

Thrombocytosis in a patient with upper gastrointestinal bleeding

Xingshun Qi^{1,§,*}, Valerio De Stefano^{2,§}, Xiaodong Shao¹, Xiaozhong Guo^{1,*}

¹ Liver Cirrhosis Study Group, Department of Gastroenterology, General Hospital of Shenyang Military Area, Shenyang, China;

² Institute of Hematology, Catholic University, Rome, Italy.

Summary Reported here is a case of upper gastrointestinal bleeding secondary to a peptic ulcer involving an extremely high platelet count of $989 \times 10^9/L$. Myeloproliferative neoplasms were ruled out on the basis of gene mutation testing and a bone marrow biopsy. After the cessation of index bleeding, the platelet count decreased markedly. Thus, reactive thrombocytosis was considered as a possibility.

Keywords: Bleeding, platelet count, thrombocytosis, myeloproliferative neoplasm, gastrointestinal

1. Introduction

Depending to its etiology, thrombocytosis is divided into two main categories, primary (*i.e.*, clonal thrombocytosis) or secondary thrombocytosis (*i.e.*, reactive thrombocytosis) (1). The most common cause of clonal thrombocytosis is essential thrombocythemia. The common causes of reactive thrombocytosis include iron deficiency, inflammatory conditions or infection, malignancy, splenectomy, and acute blood loss. Described here is a case of upper gastrointestinal bleeding in which thrombocytosis was far more apparent than that usually observed in similar cases and in which thrombocytosis subsided after the cessation of bleeding.

2. Case Report

On July 26, 2016, a 59-year-old man with recurrent upper abdominal pain for a week prior was seen at a local hospital. The man had a history of cigarette smoking. Routine blood tests revealed a white blood cell (WBC) count of $22.45 \times 10^9/L$ (normal range: $4-10 \times 10^9/L$), a percentage of neutrophils of 91.1% (normal range: 50-70%), a red blood cell (RBC) count of 2.78

$\times 10^{12}/L$ (normal range: $4-5.5 \times 10^{12}/L$), a hemoglobin (Hb) level of 64 g/L (normal range: 120-160 g/L), a hematocrit (Hct) level of 21.8% (normal range: 40-50%), a mean corpuscular volume (MCV) of 78.5 fL (normal range: 83.0-100.0 fL), a mean corpuscular hemoglobin concentration (MCHC) of 293 g/L (normal range: 320-360 g/L), a platelet (PLT) count of $989 \times 10^9/L$ (normal range: $100-300 \times 10^9/L$), and a plateletricit (PCT) level of 0.735 (normal range: 0.108-0.282). Abdominal color Doppler ultrasound did not reveal any abnormalities in the liver, spleen, or pancreas.

On July 28, 2016, the man was transferred to Hematology at another local hospital. Myeloproliferative neoplasms (MPNs) were suspected. Laboratory tests revealed that the WBC count was $19.77 \times 10^9/L$ (normal range: $3.5-9.5 \times 10^9/L$), the percentage of neutrophils was 82.3% (normal range: 40-75%), the RBC count was $2.78 \times 10^{12}/L$ (normal range: $4.3-5.8 \times 10^{12}/L$), Hb was 68 g/L (normal range: 130-175 g/L), Hct was 22.4% (normal range: 40-50%), the MCV was 80.6 fL (normal range: 82.0-100.0 fL), the MCHC was 304.0 g/L (normal range: 316-354 g/L), the PLT count was $910 \times 10^9/L$ (normal range: $125-350 \times 10^9/L$), PCT was 0.8 (normal range: 0.2-0.4), folate was 8.85 nmol/L (normal range: 10.4-42.4 nmol/L), vitamin B12 was 966.9 pmol/L (normal range: 145-637 pmol/L), and serum ferritin was 109.6 ug/L (normal range: 30-400 ug/L). The man tested negative for the BCR/ABL P210 or BCR/ABL P190 fusion gene. The man also tested negative for the JAK2 V617F mutation, the JAK2 (EXON12) N542-E543 and N542-E544 deficiency, the JAK2 (EXON12) gene K539L1/L2 mutation, the MPL (EXON10) W515K\A\L\R1\R2\S) mutation, the MPL (EXON10)

Released online in J-STAGE as advance publication December 5, 2016.

§These authors contributed equally to this works.

*Address correspondence to:

Dr. Xiaozhong Guo, and Dr. Xingshun Qi, Department of Gastroenterology, General Hospital of Shenyang Military Area, No. 83 Wenhua Road, Shenyang, 110840 China.

E-mail: guo_xiao_zhong@126.com (XG), xingshunqi@126.com (XQ)

S505N mutation, and the CALR (EXON9) L367fs*46/k385fs*47 mutation. A bone marrow biopsy revealed active proliferation of nucleated bone marrow cells. The ratio of anucleate cells to nucleated cells was 8.20/1, the proportion of granulocytes was 79.6%, the proportion of erythrocytes was 18.4%, and the ratio of granulocytes to erythrocytes was 4.33/1. There was active proliferation of granulocytes, less active erythropoiesis, and the megakaryocyte count in a bone marrow smear was 192 cells, including 27 promegakaryocytes, 41 granular megakaryocytes, 30 platelet-producing megakaryocytes, and 2 bare nuclei.

As of August 6, 2016, the man developed melena and fatigue. On August 9, 2016, he was transferred to this Department. On physical examination, the skin was pallid and the upper abdomen was tender without rebound. Laboratory tests revealed that the WBC count was $8.9 \times 10^9/L$ (normal range: $3.5-9.5 \times 10^9/L$), the percentage of neutrophils was 80.6% (normal range: 40-75%), the RBC count was $2.86 \times 10^{12}/L$ (normal range: $4.3-5.8 \times 10^{12}/L$), Hb was 67 g/L (normal range: 130-175 g/L), Hct was 21.7% (normal range: 40-50%), the PLT count was $831 \times 10^9/L$ (normal range: $125-350 \times 10^9/L$), and PCT was 0.414 (normal range: 0.108-0.272). Upper gastrointestinal endoscopy revealed multiple duodenal ulcers with active bleeding (Figure 1). The patient tested positive for a *Helicobacter pylori* infection. Thus, the patient was diagnosed with a duodenal ulcer. Three U of RBCs were intravenously infused and esomeprazole was administered. On August 12, 2016, upper gastrointestinal endoscopy was performed again and revealed no active bleeding from lesions (Figure 2). On August 17, 2016, laboratory tests revealed that the WBC count was $7.4 \times 10^9/L$ (normal range: $3.5-9.5 \times 10^9/L$), the percentage of neutrophils was 75.2% (normal range: 40-75%), the RBC count was $3.13 \times 10^{12}/L$ (normal range: $4.3-5.8 \times 10^{12}/L$), Hb was 80 g/L (normal range: 130-175 g/L), Hct was 25.3% (normal range: 40-50%), the PLT count was $448 \times 10^9/L$ (normal range: $125-350 \times 10^9/L$), and PCT was 0.301 (normal range: 0.108-0.272). After a hematologist was consulted, MPNs were ruled out. The same day, the patient was discharged due to the cost of hospitalization. Unfortunately, a telephone follow-up with the patient's son indicated that the patient died from recurrent massive upper gastrointestinal bleeding on August 28, 2016.

3. Discussion

Physicians need to differentiate the nature of thrombocytosis due to an extremely high PLT. Classic Philadelphia chromosome-negative MPNs include polycythemia vera, essential thrombocythemia, and primary myelofibrosis (2). Once a patient has a sustained PLT of more than $450 \times 10^9/L$, essential thrombocythemia should be suspected. Additionally, novel gene mutations greatly facilitate the diagnosis of

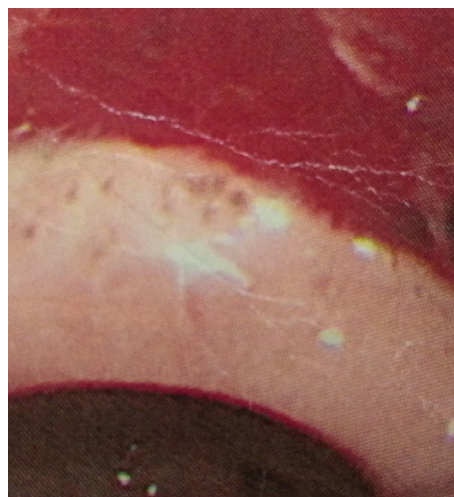


Figure 1. Upper gastrointestinal endoscopy before treatment.

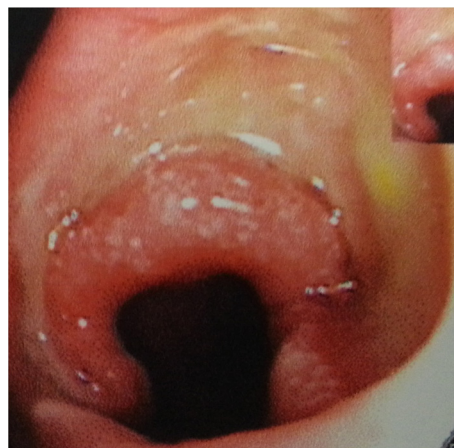

Figure 2. Upper gastrointestinal endoscopy after treatment.

essential thrombocythemia based on current evidence (2). In the current patient, clonal thrombocytosis was initially suspected. However, the current patient did not test positive for any MPN-related gene mutations. A profound increase in PLT subsided after upper gastrointestinal bleeding was appropriately diagnosed and treated. Thus, MPNs were ruled out in the current case.

According to Tefferi *et al.*, reactive thrombocytosis is defined as: *i*) no history of chronic myeloproliferative disorders; *ii*) a condition associated with secondary thrombocytosis; and *iii*) PLT returns to its normal level once an acute condition subsides (3). The current patient met these criteria for reactive thrombocytosis.

Upper gastrointestinal bleeding is one of the most frequent and lethal gastrointestinal conditions (4,5). In patients with acute upper gastrointestinal bleeding, hematemesis and melena are key clinical symptoms, anemia is a key physical sign, and a lower Hb level is evident in laboratory results. Upper gastrointestinal endoscopy is the method of choice for identifying the source of upper gastrointestinal bleeding. A peptic ulcer is one of the most common sources of upper

gastrointestinal bleeding. In the current patient, thrombocytosis was primarily secondary to upper gastrointestinal bleeding according to endoscopic findings.

The precise mechanism for upper gastrointestinal bleeding and reactive thrombocytosis remains unclear. In essential thrombocythemia, a PLT level of $> 800-1,000 \times 10^9/L$ has been reported to be associated with a higher incidence of severe bleeding independent of the use of aspirin (6). Some bleeding events in MPNs may be caused by the reported depletion of high-molecular weight von Willebrand factor multimers, *i.e.* acquired von Willebrand disease. This condition has been noted in 20% of patients with essential thrombocythemia and is associated with a higher risk of bleeding (7). In the current patient, however, thrombocytosis was primarily secondary to upper gastrointestinal bleeding, which was verified by endoscopy, and thrombocytosis subsided after the cessation of bleeding.

In conclusion, patients with upper gastrointestinal bleeding and an increased level of PLT should be carefully screened for reactive thrombocytosis.

References

1. Harrison CN, Bareford D, Butt N, *et al.* Guideline for investigation and management of adults and children presenting with a thrombocytosis. *Br J Haematol.* 2010; 149:352-375.
2. Arber DA, Orazi A, Hasserjian R, Thiele J, Borowitz MJ, Le Beau MM, Bloomfield CD, Cazzola M, Vardiman JW. The 2016 revision to the World Health Organization classification of myeloid neoplasms and acute leukemia. *Blood.* 2016; 127:2391-2405.
3. Tefferi A, Ho TC, Ahmann GJ, Katzmann JA, Greipp PR. Plasma interleukin-6 and C-reactive protein levels in reactive versus clonal thrombocytosis. *Am J Med.* 1994; 97:374-378.
4. Hearnshaw SA, Logan RF, Lowe D, Travis SP, Murphy MF, Palmer KR. Use of endoscopy for management of acute upper gastrointestinal bleeding in the UK: Results of a nationwide audit. *Gut.* 2010; 59:1022-1029.
5. Hearnshaw SA, Logan RF, Lowe D, Travis SP, Murphy MF, Palmer KR. Acute upper gastrointestinal bleeding in the UK: Patient characteristics, diagnoses and outcomes in the 2007 UK audit. *Gut.* 2011; 60:1327-1335.
6. Patrono C, Rocca B, De Stefano V. Platelet activation and inhibition in polycythemia vera and essential thrombocythemia. *Blood.* 2013; 121:1701-1711.
7. Mital A, Prejzner W, Bieniaszewska M, Hellmann A. Prevalence of acquired von Willebrand syndrome during essential thrombocythemia: A retrospective analysis of 170 consecutive patients. *Pol Arch Med Wewn.* 2015; 125:914-920.

(Received October 3, 2016; Revised November 4, 2016; Accepted November 7, 2016)