

Carotid strain measurement in patients with pseudoxanthoma elasticum – Hint for a different pathomechanism?

Sebastian Gorgonius Passon^{1,§,*}, Viviane Küllmar^{1,§}, Anna Katharina Blatzheim¹, Kristin Solveig Pausewang¹, Max Jonathan Stumpf¹, Doris Hendig², Martin Gliem³, Simon Pingel¹, Robert Schueler¹, Dirk Skowasch¹, Najib Schahab¹, Georg Nickenig¹, Christian Alexander Schaefer¹

¹Department of Internal Medicine II- Cardiology, Pulmonology and Angiology, University Hospital Bonn, Bonn, Germany;

²Institute for Laboratory and Transfusion Medicine, Heart and Diabetes Center North Rhine-Westphalia, University Hospital of the Ruhr University of Bochum, Bad Oeynhausen, Germany;

³Department of Ophthalmology, University of Bonn, Bonn, Germany.

Summary

Pseudoxanthoma Elasticum (PXE), caused by autosomal-recessive mutations in the ATP-binding cassette transporter (ABCC6) gene, is known for high prevalence of atherosclerosis. A novel method investigating elastic properties of arteries in atherosclerotic patients is vascular strain analysis. We compared 44 PXE patients with peripheral artery disease (PXE+PAD group) with 50 control patients, each 25 without (control group) and with PAD (PAD group). All participants underwent an angiological examination including ankle-brachial index (ABI) and were examined with speckle-tracking based vascular strain analysis of common carotid arteries, measuring radial displacement (r.Dis), radial velocity (r.Vel), radial strain (r.Str), circumferential strain (c.Str), radial strainrate (r.SR) and circumferential strainrate (c.SR). We found significant lower ABI in patients with PXE compared to all other groups (each $p < 0.01$). The vascular strain analysis resulted in significantly decreased values in the PAD group compared to PXE with PAD (each $p \leq 0.01$) and controls without PAD (each $p \leq 0.05$), whereas no significant difference could be found between PXE+PAD and controls without PAD. We found significant negative correlations between low strain values and a higher prevalence of PAD in non-PXE patients (r.Str $r = -0.34$; c.Str $r = -0.35$; r.SR: $r = -0.51$; c.SR: $r = -0.53$). In conclusion, PXE patients had similar values for arterial stiffness compared to controls without PAD in vascular strain analysis. In this group, arterial stiffness parameters were significantly higher compared to non-PXE PAD patients. It is worth to discuss whether PAD-like manifestations in PXE are a different kind of disease and might need another strategy in diagnostics and therapy.

Keywords: Pseudoxanthoma Elasticum (PXE), carotid strain, vascular stiffness, ATP-binding cassette transporter (ABCC6), peripheral artery disease (PAD)

1. Introduction

Pseudoxanthoma Elasticum (PXE) is a rare, autosomal

recessive disorder with a prevalence of 1:25,000 to 1:100,000 caused by loss of function mutations in the ATP-binding cassette transporter (ABCC6) gene (1–4). It is also known as Grönblad-Strandberg syndrome and represents a systemic mineralization disorder due to a defect in the ABCC6 on the basolateral cell surface, which influences the peripheral concentration of pyrophosphate (PPi) in healthy persons (5,6). As PPi is a strong inhibitor of calcification processes and PXE patients had lower levels of PPi, this is a potential reason for the observed manifestations including

Released online in J-STAGE as advance publication February 26, 2018.

[§]These authors contributed equally to this work.

*Address correspondence to:

Sebastian Passon, Department of Internal Medicine II - Cardiology, Pulmonology and Angiology, University of Bonn, Sigmund-Freud Str. 25, 53127 Bonn, Germany.
E-mail: s.passon@uni-bonn.de

calcification and fragmentation of elastic fibres and soft connective tissues (6–9). Histologic studies revealed a thickening and calcification of Bruch's membrane, mineralisation and fragmentation in the mid-dermal layer elastic fibres and several vascular changes in different organs (*i.e.* heart, muscles, lung, kidney *etc.*) (2,4,10,11). Neither the signal pathways from loss of function mutation of ABCC6 to structural changes in soft tissues are known, nor is the underlying pathomechanism of functional alterations in the vessel wall or other organ systems completely understood (7,12).

Characteristic clinical symptoms of PXE include typical skin signs including yellowish papules and inelastic skinfolds especially on the lateral neck, the axillae and the popliteal fossae (1,2). Other characteristic signs are ophthalmologic alterations like angoid streaks or retinal pigment epithelium atrophy and cardiovascular manifestations such as a high prevalence of peripheral artery disease (PAD), intermittent claudication or chronic vascular occlusions which are mostly localized in the lower limb specially the femoral arteries (13–15). Atherosclerosis and PAD are associated with changes in vascular elasticity as observed in non-PXE patients (16). These changes may lead to hypertension and a decreased vascular compliance, which is documented as an independent risk factor for cardiovascular events (17–19). There are only few existing studies with PXE patients in which arterial stiffness is investigated with conventional methods like carotid-femoral pulse wave velocity or distensibility coefficient analysis (20,21). Results vary a lot between different authors and cohorts. The findings are contradictory as they spread between a more elastic artery, no changes or stiffer arteries at different sites of the arterial tree (1,9).

Speckle-tracking based vascular strain analysis is a novel method to examine arterial elasticity used since 2010 and has been demonstrated as a feasible and reliable method (22,23). The technique is easy to apply, provides information on the mechanical properties of arteries and is proven to be as a superior method for detecting patients with cardiovascular risks and subclinical atherosclerosis (24–26).

Purpose of our study was to examine the elastic properties of carotid arteries in PXE patients with the technique of vascular strain imaging to generate more information about mechanical changes caused by the mineralisation disorder.

2. Materials and Methods

2.1. Patients

For this retrospective register data analysis, we enrolled 94 subjects. 44 patients had a clinical or a combined clinical and genetical evidence of PXE. The clinical

evidence consists of characteristic skin lesions and typical eye and retina changes, whereas the combined evidence implies a genetical evidence of a biallelic loss of function mutation in the ABCC6 gene, assessed in the Institute for Laboratory and Transfusion Medicine at the Heart and Diabetes Centre Bad Oeyenhausen and at least one clinical sign as described above (14).

PAD was defined by ultrasonographic findings (*i.e.* calcified or inhomogeneous vessel wall deformations and plaques) or an ankle-brachial index (ABI) lower than 0.9 or higher than 1.3.

All 44 PXE patients had a proven PAD, including 11 patients with a chronic vascular occlusion (CVO), and were classified as "PXE+PAD". Patients with PXE without a proven PAD were excluded due to a very small number of patients. 25 non PXE patients were confirmed to have PAD and were rated as "PAD". The last group named "control" comprised 25 patients without neither signs of PAD nor of PXE. For baseline characteristics see Table 1.

2.2. Angiological examination

Angiological examinations took place in the Department for Internal Medicine II at the University Hospital Bonn. Common cardiovascular risk factors such as age, sex, smoking, diabetes, hypertonia, fat metabolism disorder and an existing coronary artery disease were recorded from our register data.

The investigated functional parameters were the ankle-brachial index (ABI) (Vasoquant VQ 4000: ELCAT, Wolfraatshausen, Germany), the pulse-wave index (PWI) and the central pulse wave velocity (cPWV) (PWI and cPWV: Angio Experience Pro 8: Sonoteknik Karl Glantschnig GmbH, Kärnten, Austria). The PWI is a novel marker which might allow an early detection of subclinical atherosclerosis and is calculated as follows (27):

$$PWI = \frac{\text{higher amplitude of upper limb pulse wave}}{\text{amplitude of corresponding lower limb pulse wave}} \times \text{peak time}$$

Values greater than 180 were considered as pathological (28).

All patients underwent ultrasonographic examination performed by experienced physicians. (iE 33 xMatrix Echocardiography System equipped with a L11-3 Line Array Scanner, Philips Healthcare, PC Best, Netherlands) Bilateral images and maximum velocities of the common carotid artery (CCA), internal and external carotid artery, and vertebral artery were acquired. Lower limb arteries were also examined. Additionally, during ultrasound examination an ECG-triggered sequence of both CCA from all enrolled patients was captured over five cardiac cycles during a short breath hold for the following vascular strain analysis.

Table 1. Baseline characteristics

Items	PXE+PAD (n = 44)	Control (n = 25)	PAD (n = 25)	ANOVA p-value	PXE+PAD vs. Control	PXE+PAD vs. PAD	PAD vs. Control
Age (years)	54.25 ± 8.93	49.32 ± 9.76	53.60 ± 6.07	0.064			
BMI	28.19 ± 6.16	24.10 ± 3.52	23.28 ± 4.46	0.014	0.03	0.24	0.96
Sex (male) [%]	19 [43.2]	11 [44.0]	12 [48.0]	0.925			
Smoking [%]	20 [45.5]	6 [24.0]	12 [48.0]	0.381			
Diabetes [%]	1 [2.3]	0 [0.0]	2 [8.0]	0.252			
Hypertension [%]	19 [43.2]	8 [32.0]	14 [56.0]	0.231			
Dyslipidämia [%]	18 [40.9]	4 [16.0]	9 [36.0]	0.121			
Coronary heart disease [%]	5 [11.4]	0 [0.0]	5 [20.0]	0.101			

PXE = patients with pseudoxanthoma elasticum; PAD = peripheral artery disease; BMI = body mass index.

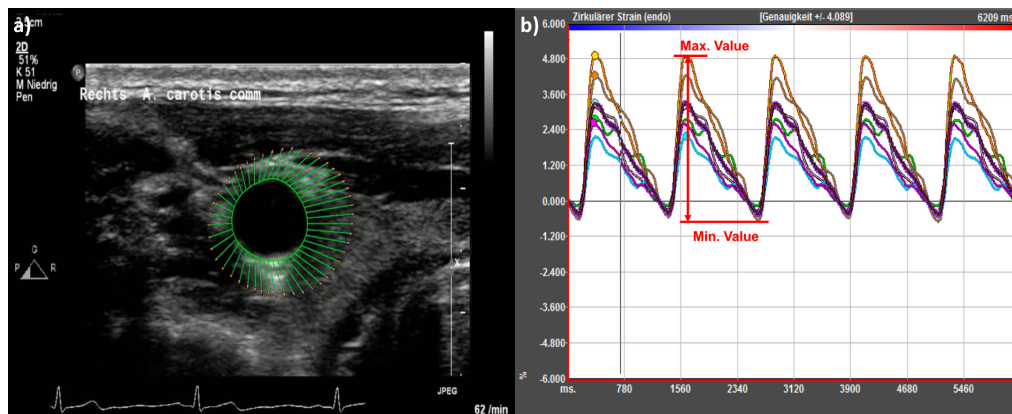


Figure 1. Carotid strain analysis. a) Region of interest (ROI) marked by green line with vectors of vessel movement. b) Graphic display of 6 parts of circumferential strain by software.

2.3. Vascular strain analysis

As we described previously, vascular strain analysis was performed at an offline work station equipped with Image Arena™ Version 4.6 Build 4.6.2.12 (TomTec Imaging Systems, Unterschleissheim, Germany) (29). After choosing the sequence with the least motion artefacts, a "region of interest" (ROI) was placed by marking indicator points in the intima-media complex so that the software was able to calculate the circumferential contour of the vessel (30,31) (Figure 1a). Adequate speckle-tracking based analysis was verified by the operator and adjusted if necessary (22). The vessel wall was divided automatically into six parts and local parameters were assessed. For further analysis, the six values were averaged (Figure 1b). For characterisation of the arterial motion and deformation six parameters were recorded: radial displacement (r.Dis) (mm) describes the motion of the entire vessel wall, whereas the radial strain (r.Str) (%) represents the radial expansion during the cardiac cycle. Circumferential strain (c.Str) (%) describes the circumferential stretching and constriction of the artery. For these parameters the maximum and minimum values were recorded by the software and the amplitudes were calculated (26,31). Radial velocity (r.Vel) (cm/s), radial strain rate (r.SR) (1/s) and circumferential strain rate (c.SR) (1/s) correspond as temporal derivation to the dynamic motion of the

Table 2. Reliability analysis with interclass correlation coefficient (ICC)

Items	Interrater ICC (95% CI)	Intrater ICC (95% CI)
r.Str (%)	0.895 (0.755-0.952)	0.891 (0.745-0.955)
c.Str (%)	0.958 (0.897-0.983)	0.940 (0.855-0.976)
r.SR (%)	0.883 (0.729-0.952)	0.823 (0.606-0.926)
c.SR (%)	0.980 (0.950-0.992)	0.964 (0.912-0.986)

r.Str = radial strain; c.Str = circumferential strain; r.SR = radial strain rate; c.SR = circumferential strain rate.

vessel wall. For these parameters, the maximum value was recorded.

To consider stabilizing effects of current statin therapy on radial strain in PAD patients we compared existing statin therapy between PXE+PAD group and PAD group but found no significant difference (40/43 (93%) vs. 23/25 (92%); $p = 0.876$) (29).

A reliability analysis for vascular strain measurement was performed by calculating the interclass correlation coefficient (ICC) for 20 random patients by two experienced observers. The results are displayed in Table 2 and for all investigated strain values (r.Str, c.Str, r.SR and c.SR) we found good agreement for inter- and intra-reader reliability.

2.4. Statistical analysis

Statistical Analysis was performed with SPSS 23®

Table 3. Angiological examination with arterial stiffness analysis

Items	PXE+PAD (n = 44)	Control (n = 25)	PAD (n = 25)	ANOVA p-value	PXE+PAD vs. Control	PXE+PAD vs. PAD	PAD vs. Control
ABI	0.83 ± 0.19	1.09 ± 0.07	1.04 ± 0.12	0.001	0.001	0.001	0.373
PWI	259.20 ± 124.05	115.47 ± 33.83	181.80 ± 180.77	0.002	0.001	0.349	0.397
cPWV (m/s)	5.10 ± 1.04	5.65 ± 1.14	6.27 ± 2.07	0.058			
r.Vel (cm/s)	0.07 ± 0.08	0.11 ± 0.04	0.07 ± 0.04	0.048	0.06	0.982	0.003
r.Dis (mm)	0.15 ± 0.05	0.15 ± 0.05	0.11 ± 0.06	0.008	0.997	0.014	0.041
r.Str (%)	5.30 ± 1.72	4.73 ± 1.56	3.62 ± 1.68	0.001	0.396	0.001	0.069
c.Str (%)	4.05 ± 1.44	4.09 ± 1.47	2.90 ± 1.73	0.007	0.991	0.014	0.026
r.SR (1/s)	0.39 ± 0.11	0.36 ± 0.10	0.25 ± 0.10	0.001	0.685	0.001	0.001
c.SR (1/s)	0.28 ± 0.10	0.30 ± 0.11	0.18 ± 0.10	0.001	0.799	0.001	0.001

ABI = ankle brachial index; PWI = pulse wave index; cPWV = central pulse wave velocity; r.Vel = radial velocity; r.Dis = radial displacement; r.Str = radial strain; c.Str = circumferential strain; r.SR = radial strain rate; c.SR = circumferential strain rate.

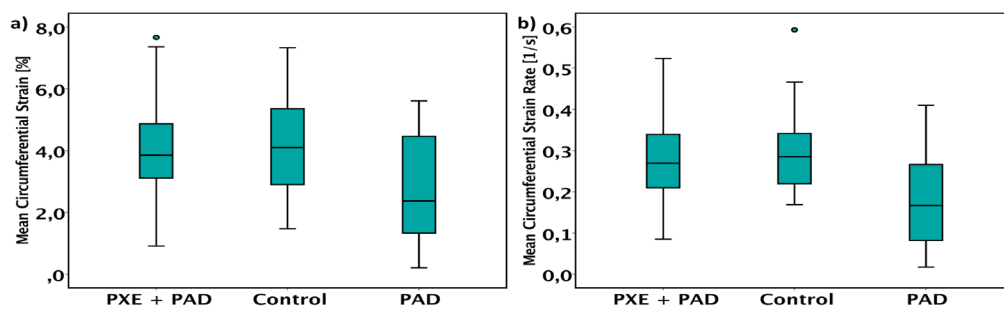


Figure 2. Analysis of circumferential strain and circumferential strain rate. a) Comparison of circumferential strain [%] between all groups. (PXE+PAD: 4.05 ± 1.44 vs. Control: 4.09 ± 1.47 vs. PAD: 2.90 ± 1.73; $p = 0.007$). **b)** Comparison of circumferential strain rate [1/s] between all groups. (PXE+PAD: 0.28 ± 0.10 vs. Control: 0.30 ± 0.11 vs. PAD: 0.18 ± 0.10; $p = 0.004$).

(SPSS Inc. Chicago, IL, USA) and all values were presented as mean ± standard deviation. A significant p -value was assumed as a two-sided $p < 0.05$. To investigate distributions of non-parametric variables Chi² test was applied, whereas parametric variables were explored with ANOVA test in case of comparison of more than two groups. As post-hoc analysis we made use of Tahame-T2 test for inhomogeneous variances and a Scheffé procedure for homogenous variances. In case of comparison of two groups a Gaussian distribution was verified. For this purpose, a t -test was used, while in non-Gaussian distributions a Mann-Whitney- U -test was applied. Correlation analysis was performed with Pearson's test for parametric variables and Spearman-Rho test for non-parametric variables.

3. Results

Patients' baseline characteristics are displayed in Table 1. We found no differences in age and cardiovascular risk profiles.

3.1. Angiological parameters

Analysing functional angiological parameters we found significant differences in ABI ($p < 0.01$) and post-hoc analysis revealed lower ABI in the PXE+PAD group compared to all other groups (each $p < 0.01$). Likewise,

the ANOVA test for PWI resulted in a significant overall difference ($p < 0.01$) and in pairwise analysis the PXE+PAD group had significant higher values compared to control group (259.20 ± 124.05 vs. 115.47 ± 33.83; $p < 0.01$). (Table 3)

3.2. Vascular stiffness analysis

Exploration of vascular stiffness parameters presented a trend for cPWV to be higher in the PAD group ($p = 0.06$). Results of vascular strain analysis are also displayed in Table 3. For all six parameters the ANOVA test produced significant p -values for overall differences (r.Dis: $p < 0.01$; r.Str: $p < 0.01$; c.Str: $p < 0.01$; r.Vel: $p = 0.048$; r.SR: $p < 0.01$; c.SR: $p < 0.01$). For each mentioned strain value, except radial velocity and radial strain in comparison of PAD to control, we found significant lower values in the PAD group compared with PXE+PAD (r.Dis: $p = 0.01$; r.Str: $p < 0.01$; c.Str: $p = 0.01$; r.SR: $p < 0.01$; c.SR: $p < 0.01$) and controls (r.Dis: $p = 0.04$; r.Str: $p = 0.07$; c.Str: $p = 0.03$; r.SR: $p < 0.01$; c.SR: $p < 0.01$) in post-hoc analysis, whereas no significant difference could be found between PXE+PAD and controls without PAD (r.Dis: $p = 0.99$; r.Str: $p = 0.40$; c.Str: $p = 0.99$; r.SR: $p = 0.69$; c.SR: $p = 0.80$) (Figure 2).

Across all groups we found weak but significant negative correlations for cPWV and r.SR ($r = -0.362$; $p <$

Table 4. Subgroup analysis

Items	PXE+PAD (n = 33)	PXE+CVO (n = 11)	p-value
Age	53.84 ± 9.39	55.73 ± 8.14	0.577
ABI	0.90 ± 0.15	0.66 ± 0.20	0.000
PWI	237.70 ± 119.14	353.80 ± 108.54	0.047
cPWV (m/s)	5.27 ± 1.15	4.67 ± 0.58	0.243
r.Vel (cm/s)	0.06 ± 0.09	0.09 ± 0.07	0.226
r.Dis (mm)	0.14 ± 0.05	.15 ± 0.06	0.563
r.Str (%)	5.24 ± 1.54	5.51 ± 2.28	0.668
c.Str (%)	4.01 ± 1.35	4.20 ± 1.77	0.712
r.SR (1/s)	0.38 ± 0.10	0.41 ± 0.14	0.474
c.SR (1/s)	0.27 ± 0.09	0.30 ± 0.12	0.325

ABI = ankle brachial index; PWI = pulse wave index; cPWV = central pulse wave velocity; r.Vel = radial velocity; r.Dis = radial displacement; r.Str = radial strain; c.Str = circumferential strain; r.SR = radial strain rate; c.SR = circumferential strain rate.

0.01) and cPWV and c.SR ($r = -0.329$; $p = 0.02$). Within the non-PXE group (controls; PAD) we observed highly significant correlations for the existence of PAD and r.Str ($r = -0.34$; $p = 0.02$), PAD and c.Str ($r = -0.345$; $p = 0.01$), PAD and r.SR ($r = -0.51$; $p < 0.01$) and PAD and c.SR ($r = -0.53$; $p < 0.01$).

3.3. Subgroup analysis

For a subgroup analysis, the PXE+PAD group is divided into a group with PAD and another group with chronic vascular occlusions (CVO). ABI was lower in the PXE+CVO group compared to the PXE+PAD subgroup (0.66 ± 0.20 vs. 0.90 ± 0.15 ; $p < 0.01$) and PWI was higher in the PXE+CVO group (353.80 ± 168.54 vs. 237.70 ± 119.14 ; $p = 0.047$). Parameters for vascular stiffness did not differ between these groups (Table 4).

4. Discussion

The present study demonstrated similar carotid strain values of PXE patients with PAD and control patients without PAD. Contrary to our expectation PXE patients with PAD presented higher carotid strain values compared to "normal" PAD patients, even if they suffered from severe PAD with a high amount of chronic vascular occlusions, as we already have demonstrated (15). Additionally, subgroup analysis revealed no differences between PXE patients with PAD and PXE patients with CVO, even their strain values are consistent with the results of healthy controls.

In 2003 Germain *et al.* described a more elastic radial artery, as well as less carotid wall stress in PXE patients assessed with conventional methods of vascular stiffness measurement (21). As demonstrated by Kornet *et al.*, PXE patients show a stable compliance coefficient of carotid arteries with increasing age in comparison to controls with decreasing coefficients over time. (9). Leftheriotis *et al.* published in 2011 that patients with lower ABI were older and had a higher carotid femoral PWV, but they were not able to prove

that PWV could serve as predictor of ABI (20). To our knowledge, the latest study regarding the vascular stiffness of PXE patients, was performed by Campens *et al.* in 2013 and showed that PXE had a higher PWV compared to controls. They concluded, that PXE patients' aorta was stiffer (1).

Studies with non PXE-patients described an association of arterial stiffness with PAD in connected with higher values for PWV (16). In addition, Podgórski *et al.* already performed vascular strain analysis to examine arterial calcification (26). Bjällmark *et al.* and Park *et al.* also revealed the association between the novel parameters and subclinical atherosclerosis in which they saw vascular strain imaging as a superior method (22,32).

Another disease with a high prevalence of PAD is obstructive sleep apnoea. It is associated with low vascular stiffness values assessed by speckle tracking strain analysis (33,34). Following these studies, we expected low strain values in PXE patients as well. In contrast to our expectation PXE patients had inconspicuous values similar to controls without PAD.

The first histomorphological study of three PXE patients was performed in 1978 where Mendelson *et al.* described fragmented and elastic laminae in the muscle arteries followed by vascular calcification (35). In the last decade studies from Nolte *et al.* and Miki *et al.* also discussed degenerated, fragmented and calcified elastic fibres (10,36). An autopsy study of two PXE patients was published in 2003 by Gheduzzi *et al.* In their studied cases they found similar damages in arteries and veins including fragmentation and mineralization of elastic fibres. Additionally they observed changes in collagen fibrils (37). To our knowledge, the latest histomorphological study of the vascular system was accomplished in 2004 by Kornet *et al.* Besides the well-known fragmented elastic fibres and calcifications processes, which were found especially in the media of the arterial wall, they found increased quantity of proteoglycans in the media which may lead to a diminished arterial stiffness (9).

PAD in non PXE patients is predominantly characterized as a process affecting the intima of the vessel wall with endothelial dysfunction, lipid deposition, local inflammation, affection the smooth muscles and remodelling of the extracellular matrix resulting in an atherosclerotic plaque (38). Whereas histomorphological changes regarding PAD in PXE patients are mainly described in the media of the vessel wall and the surrounding elastic laminae (9,35).

Having in mind the described histomorphological changes, a possible explanation for the clinical results of vascular strain analysis could be a combined pathomechanism. On the one hand, the calcification and mineralization of the arterial wall as observed in non-PXE PAD patients, increase the arterial stiffness. On the other hand, the combined effect of damaged arterial wall

architecture – caused by fragmentation and degeneration of elastic fibres – and changed vessel wall composition with more proteoglycans leads to decreased arterial stiffness. As final result of the antagonizing processes, it is understandable that vascular stiffness measured by vascular strain analysis did not change within PXE patients with progressive PAD. In contrast, it seems to be stable and similar to people without PAD. It is worth to be discussed if PAD-like manifestations in PXE, with its separate pathomechanism, are a fundamentally different disease than PAD caused by "normal" atherosclerosis. Following this consideration, we should think about other diagnostic strategies for detection of CVO.

Limitations of the present study imply a lack of information due to the design as register study, such as baseline characteristics and measurement results, but for all patients age, ABI and vascular strain data was completely recorded. Another limitation is the small number of patients. In further studies, we would like to confirm our results with more patients and controls to validate the unexpected inconspicuous strain values of PXE patients with PAD and investigate the change of vascular strain in patients with PXE over time.

5. Conclusion

Assessed by vascular strain analysis of common carotid arteries PXE patients had unremarkable values for arterial stiffness compared to controls without PAD. Their arterial stiffness parameters were significantly better than in non-PXE PAD patients, even if they had a more servant PAD. In addition, we found a negative correlation in non-PXE patients between low strain values and a higher prevalence of PAD. We have to consider a combined pathway of vascular alteration as well as PXE as a fundamentally different disease which needs other therapy strategies in those patients.

Acknowledgement

We would like to thank Sonotechnik Austria for providing the Angio Experience Pro 8.

References

- Campens L, Vanakker OM, Trachet B, Segers P, Leroy BP, De Zaeijtj J, Voet D, De Paepe A, De Backer T, De Backer J. Characterization of cardiovascular involvement in pseudoxanthoma elasticum families. *Arterioscler Thromb Vasc Biol.* 2013; 33:2646-2652.
- Marconi B, Bobyr I, Campanati A, Molinelli E, Consales V, Brisigotti V, Scarpelli M, Racchini S, Offidani A. Pseudoxanthoma elasticum and skin: Clinical manifestations, histopathology, pathomechanism, perspectives of treatment. *Intractable rare Dis Res.* 2015; 4:113-122.
- Koblos G, Andrikovics H, Prohaszka Z, Tordai A, Varadi A, Aranyi T. The R1141X loss-of-function mutation of the ABCC6 gene is a strong genetic risk factor for coronary artery disease. *Genet Test Mol Biomarkers.* 2010; 14:75-78.
- Gliem M, Fimmers R, Müller PL, Brinkmann CK, Finger RP, Hendig D, Holz FG, Charbel Issa P. Choroidal Changes Associated With Bruch Membrane Pathology in Pseudoxanthoma Elasticum. *Am J Ophthalmol.* 2014; 158:198-207.e3.
- Li Q, Jiang Q, Uitto J. Ectopic mineralization disorders of the extracellular matrix of connective tissue: Molecular genetics and pathomechanisms of aberrant calcification. *Matrix Biol.* 2014; 33:23-28.
- Jansen RS, Duijst S, Mahakena S, Sommer D, Szeri F, Váradi A, Plomp A, Bergen AA, Oude Elferink RP, Borst P, van de Wetering K. ABCC6-mediated ATP secretion by the liver is the main source of the mineralization inhibitor inorganic pyrophosphate in the systemic circulation – Brief report. *Arterioscler Thromb Vasc Biol.* 2014; 34:1985-1989.
- Lefthériotis G, Omarjee L, Le Saux O, Henrion D, Abraham P, Prunier F, Willoteaux S, Martin L. The vascular phenotype in Pseudoxanthoma elasticum and related disorders: contribution of a genetic disease to the understanding of vascular calcification. *Front Genet.* 2013; 4:4.
- Jansen RS, Küçükosmanoglu A, de Haas M, Saphth S, Otero JA, Hegman IE, Bergen AA, Gorgels TG, Borst P, van de Wetering K. ABCC6 prevents ectopic mineralization seen in pseudoxanthoma elasticum by inducing cellular nucleotide release. *Proc Natl Acad Sci U S A.* 2013; 110:20206-20211.
- Kornet L, Bergen AAB, Hoeks APG, Cleutjens JP, Oostra RJ, Daemen MJ, van Soest S, Reneman RS. In patients with pseudoxanthoma elasticum a thicker and more elastic carotid artery is associated with elastin fragmentation and proteoglycans accumulation. *Ultrasound Med Biol.* 2004; 30:1041-1048.
- Miki K, Yuri T, Takeda N, Takehana K, Iwasaka T, Tsubura A. An autopsy case of pseudoxanthoma elasticum: Histochemical characteristics. *Med Mol Morphol.* 2007; 40:172-177. 5
- Pingel S, Passon SG, Pausewang KS, Blatzheim AK, Pizarro C, Tuleta I, Gliem M, Charbel Issa P, Schahab N, Nickenig G, Skowasch D, Schaefer CA. Pseudoxanthoma elasticum – Also a lung disease? the respiratory affection of patients with pseudoxanthoma elasticum. *PLoS One.* 2016;11: e0162337.
- Hosen MJ, Coucke PJ, Le Saux O, De Paepe A, Vanakker OM. Perturbation of specific pro-mineralizing signalling pathways in human and murine pseudoxanthoma elasticum. *Orphanet J Rare Dis.* 2014; 9: 66.
- Finger RP, Issa PC, Ladewig M, Götting C, Holz FG, Scholl HP. Fundus autofluorescence in Pseudoxanthoma elasticum. *Retin (Philadelphia, Pa).* 2009; 29:1496-1505.
- Uitto J, Jiang Q, Váradi A, Bercovitch LG, Terry SF. Pseudoxanthoma elasticum: Diagnostic features, classification, and treatment options. *Expert Opin orphan drugs.* 2014; 2:567-577.
- Pingel S, Pausewang KS, Passon SG, Blatzheim AK, Gliem M, Charbel Issa P, Hendig D, Horlbeck F, Tuleta I, Nickenig G, Schahab N, Skowasch D, Schaefer CA. Increased vascular occlusion in patients with pseudoxanthoma elasticum. *Vasa.* 2017; 46:47-52.
- van Popele NM, Grobbee DE, Bots ML, Asmar R, Topouchian J, Reneman RS, Hoeks AP, van der Kuip DA,

- Hofman A, Witteman JC. Association between arterial stiffness and atherosclerosis: the Rotterdam Study. *Stroke*. 2001; 32:454-460.
17. Liao D, Arnett DK, Tyroler HA, Riley WA, Chambless LE, Szklo M, Heiss G. Arterial stiffness and the development of hypertension: The ARIC study. *Hypertension*. 1999; 34:201-206.
 18. Yang EY, Dokainish H, Virani SS, Misra A, Pritchett AM, Lakkis N, Brunner G, Bobek J, McCulloch ML, Hartley CJ, Ballantyne CM, Nagueh SF, Nambi V. Segmental Analysis of Carotid Arterial Strain Using Speckle-Tracking. *J Am Soc Echocardiogr*. 2011; 24:1276-1284. e5.
 19. Laurent S. Arterial stiffness: Intermediate or surrogate endpoint for cardiovascular events? *Eur Heart J*. 2005; 26:1152-1154.
 20. Lefthériotis G, Abraham P, Le Corre Y, Le Saux O, Henrion D, Ducluzeau PH, Prunier F, Martin L. Relationship between ankle brachial index and arterial remodeling in pseudoxanthoma elasticum. *J Vasc Surg*. 2011; 54:1390-1394.
 21. Germain DP, Boutouyrie P, Laloux B, Laurent S. Arterial remodeling and stiffness in patients with pseudoxanthoma elasticum. *Arterioscler Thromb Vasc Biol*. 2003; 23:836-841.
 22. Bjällmark A, Lind B, Peolsson M, Shahgaldi K, Brodin LK, Nowak J. Ultrasonographic strain imaging is superior to conventional non-invasive measures of vascular stiffness in the detection of age-dependent differences in the mechanical properties of the common carotid artery. *Eur J Echocardiogr*. 2010; 11:630-636.
 23. Yang WI, Ha JW. Non-invasive assessment of vascular alteration using ultrasound. *Clin Hypertens*. 2015; 21:25.
 24. Catalano M, Lamberti-Castronuovo A, Catalano A, Filocamo D, Zimbalatti C. Two-dimensional speckle-tracking strain imaging in the assessment of mechanical properties of carotid arteries: Feasibility and comparison with conventional markers of subclinical atherosclerosis. *Eur J Echocardiogr*. 2011; 12:528-535.
 25. Zou C, Jiao Y, Li X, Zheng C, Chen M, Hu C. Role of ultrasonography in the evaluation of correlation between strain and elasticity of common carotid artery in patients with diabetic nephropathy. *Int J Clin Exp Med*. 2015; 8:17765-17772.
 26. Podgórski M, Grzelak P, Szymczyk K, Szymczyk E, Drozd J, Stefańczyk L. Peripheral vascular stiffness, assessed with two-dimensional speckle tracking versus the degree of coronary artery calcification, evaluated by tomographic coronary artery calcification index. *Arch Med Sci*. 2015; 11:122-129.
 27. Tuleta I, Pingel S, Biener L, Pizarro C, Hammerstingl C, Öztürk C, Schahab N, Grohé C, Nickenig G, Schaefer C, Skowasch D. Atherosclerotic Vessel Changes in Sarcoidosis. *Adv Exp Med Biol*. 2015; 910:23-30.
 28. Pizarro C, Schaefer C, Kimeu I, Pingel S, Horlbeck F, Tuleta I, Nickenig G, Skowasch D. Underdiagnosis of obstructive sleep apnoea in peripheral arterial disease. *Respiration*. 2015; 89:214-220.
 29. Schaefer CA, Blatzheim AK, Passon SG, Pausewang KS, Schahab N, Nickenig G, Skowasch D, Schueler R, Hammerstingl C, Pingel S. Modulation of carotid strain by statin therapy in atherosclerosis patients. *Vasa*. 2017; 79:1-8.
 30. Yang JW, Cho KI, Kim JH, Kim SY, Kim CS, You GI, Lee JY, Choi SY, Lee SW, Kim HS, Heo JH, Cha TJ, Lee JW. Wall shear stress in hypertensive patients is associated with carotid vascular deformation assessed by speckle tracking strain imaging. *Clin Hypertens*. 2014; 20:10.
 31. Charwat-Resl S, Niessner A, Mueller M, Bartko PE, Giurgea GA, Zehetmayer S, Willfort-Ehringer A, Koppensteiner R, Schlager O. Speckle-tracking-based evaluation of vascular strain at different sites of the arterial tree in healthy adults. *Ultraschall Med*. 2016; 37:503-508.
 32. Park HE, Cho GY, Kim HK, Kim YJ, Sohn DW. Validation of circumferential carotid artery strain as a screening tool for subclinical atherosclerosis. *J Atheroscler Thromb*. 2012; 19:349-356.
 33. Schaefer CA, Adam L, Weisser-Thomas J, Pingel S, Vogel G, Klarmann-Schulz U, Nickenig G, Pizarro C, Skowasch D. High prevalence of peripheral arterial disease in patients with obstructive sleep apnoea. *Clin Res Cardiol*. 2015; 104:719-726.
 34. Tuleta I, Skowasch D, Krycki J, Pizarro C, Hammerstingl C, Weber M, Schahab N, Nickenig G, Schaefer C, Pingel S. Obstructive Sleep Apnea Is Related to Increased Arterial Stiffness in Ultrasound Speckle-Tracking Analysis. *Adv Exp Med Biol*. 2016; 910:9-14.
 35. Mendelsohn G, Bulkley BH, Hutchins GM. Cardiovascular manifestations of Pseudoxanthoma elasticum. *Arch Pathol Lab Med*. 1978; 102:298-302.
 36. Nolte KB. Sudden cardiac death owing to pseudoxanthoma elasticum: A case report. *Hum Pathol*. 2000; 31:1002-1004.
 37. Gheduzzi D, Sammarco R, Quaglino D, Bercovitch L, Terry S, Taylor W, Ronchetti IP. Extracutaneous ultrastructural alterations in pseudoxanthoma elasticum. *Ultrastruct Pathol*. 2003; 27:375-384.
 38. Badimon L, Vilahur G. Thrombosis formation on atherosclerotic lesions and plaque rupture. *J Intern Med*. 2014; 276:618-632.

(Received January 7, 2018; Revised February 18, 2018; Accepted February 19, 2018)