

Osteogenesis imperfecta type III/Ehlers-Danlos overlap syndrome in a Chinese man

Yanqin Lu^{1,2}, Yanzhou Wang³, Frank Rauch⁴, Hu Li^{1,2,§}, Yao Zhang^{1,2}, Naixiang Zhai^{1,2}, Jian Zhang^{1,2}, Xiuzhi Ren^{5,*}, Jinxiang Han^{1,2,*}

¹Key Laboratory for Rare & Uncommon Diseases of Shandong Province, Shandong Medicinal Biotechnology Centre, Shandong Academy of Medical Sciences, Ji'nan, China;

²School of Medicine and Life Sciences, University of Ji'nan-Shandong Academy of Medical Sciences, Ji'nan, China;

³Department of Paediatric Surgery, Shandong Provincial Hospital, Ji'nan, China;

⁴Shriners Hospital for Children and McGill University, Montreal, Quebec, Canada;

⁵Department of Orthopaedic Surgery, The People's Hospital of Wuqing District, Tianjin, China.

Summary

Osteogenesis imperfecta (OI) and Ehlers-Danlos syndrome (EDS) are rare genetic disorders that are typically inherited in an autosomal dominant manner. Few cases of OI/EDS overlap syndrome have been documented. Described here is a 30-year-old Chinese male with OI type III and EDS. Sequencing of genomic DNA revealed a heterozygous *COL1A1* mutation (c.671G>A, p.Gly224Asp) that affected the N-anchor domain of the alpha 1 chain of collagen type I. Ultrastructural analysis of a skin biopsy specimen revealed thin collagen fibers with irregular alignment of collagen fibers. These findings have expanded the genotypic spectrum of the OI/EDS overlap syndrome.

Keywords: Ehlers-Danlos syndrome, osteogenesis imperfecta, transmission electron microscopy, collagen type I

1. Introduction

Osteogenesis imperfecta is an inherited connective tissue disorder that is mainly characterized by increased bone fragility, short stature, and blue or grey sclera. The condition may also be associated with hearing loss, dentinogenesis imperfecta, and scoliosis (1,2). OI has a wide-ranging clinical spectrum, with type I being the mildest form, types III and IV being more severe forms, and type II usually being lethal (1,3). Mutations in the *COL1A1* and *COL1A2* genes encoding pro- α 1 and pro- α 2(I) chains of type I procollagen are present in the large majority of patients with a typical OI phenotype (4,5). Missense mutations are the most common, and especially

glycine substitutions in the helical regions of the pro- α 1(I) and pro- α 2(I) chains.

Mutations in *COL1A1* and *COL1A2* can also lead to Ehlers-Danlos syndrome types VIIA and VIIB when they affect exon 6 of either gene (6,7). Mutations in this region can impede the cleavage of N-proteinase and the normal interhelical cross-linking of collagen fibers (8,9). Individuals affected by such mutations usually suffer from bilateral hip dislocation and severe joint hypermobility (4,7).

A few patients with OI/EDS overlap syndrome have been described as having the clinical symptoms of both OI and EDS with different levels of joint laxity, skin hyperextensibility, atrophic scars, and easy bruising (10-21). OI/EDS phenotypes can be caused by mutations affecting the amino-terminal portion of the collagen type I triple helix with some apparent genotype-phenotype correlation. Patients with mutations that affect the most N-terminal portion of the triple helix, such as exon 7 skipping and p.Gly13Asp substitution, present with relatively mild OI and more severe EDS, whereas individuals harboring mutations in exon 11 (such as p.Gly88Glu in *COL1A1*) have more severe OI and a milder EDS phenotype (8). Described here is a Chinese

[§]Present address, Institute of Medicinal Biotechnology, Chinese Academy of Medical Sciences and Peking Union Medical College, Beijing, China.

*Address correspondence to:

Dr. Jinxiang Han, Shandong Academy of Medical Sciences, 18877 Jingshi Road, 250062 Ji'nan, China.
E-mail: samshjx@sina.com

Dr. Xiuzhi Ren, The People's Hospital of Wuqing District, 100 West Yongyang Road, Tianjin 301700, China.
E-mail: xiuzhiren@hotmail.com

man with OI/EDS overlap syndrome with a heterozygous mutation affecting the N-terminal portion of the pro α 1(I) triple helical domain.

2. Subjects and Methods

2.1. Patient

On examination at the age of 30 years, the patient weighed 28 kg, was 120 cm in height, and had a head circumference of 60 cm. His first femoral fracture had occurred no more than 20 days after birth. He could not walk until he was 7 years old and he had experienced more than 60 fractures during his life. Most of these were bilateral femoral fractures; fractures to the upper limbs and tibiae were less frequent.

The patient's facial features included an oval-shaped face, protuberant eyes and jaw, grayish-blue sclerae, and tooth loss. Severe kyphoscoliosis was present, and both radial heads were dislocated (Figure 1A, 1B, *Supplementary material*, <http://www.irdrjournal.com/action/getSupplementalData.php?ID=17>). Mild skin hyperextensibility and dislocation of the interphalangeal joints were also evident (Figure 1C, 1D, *Supplementary material*, <http://www.irdrjournal.com/action/getSupplementalData.php?ID=17>). The patient suffered from easy bruising. He had a scar on the lower portion of his deformed chest and typical symptoms of marked ligamentous laxity and generalized joint hypermobility. He had a prominent, asymmetric thorax and respiratory distress, which limited his ability to walk. His hearing and vision were normal.

The patient had a Beighton score of 6, but he could not put his hands flat on the floor or bend either elbow backwards due to radial head dislocation and bone deformities. The tourniquet test was positive. X-ray radiography indicated that long bones of the lower limbs were deformed (Figure 1E) and that the heads of both radii were dislocated (Figure 1F).

2.2. Methods

This study was conducted in accordance with the Code of Ethics of the World Medical Association (Declaration of Helsinki) for experiments involving humans. This study was approved by the Ethical Committee of the Shandong Medicinal Biotechnology Center, and informed consent was obtained from the patient. Blood was collected from the patient, his mother, and three of his four sisters after their informed consent was obtained. The patient's medical history and radiographs were obtained from hospital records.

Genomic DNA was extracted using the E.Z.N.A.[®] Blood DNA Kit according to the manufacturer's instructions (Omega Bio-Tek, Norcross, GA, USA). A total of 65 PCR reactions were performed to cover the entire coding regions, intron-exon boundaries, and flanking intronic sequences of *COL1A1* and *COL1A2* (22). PCR products were subjected to direct DNA sequencing (Beijing Genomics Institute, Qingdao, China). Genetic variations were analyzed with the software Mutation Surveyor 4.0 (SoftGenetics LLC, State College, PA, USA) using the human osteogenesis imperfecta variant database. The following software was used to assess the potential effect of a mutation on functional changes: Polyphen; Align GVGD, SIFT Human Coding SNPs, and RESCUE-ESE.

A skin biopsy sample was obtained from the proband, fixed in 2.5% glutaraldehyde, post-fixed in 1% OsO₄, and stained with 2% uranyl acetate. After dehydration, the specimen was embedded in Spurr's plastic resin. Thin sections (60 nm) were cut and placed on formvar-coated grids and then counterstained with 7% methanolic uranyl acetate and lead citrate. The stained grids were viewed with a transmission electron microscope (JEOL-1200ES, Japan Spectroscopic, Tokyo, Japan) and images were photographed. The diameter of collagen fibers was determined using the software Image-Pro Plus 6.0.

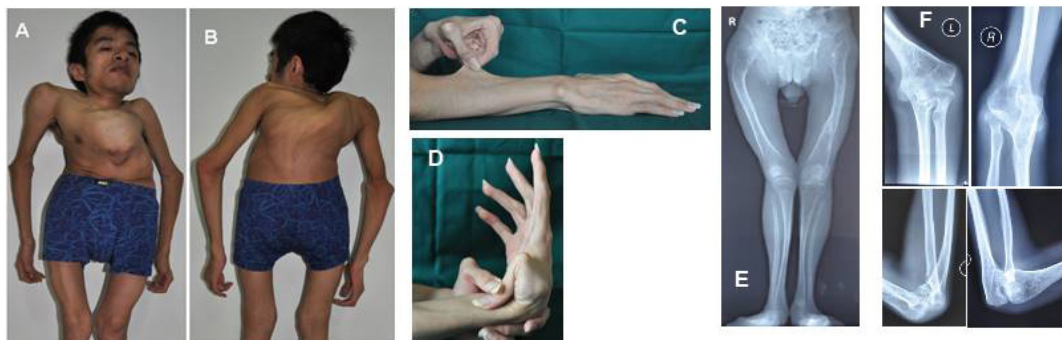


Figure 1. Clinical and radiographic features of the patient. (A), The patient presented with an oval face, protuberant eyes, a short thorax, distinctive thoracic asymmetry, and dislocation of both radial heads; (B), Severe kyphoscoliosis; (C), Skin hyperextensibility; (D), Dislocation of the interphalangeal joints; (E), The femoral neck was thick and short, both femoral shafts were irregular, and tibial and fibular shafts on both sides were slender with expanded ends; (F), Bone structures were thin on both sides of the elbow, with some expansion at the epiphysis. The olecranon process was small, and subluxation of the elbow was also present.

3. Results and Discussion

Sequencing revealed a heterozygous c.671G>A (p.Gly224Asp) in exon 9 of COL1A1 in the patient but not in his family members (Figures 2A and 2B). Polyphen, Align GVGD, and SIFT analyses predicted that this substitution would have a damaging effect.

Transmission electron microscopy revealed irregularly arranged thin collagen fibers (Figure 2C). Quantification of the diameter of the collagen fibers revealed that they were significantly thinner in the patient compared to those in the healthy controls (Figure 2D).

Previously reported COL1A1 mutations associated with OI/EDS overlap syndrome mostly result from glycine substitutions in the aminoterminal portion of the triple helical domain (Table 1), but three Y-position substitutions of arginine by cysteine, alanine by valine, and one C-propeptide mutation have also been reported

(4,15,17,20).

The current study reported on a Chinese man with OI/EDS overlap syndrome who presented with the typical features of severe OI. He also has marked ligamentous laxity, joint hypermobility, and skin hyperextension. These features were more severe than what is usually seen in OI and are compatible with a diagnosis of EDS.

The current authors previously identified a heterozygous p.Gly224Asp mutation in COL1A1 and submitted it to the OI mutation database (13,14). This mutation is located in the anchor domain of type I collagen. Besides this mutation, a c.3733G>A (pval1245Met) variation in the COL1A2 gene was also noted, though this was later excluded by the Exome Aggregation Consortium (ExAC) browser. A mutation of p.Gly224Asp in COL1A1 was noted by Liu *et al.*, who regarded a patient with this mutation as having OI type I (23). The anchor domain consists of the first 85

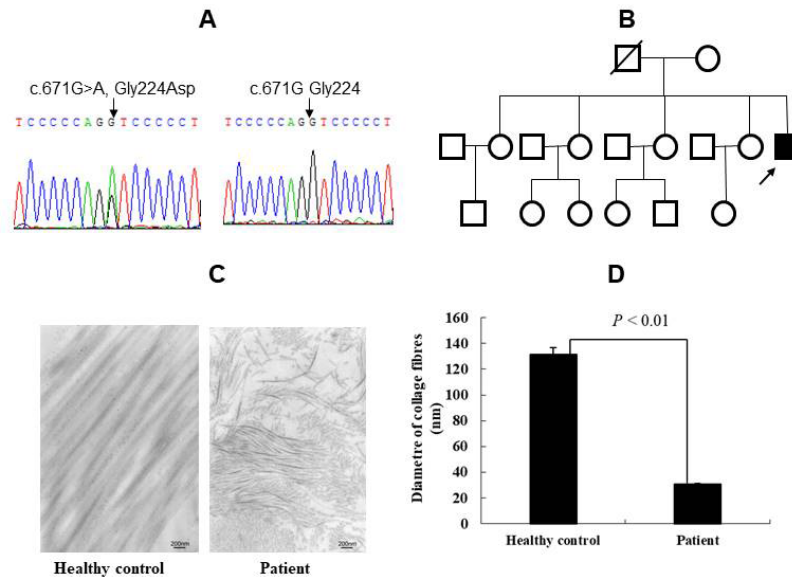


Figure 2. COL1A1 gene mutation and the structure and diameter of collagen fibers. (A), There is a heterogeneous G>A mutation (p.Gly224Asp) of COL1A1 in the patient but not in healthy family members; (B), Pedigree map of the patient; (C), Irregular fibers in the patient; (D) Collagen fibers with significantly smaller diameters in the patient.

Table 1. Overview of COL1A1 mutations causing OI/EDS overlap syndrome

Exon	DNA change	aa substitution	Position	Ref.
7	c.563G>A	p.Gly188Asp	Gly	Malfait <i>et al.</i> , 2013 (18)
7	c.572G>A	p.Gly191Asp	Gly	Cabral <i>et al.</i> , 2005 (8)
07 i	c.588+4A>T	-	-	Cabral <i>et al.</i> , 2005 (8)
8	c.590G>A	p.Gly197Asp	Gly	Marini <i>et al.</i> , 2007 (4)
8	c.607G>T	p.Gly203Cys	Gly	Malfait <i>et al.</i> , 2013 (18)
8	c.609G>A	p.Gly203Val	Gly	Cabral <i>et al.</i> , 2005 (8)
8	c.617G>A	p.Gly206Asp	Gly	Belgium:Ghent (13,14)
8	c.634G>C	p.Gly212Arg	Gly	Cabral <i>et al.</i> , 2005 (8)
9	c.643G>A	p.Gly215Ser	Gly	Vandersteen <i>et al.</i> , 2014 (21)
11	c.761G>A	p.Gly254Glu	Gly	Cabral <i>et al.</i> , 2005 (8)
11	c.796G>A	p.Gly266Glu	Gly	Cabral <i>et al.</i> , 2005 (8)
44	c.3106C>T	p.Arg1036Cys	Y	Lund <i>et al.</i> , 2008 (15)
44	c.3196C>T	p.Arg1066Cys	Y	Cabral <i>et al.</i> , 2007 (16)
37,44	c.2522delC+ c.3196C>T	p.Pro841Leufs*266+ p.Arg1066Cys	Y	Ackermann <i>et al.</i> , 2017 (19)
48	c.3521C>T	p.Ala1174Val	Y	Shi <i>et al.</i> , 2015 (20)
49	c.3790A>G	p.Met1264Val	Met	Symoens <i>et al.</i> , 2004 (17)

residues of the helical region (residues 179 to 263 of the alpha 1 chain of procollagen type I) and is essential for the correct folding and stability of the N-terminal end of the triple helix. Therefore, mutations in this domain usually lead to the unfolding of the helix and an abnormal conformation of the N-propeptide cleavage site. Hence, N-propeptide processing by procollagen I N-proteinase is delayed, leading to defective collagen crosslinking and thus the EDS phenotype (9). Direct evidence for a defective collagen structure was found in a skin biopsy specimen that also had collagen fibers with a thin diameter. These changes may contribute to the clinical observation of very thin and velvety skin.

The glycine to aspartate change that was found in the current patient introduces a charged amino acid that presumably leads to severe disruption of the triple helix. This may explain why the current patient had more severe bone fragility than a previously reported individual with a glycine-to-cysteine substitution at codon 224, which was associated with an OI type I phenotype (24). A glycine to aspartic acid change in exon 6 to 11 has been noted in phenotypes of both OI and OI/EDS overlap syndrome. Severe and moderate phenotypes are more prevalent than a mild phenotype in patients with OI (13,14).

In conclusion, this report describes a man with OI/EDS overlap syndrome caused by a novel heterozygous p.Gly224Asp mutation in *COL1A1*. These findings have expanded the genotypic spectrum of the OI/EDS overlap syndrome.

Web Resources

Align GVGD: http://gvgd.iarc.fr/agvgd_input.php
 Osteogenesis Imperfecta Variant database: <http://www.le.ac.uk/genetics/collagen>
 Polyphen: <http://genetics.bwh.harvard.edu/pph>
 RESCUE-ESE: <http://genes.mit.edu/burgelab/rescue-ese/>
 SIFT: http://provean.jcvi.org/genome_submit.php

Acknowledgements

The authors wish to thank the patient and his family members who participated in this study. This study was supported by grants from the Shandong Key Research and Development Plan (2016ZDJS07A10, 2016GSF201222,) and the Shandong Provincial Natural Science Foundation of China (2015ZRC03171).

References

- Sillence DO, Senn A, Danks DM. Genetic heterogeneity in osteogenesis imperfecta. *J Med Genet.* 1979; 16:101-116.
- Byers PH, Cole WJ. Connective tissue and its heritable disorders. Molecular, genetic, and medical aspects (Royce PM, Steinmann B. eds.) 2nd Ed., Wiley-Liss, Inc., New York, USA, 2002; pp. 385-430.
- Rauch F, Glorieux FH. Osteogenesis imperfecta. *Lancet.* 2004; 363:1377-1385.
- Marini JC, Forlino A, Cabral WA, et al. Consortium for osteogenesis imperfecta mutations in the helical domain of type I collagen: Regions rich in lethal mutations align with collagen binding sites for integrins and proteoglycans. *Hum Mutat.* 2007; 28:209-221.
- Bardai G, Moffatt P, Glorieux FH, Rauch F. DNA sequence analysis in 598 individuals with a clinical diagnosis of osteogenesis imperfecta: Diagnostic yield and mutation spectrum. *Osteoporos Int.* 2016; 27:3607-3613.
- Beighton P, De Paepe A, Steinmann B, Tsipouras P, Wenstrup RJ. Ehlers-Danlos syndromes: Revised nosology, Villefranche, 1997. Ehlers-Danlos National Foundation (USA) and Ehlers-Danlos Support Group (UK). *Am J Med Genet.* 1998; 77:31-37.
- Holmes DF, Watson RB, Steinmann B, Kadler KE. Ehlers-Danlos syndrome type VII B. Morphology of type I collagen fibrils formed *in vivo* and *in vitro* is determined by the conformation of the retained N-propeptide. *J Biol Chem.* 1993; 268:15758-15765.
- Cabral WA, Makareeva E, Colige A, Letocha AD, Ty JM, Yeowell HN, Pals G, Leikin S, Marini JC. Mutations near amino end of $\alpha 1(I)$ collagen cause combined osteogenesis imperfecta/Ehlers-Danlos syndrome by interference with N-propeptide processing. *J Biol Chem.* 2005; 280:19259-19269.
- Makareeva E, Cabral WA, Marini JC, Leikin S. Molecular mechanism of $\alpha 1(I)$ -osteogenesis imperfecta/Ehlers-Danlos syndrome: Unfolding of an N-anchor domain at the N-terminal end of the type I collagen triple helix. *J Biol Chem.* 2006; 281:6463-6470.
- Raff ML, Craigen WJ, Smith LT, Keene DR, Byers PH. Partial *COL1A2* gene duplication produces features of osteogenesis imperfecta and Ehlers-Danlos syndrome type VII. *Hum Genet.* 2000; 106:19-28.
- Chiodo AA, Hockey A, Cole WG. A base substitution at the splice acceptor site of intron 5 of the *COL1A2* gene activates a cryptic splice site within exon 6 and generates abnormal type I procollagen in a patient with Ehlers-Danlos syndrome type VII. *J Biol Chem.* 1992; 267:6361-6369.
- Nicholls AC, Valler D, Wallis S, Pope FM. Homozygosity for a splice site mutation of the *COL1A2* gene yields a non-functional pro $\alpha 2(I)$ chain and an EDS/OI clinical phenotype. *J Med Genet.* 2001; 38:132-136.
- Dalgleish R. The human type I collagen mutation database. *Nucleic Acids Res.* 1997; 25:181-187.
- Dalgleish R. The Human Collagen Mutation Database 1998. *Nucleic Acids Res.* 1998; 26:253-255.
- Lund A, Joensen F, Christensen E, Duno M, Skovby F, Schwartz M. A novel arginine-to-cysteine substitution in the triple helical region of the $\alpha 1(I)$ collagen chain in a family with an osteogenesis imperfecta/Ehlers-Danlos phenotype. *Clin Genet.* 2008; 73:97-101.
- Cabral WA, Makareeva E, Letocha AD, Scribanu N, Fertala A, Steplewski A, Keene DR, Persikov AV, Leikin S, Marini JC. Y-position cysteine substitution in type I collagen ($\alpha 1(I)$ R888C/p.R1066C) is associated with osteogenesis imperfecta/Ehlers-Danlos syndrome phenotype. *Hum Mutat.* 2007; 28:396-405.
- Symoens S, Nuytinck L, Legius E, Malfait F, Coucke PJ, De Paepe A. Met>Val substitution in a highly conserved

- region of the pro- α 1(I) collagen C-propeptide domain causes alternative splicing and a mild EDS/OI phenotype. *J Med Genet.* 2004; 41:e96.
18. Malfait F, Symoens S, Goemans N, Gyftodimou Y, Holmberg E, Lopez-Gonzalez V, Mortier G, Nampoothiri S, Petersen MB, De Paepe A. Helical mutations in type I collagen that affect the processing of the amino-propeptide result in an Osteogenesis Imperfecta/Ehlers-Danlos Syndrome overlap syndrome. *Orphanet J Rare Dis.* 2013; 8:78.
 19. Ackermann AM, Levine MA. Compound heterozygous mutations in *COL1A1* associated with an atypical form of type I osteogenesis imperfecta. *Am J Med Genet A.* 2017. doi: 10.1002/ajmg.a.38238.
 20. Shi X, Lu Y, Wang Y, Zhang YA, Teng Y, Han W, Han Z, Li T, Chen M, Liu J, Fang F, Dou C, Ren X, Han J. Heterozygous mutation of c.3521C>T in *COL1A1* may cause mild osteogenesis imperfecta/Ehlers-Danlos syndrome in a Chinese family. *Intractable Rare Dis Res.* 2015; 4:49-53.
 21. Vandersteen AM, Lund AM, Ferguson DJ, Sawle P, Pollitt RC, Holder SE, Wakeling E, Moat N, Pope FM. Four patients with Sillence type I osteogenesis imperfecta and mild bone fragility, complicated by left ventricular cardiac valvular disease and cardiac tissue fragility caused by type I collagen mutations. *Am J Med Genet A.* 2014; 164a:386-391.
 22. Lu Y, Ren X, Wang Y, Li T, Li F, Wang S, Xu C, Wu G, Li H, Li G, Zhao F, Wang Z, Mo X, Han J. Mutational and structural characteristics of four novel heterozygous C-propeptide mutations in the pro α 1(I) collagen gene in Chinese osteogenesis imperfecta patients. *Clin Endocrinol (Oxf).* 2014; 80:524-531.
 23. Liu Y, Asan, Ma D, *et al.* Gene mutation spectrum and genotype-phenotype correlation in a cohort of Chinese osteogenesis imperfecta patients revealed by targeted next generation sequencing. *Osteoporos Int.* 2017; 28:2985-2995.
 24. Byers PH, Wallis GA, Willing MC. Osteogenesis imperfecta: Translation of mutation to phenotype. *J Med Genet.* 1991; 28:433-442.
- (Received January 20, 2018; Revised February 20, 2018; Accepted February 21, 2018)