

# Situs viscerum inversus and abdominal aortic aneurysm: A systematic review of a rare association

Paolo Ossola<sup>1,\*</sup>, Federico Mascioli<sup>2</sup>, Andrea Pierre Luzzi<sup>3</sup>, Lorenzo Epis<sup>4</sup>, Diego Coletta<sup>5,6</sup>

<sup>1</sup> Department of Surgery, Cardinal Massaia Hospital, Corso Dante Alighieri, Asti, Italy;

<sup>2</sup> Department of Surgery, Casa di Cura Privata Pierangeli Srl, Pescara, Italy;

<sup>3</sup> Department of Medicine DIMI, University of Genova, Genova, Italy;

<sup>4</sup> Department of Surgical Sciences DISC, University of Genova, Genova, Italy;

<sup>5</sup> Department of Surgical Sciences, Policlinico Umberto I University Hospital, Sapienza University of Rome, Rome, Italy;

<sup>6</sup> Hepatopancreatobiliary Surgery, IRCCS Regina Elena National Cancer Institute, Rome, Italy.

**SUMMARY** Situs viscerum inversus (SVI) is a very rare condition in that abdominal and thoracic organs are located reversed. Abdominal aortic aneurysm (AAA) is a life-threatening pathology due to progressive aortic enlargement until the rupture. The association between SVI and AAA is very infrequent. The aim of this study is to identify the surgical procedures available to treat AAA in SVI. We performed a literature review of all studies about AAA in SVI patients, analyzing PubMed/MEDLINE, EMBASE, Web of Science (WOS), Google Scholar databases. The survey includes all publications until June 2023. The outcomes include demographic findings, type of surgical procedure, intraoperative and postoperative complications, follow-up. A total of 12 studies, including 12 patients, were considered eligible for the review. AAA mean size was 70.5 mm (range: 55–90 mm); the most common localization was in the infrarenal aortic portion. 6 studies reported data on elective surgery, and 6 on emergency procedures. In one case endovascular treatment was performed. No intraoperative complications are reported; 3 postoperative complications are registered. Medium follow-up period was 13.5 months (range: 3–60). According to the available literature, the treatment of AAA in SVI is feasible and does not show an incremented morbidity compared to patients with a normal visceral configuration. This treatment seems to be effective also in case of endovascular treatment. AAA treatment in SVI should be performed (especially in elective settings) in high volume centers where it is possible to bring on collaboration across different surgical specialists.

**Keywords** situs viscerum inversus, aortic aneurysm, surgery

## 1. Introduction

Situs viscerum inversus (SVI) is a rare congenital condition in which the organ's position is completely reversed, affecting both abdominal and thoracic compartments (1,2). The incidence of SVI ranges between 1:5,000 and 1:20,000 of newborns (1), with no evidence of gender inheritance (3). This condition is due to a complete failure of the normal left-right asymmetry (2), even if the exact SVI etiology is yet unclear (3). To date, the most widely accepted theory is the deregulation of Sonic Hedgehog (Shh) protein during the third week of embryonic development (4), while it is known that the genetic deletions in KIF3-A or KIF3-B are responsible of alterations in visceral disposition within the abdomen/thorax (2).

Six risk factors were recently identified for SVI (2): *i*) family history of heart defects, *ii*) family history of noncardiac anomalies, *iii*) maternal diabetes, *iv*) antitussive use during pregnancy, *v*) paternal smoking, and *vi*) low socioeconomic status. Furthermore, SVI could be an incidental condition or could occur in conjunction with several pathological conditions such as primary ciliary dyskinesia, polysplenia, Ivermark's syndrome. The association between SVI and vascular anomalies are rare and, in particular, the prevalence of abdominal aortic aneurysm (AAA) in SVI patients is currently unknown. When SVI is not associated with the anamnestic history of the patient, the preoperative study and the surgical procedure are not standardizable.

The aim of this systematic review is to highlight how AAA is diagnosed and treated when associated with SVI.

## 2. Literature search strategy

We conducted a systematic review of published studies in accordance with Preferred Reporting Items for Systematic Review and Meta-Analysis (PRISMA) guidelines (5) to identify studies reporting abdominal aortic aneurysm treatment in patients with SVI.

The population, intervention, comparator, outcome, and study design (PICOS) criteria are reported in Supplemental Table S1 (<https://www.irdrjournal.com/supplementaldata/178>). Supplemental Table S2 (<https://www.irdrjournal.com/supplementaldata/178>) reports the National Institutes of Health (NIH) quality assessment for each study considered for this research.

PubMed/MEDLINE, EMBASE, Web of Science (WOS), Google Scholar databases were surveyed using a combination of the following search terms: "situs viscerum inversus AND abdominal aortic aneurysm", "situs inversus AND aortic abdominal aneurysm", "situs organum inversus AND abdominal aortic aneurysm". The survey includes all publications until 30 June 2023.

All publications considering the AAA treatment in patients with SVI in both elective or emergency settings were considered for further selection. Full-text publications considered for inclusion were reviewed by two independent assessors (Paolo Ossola and Diego Coletta), and the references therein were further scrutinized to find additional publications unreported in the previous survey. Only publications in English, Spanish or Italian language were selected. All concerns in the publications selected were discussed and consensus was sought across all authors. When agreement was not found, the publication of concern was excluded from the selection

pool.

In accordance with the pre-established agreement, extracted data included: study design, country where the study was performed, date of publication, number of patients, age, gender, type of surgical procedure, intraoperative and postoperative complications, length of hospital stay (LOS), and follow-up. Results are reported as descriptive statistics with mean and minimum-maximum range.

## 3. Studies selection

The first literature survey resulted in 326 papers. After the first screening, 295 publications were excluded because off-topic title and abstract or duplicate. Eventually, 12 full-text publications (4,6-16), accounting for 12 patients, met the selection criteria and are included in our review (Figure 1): 10 are written in English (4,7,8,10-16), one in Spanish (6), and one in Italian (9).

## 4. Characteristics of studies

The studies selected are conducted in various countries: 5 studies are in Europe (4,7-10), 1 in the United State of America (11), 2 in Canada (12,13), 1 in China (14), 2 in Japan (15,16), and one in Colombia (6).

All the studies are case reports of a single patient. Surgery procedures are performed in general surgery division in 2 reports (4,10), vascular surgery departments in 5 cases (7-9,11,14), and 3 cases are treated in cardio-vascular departments (13,15,16). In 2 cases (6,12), a team of vascular and general surgery specialists performed the procedure.

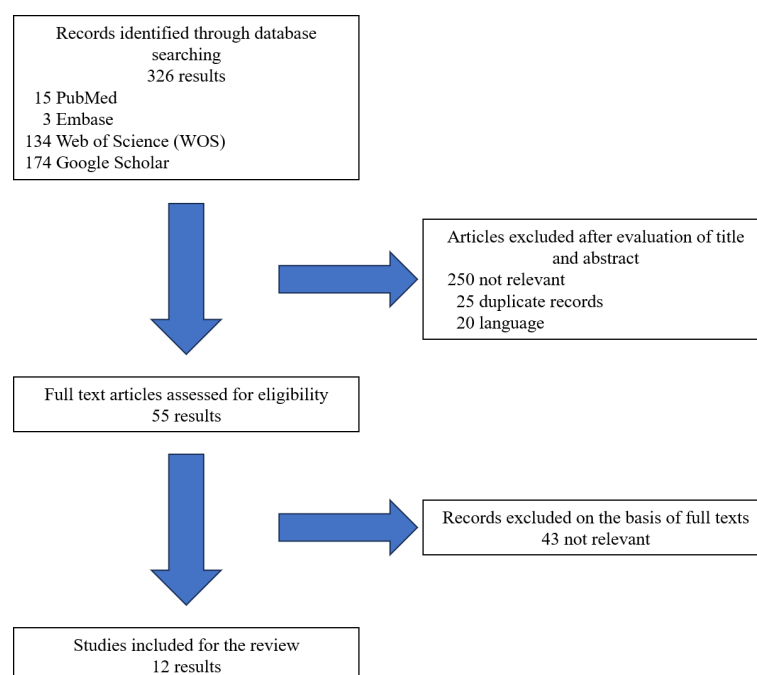


Figure 1. PRISMA flow-chart for studies selection.

**5. Demographic findings**

Demographic findings are reported in Table 1.

Pathological anamnesis is reported in 7 studies (4,6-8,12,14,16): 7 patients are affected by arterial hypertension (4,6-8,12,14,16), and two cases also by ischemic heart disease previously (14,16). AAA size is reported in 10 studies (4,6-9,11,12-15): the mean AAA diameter was 70.5 mm (range: 55-90 mm); also AAA localization is reported in all studies, and summarized in Figure 2. The most common localization in normal conformed patients is infrarenal aortic portion, and juxtarenal aneurysm accounts for about 15% (17). Our series, accounting 8 infrarenal aneurysms (4,6,8,10,11,13-15), 1 juxtarenal (12), 1 pararenal (7) and two infrarenal aneurysms associated with left common iliac artery aneurysm (9,16), didn't differ from data derived from normal conformed patients.

SVI was a known condition in 8 cases (4,6,7,11-15); in 3 patients (8,9,16), SVI were identify by a computed tomography scan contrast enhanced (CT) performed for prostate hypertrophy study (8), and for abdominal pain study (9,16). In one case (10), SVI was diagnosed by abdomen ultrasound scan (US) in a patient with abdominal pain.

**6. Operative findings**

The present review analyzed studies involving surgery in both elective and emergency settings: 6 studies reported data on elective surgery (4,7,8,11,13,14), and 6 on emergency procedures (6,9,10,12,15,16).

No intraoperative complications are reported. In 3 cases, patients experienced postoperative complications: a case of acute distal femoral, popliteal and pedidia right arteries ischemia during the immediate postoperative period treated with thromboendarterectomy (6); a respiratory failure associated with deep vein thrombosis of the right leg treated with warfarin therapy (15), and postoperative fever (13). All postoperative complications are reported in patients undergoing emergency surgery.

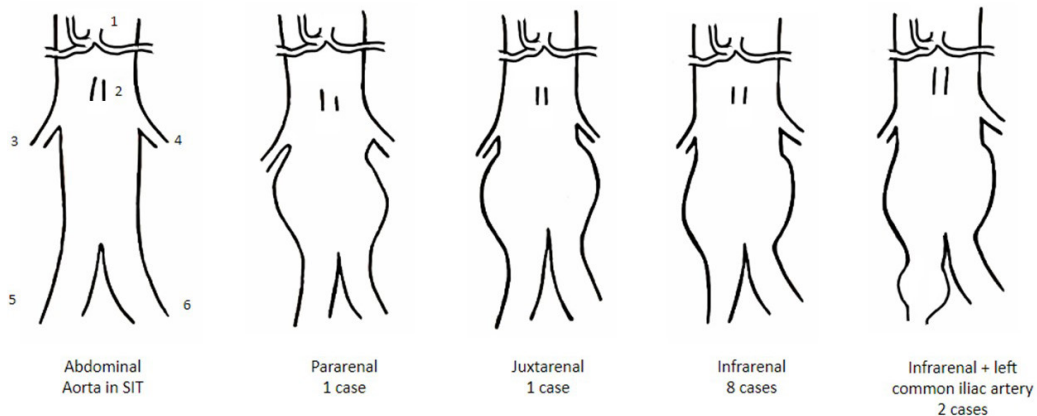
LOS is reported in 6 studies (4,7,9,12,14,15) with mean LOS of 12.5 days and a range of 3–46 days. Data on postoperative follow-up are reported in 8 studies (4,6-8,13-16) with a medium observation period of 13.5 months (range: 3–60)

**7. Discussion**

This systematic review focuses on the actual AAA treatment in patients with SVI. The extreme unlikelyhood

**Table 1. Demographic findings of Literature**

Author (Ref), Year	Country	Sex	Age (Years)	SIT known	Diagnosis of AAA	AAA dimension (mm)	AAA localization
Bonnely (4), 2022	Spain	M	58	Yes	CT	56	infrarenal
Télez-Beltrán (6), 2020	Colombia	F	56	Yes	US + CT	80	infrarenal
Gatta (7), 2020	Italy	M	73	Yes	US + CT	60	pararenal
Cwinn (12), 2016	Canada	F	82	Yes	CT	90	iuxtarenal
Riera Hernández (8), 2015	Spain	M	69	No	CT	60	infrarenal
Chan (14), 2010	China	M	81	Yes	CT	75	infrarenal
Kimura (15), 2008	Japan	F	80	Yes	CT	85	infrarenal
Kato (16), 2006	Japan	M	75	No	CT	na	infrarenal + left common iliac artery
Baccellieri (9), 2006	Italy	M	70	No	CT	55	infrarenal + left common iliac artery
Occhionorelli (10), 1998	Italy	F	76	No	US+CT	na	infrarenal
Huston (11), 1990	USA	M	84	Yes	CT	70	infrarenal
Ricci (13), 1989	Canada	M	79	Yes	US + arteriography	74	infrarenal



**Figure 2. Conformation of normal aorta in SVI and type of AAA in SVI reported in Literature.** 1: celiac trunk; 2: superior mesenteric artery; 3: left renal artery; 4: right renal artery; 5: left common iliac artery; 6: right common iliac artery.

of this condition is evident in the low literature studies on the topic: in our survey we identified only 12 studies (4,6-16) reporting data on 12 patients.

### 7.1. Clinical presentation

In people with normal visceral anatomy, the clinic presentation of AAA varies: in some cases it could be completely asymptomatic, in this situation AAA is an incidental finding during routine exams. In fact, AAA is due to a progressive enlargement of the abdominal aortic diameter, with the stretch of all three artery layers, determining a thin and weak aortic wall (18). In other cases, patients complain of abdominal pain or hemorrhagic shocks: the main complication of AAA, and in general of an artery aneurysm, is its rupture with hemoperitoneum (or hemo-retroperitoneum) with hemorrhagic shock and death (19).

SVI could represent only a variation of a normal anatomy with no alteration in life and health expectancy of the patient being an occasional finding during routine clinical exams. Otherwise, SVI could be an aspect of a group of pathological conditions defined as "syndromic conditions". The most common syndromic conditions are primary ciliary dyskinesia, polysplenia, and Ivermark's syndrome.

Cardiac malformations are not infrequent in SVI patients (3–9%) (2); while the most common vascular anomalies are the interrupted inferior vena cava (20%) and preduodenal portal vein (42%) (2). In the rare case of SVI, AAA could appear also as an intestinal occlusion (20).

### 7.2. Diagnosis

AAA diagnosis is obtained through US and contrast enhancement CT: obviously, the same techniques allow to detect any anomalies in the organs topology in the body. So, often, AAA and SVI are diagnosed at the same time.

US is a first level tool able to identify AAA, its localization along the aorta, describe the diameter, the status (*i.e.* the rupture or the fissuring), and the blood flow inside the aneurysm sac. US is fast, does not need injection of any contrast fluids, and does not expose the patient to ionizing radiations. The main limit of US is that the sensibility of this technique is linked to the operator ability; nevertheless, US is a gold standard in the follow-up, particularly in case of young or female patients, avoiding radiation exposure (21). CT scan with vascular acquisitions is mandatory in the definitive description and for treatment planning. If AAA is associated with SVI, CT allows to identify the anomalies in organs location, to verify the presence of vascular anomalies, that is, anomalies in vein or artery number, or course.

In the literature, 11 cases (4,6-12,14-16) underwent

preoperative CT, in one case AAA was diagnosed with US and arteriography (13): this last case was treated in 1989 when CT was not largely available. CT remains the most relevant imaging method for AAA and SVI diagnosis at the same time.

### 7.3. Treatment

In patients with normal disposition of internal organs, unruptured AAA is treated when the diameter is  $\geq 5.5$  cm in male or  $\geq 5$  cm in female or when the growth rate is  $\geq 0.5$  cm in 6 months (22). When ruptured, AAA treatment is mandatory in emergency settings. In case of SVI, the indications for AAA treatment are the same as in normal patients.

In the surveyed publications, the mean AAA diameter was 70.5 mm (range: 55–90 mm), 6 cases (6,9,10,12,15,16) were treated in emergency settings, and 6 (4,7,8,11,13,14) cases were planned as elective procedures. Technical approaches for AAA vary: in this work 11 cases (4,6-13,15,16) were treated with open approach with aneurysmectomy and graft interposition. Chan *et al.* (14) reported the first case of AAA in SVI endovascular repair: the 81 years-old patient with a medical history of SVI and previous abdominal surgery for colon cancer, was treated with a Cook Zenith endovascular device and discharged on 3<sup>rd</sup> postoperative day without complications. Chan *et al.* (14) affirmed that endovascular repair is safe and feasible also in case of SVI, with not specific difficulties compared to normal-topology patients. Certainly, endovascular approaches should be reserved in high expertise and large volume vascular Departments.

Laparotomic approach for AAA in SVI patients was performed by general and vascular surgeons, especially in emergency conditions. In our series 2 cases (6,12) were treated by a multidisciplinary surgical team consisting of general and vascular surgeons, 5 patients (7-9,11,14) by vascular surgeons, 2 cases (4,10) by general surgeons, 3 cases (13,15,16) by cardio-vascular surgeons. The possibility to treat complex cases by multispecialistic teams (*e.g.* general and vascular surgery, cardio-vascular surgery, or other), represent an advantage in terms of safety and good results of the surgical procedure.

### 7.4. Complications

Interestingly, no intraoperative complications are registered: this finding could be explained considering that AAA in SVI is a very rare condition and preferably treated in high volume and expertise centers. On the other hand, because AAAs in SVI are treated also in emergency settings, the absence of intraoperative complications could reflect the absence of technical differences compared to AAA in normal conformed patients.



Postoperative complications are registered in emergency conditions: Beltran *et al.* (6) reported a case of acute distal femoral-popliteal and pedicled right arteries ischemia treated with thromboembolectomy through the femoral artery with complete ischemia resolution. The patient described by Kimura *et al.* (15) developed respiratory failure and deep vein thrombosis of the right leg; the patient was extubated on 14 postoperative day with anticoagulation therapy with warfarin continued for the deep vein thrombosis. Ricci *et al.* (13) reported a postoperative course complicated by transitory fever, that could be due to the body reaction to the graft.

Operative time is reported in only 2 studies: Beltran *et al.* (6): 96 minutes and Kimura *et al.* (15) 190 minutes: for this reason it is not possible to know if SVI increases the operative time. The median LOS was 12.5 days (range 3–46) and is reported in 6 studies (4,7,9,12,14,15).

### 7.5. Follow-up

Follow-up is mandatory to early identify graft leak, the graft thrombosis, or rupture; in our review the mean follow-up resulted in 13.5 months (range: 3–60), and was reported in 8 studies (4,6,7,8,13-16). CT is the gold standard for imaging follow-up, even if also US could be adopted in order to reduce radiological exposition. As of today, no specific protocols are available for AAA in SVI follow-up.

## 8. Conclusion

The analysis of the scientific literature shows that the treatment of AAA in SVI is feasible and does not show an incremented morbidity compared to patients with a normal visceral configuration. This treatment seems to be effective also in case of endovascular treatment. The preoperative imaging study with CT is mandatory before performing any invasive treatment in SVI patients, in order to identify potential alteration in the vessels course. However, the AAA treatment in SVI should be performed (especially in elective settings) in high volume centers where it is possible to bring on collaboration across different surgical specialists, such as general, vascular and cardio-vascular surgeons. Further studies are necessary to explore the role of endovascular techniques in SVI.

*Funding:* None.

*Conflict of Interest:* The authors have no conflicts of interest to disclose.

## References

1. Multani A, Parmar S, Dixon E. Laparoscopic vs. robotic gastrectomy in patients with situs inversus totalis: A systematic review. *Minim Invasive Surg.* 2023; 2023:3894561.

2. Eitler K, Bibok A, Telkes G. Situs inversus totalis: A clinical review. *Int J Gen Med.* 2022; 15:2437-2449.
3. Amankwa NA, Adomako EK, Obodai EO, Afriyie-Ansah SP. Situs inversus totalis in a 34-year-old diabetic woman. A case report. *Radiol Case Rep.* 2022; 18:704-708.
4. Bonnelly O, Peña R, Carnicero J. Infrarenal abdominal aortic aneurysm in a patient with situs inversus totalis and its therapeutic implications. *Angiologia* 2022; 74:253-256.
5. Moher D, Liberati A, Tetzlaff J, Altman DG; PRISMA Group. Preferred reporting items for systematic reviews and meta-analyses: the PRISMA statement. *BMJ.* 2009; 339:b2535
6. Téllez-Beltrán D, González-Muñoz A, Barón-Cifuentes V, Pradilla-Gómez JM. Abdominal aortic aneurysm in a patient with situs inversus totalis. *Cir Cir.* 2020; 88(Suppl 1):79-82.
7. Gatta E, Schiavon S, Pagliariccio G, Persechini P, Carbonari L. Pararenal aortic aneurysm in situs inversus totalis: open repair with right retroperitoneal approach. *J Surg Case Rep.* 2020; 2020:rjaa197.
8. Riera Hernández C, Pérez Ramírez P, Esteban Gracia C, Jiménez Olivera MA, Llagostera Pujol S. Situs inversus totalis and abdominal aortic aneurysm: Surgical repair of an extremely uncommon association. *Int J Surg Case Rep.* 2015; 10:216-218.
9. Baccellieri D, Mirenda F, Mandolino T, La Spada M, Stilo F, Spinelli F. Symptomatic aorto-iliac aneurysm and situs viscerum inversus: Case report. *Chir Ital.* 2006; 58:113-116. (in Italian)
10. Occhionorelli S, Navarra G, Santini M, Carcoforo P, Sartori A, Pollinzi V, Mascio F. Symptomatic abdominal aortic aneurysm and "situs viscerum inversus." Diagnostic and therapeutic approach. *J Cardiovasc Surg (Torino).* 1998; 39:31-33.
11. Huston J, Nicholas G. Situs inversus totalis and an infrarenal abdominal aortic aneurysm: Case report. *Vascular and Endovascular Surgery.* 1990; 24:372-374.
12. Cwinn M, Morzycki A, Lee M, Midgley P. Repair of a juxtarenal abdominal aortic aneurysm in a patient with situs inversus totalis using a retroperitoneal approach, *Journal of Vascular Surgery Cases, Innovations and Techniques,* 2016; 2:92-94.
13. Ricci MA, Deshmukh N. Situs inversus and abdominal aortic aneurysm — A case report. *Vascular and Endovascular Surgery.* 1989; 23:413-416.
14. Chan YC, Ting AC, Qing KX, Cheng SW. Successful endovascular infrarenal aneurysm repair in a patient with situs inversus totalis. *Ann Vasc Surg.* 2010; 24:1134.e5-7.
15. Kimura N, Kawahito K, Ito S. Rupture of an abdominal aortic aneurysm in a patient with a situs inversus totalis: Report of a case. *Surg Today.* 2008; 38:249-252.
16. Kato T, Takagi H, Sekino S, Manabe H, Matsuno Y, Umemoto T. Abdominal aortic aneurysm in situs inversus totalis. *Ann Vasc Surg.* 2006; 20:267-270.
17. Jongkind V, Yeung KK, Akkersdijk GJ, Heidsieck D, Reitsma JB, Tangelder GJ, Wisselink W. Juxtarenal aortic aneurysm repair. *J Vasc Surg.* 2010; 52:760-767.
18. Liu Z. Editorial: Abdominal aortic aneurysms: advancements in diagnosis, biomarkers, drug therapeutics, surgical and endovascular treatment. *Front Cardiovasc Med.* 2023; 10:1218335.
19. Silvestri V, Sapienza P, Ossola P, Grande R, Brachini G, Sterpetti AV, Mingoli A. Ruptured superior mesenteric

- artery aneurysm due to fibromuscular dysplasia: A rare vascular presentation in a patient with schizophrenia. *Ann Vasc Surg.* 2019; 58:384.e5-384.e8.
20. Bhama JK, Ogren J, Guinn G, Fisher WE. Unique cause of duodenal obstruction by an abdominal aortic aneurysm. *J Vasc Surg.* 2001; 34:1130-1132.
21. Ossola P, Mascioli F, Coletta D. Laparoscopic and robotic surgery for splenic artery aneurysm: A systematic review. *Ann Vasc Surg.* 2020; 68:527-535.
22. Isselbacher EM, Preventza O, Hamilton Black J 3rd, *et al.* 2022 ACC/AHA Guideline for the Diagnosis and Management of Aortic Disease: A Report of the American Heart Association/American College of Cardiology Joint Committee on Clinical Practice Guidelines. *Circulation.* 2022; 146:e334-e482.
- Received September 16, 2023; Revised November 3, 2023; Accepted December 26, 2023.
- \*Address correspondence to:*  
Paolo Ossola, Department of Surgery, Cardinal Massaia Hospital, Corso Dante Alighieri, 202, 14100 Asti, Italy.  
E-mail: paolo.ossola90@gmail.com
- Released online in J-STAGE as advance publication December 28, 2023.