

ISSN 2186-3644 Online ISSN 2186-361X

IRDR

Intractable & Rare Diseases Research

Volume 5, Number 1
February, 2016



www.irdrjournal.com

IRDR

Intractable & Rare Diseases Research



ISSN: 2186-3644
Online ISSN: 2186-361X
CODEN: IRDRA3
Issues/Year: 4
Language: English
Publisher: IACMHR Co., Ltd.

Intractable & Rare Diseases Research is one of a series of peer-reviewed journals of the International Research and Cooperation Association for Bio & Socio-Sciences Advancement (IRCA-BSSA) Group and is published quarterly by the International Advancement Center for Medicine & Health Research Co., Ltd. (IACMHR Co., Ltd.) and supported by the IRCA-BSSA, Shandong Academy of Medical Sciences, and Shandong Rare Disease Association.


Intractable & Rare Diseases Research devotes to publishing the latest and most significant research in intractable and rare diseases. Articles cover all aspects of intractable and rare diseases research such as molecular biology, genetics, clinical diagnosis, prevention and treatment, epidemiology, health economics, health management, medical care system, and social science in order to encourage cooperation and exchange among scientists and clinical researchers.

Intractable & Rare Diseases Research publishes Original Articles, Brief Reports, Reviews, Policy Forum articles, Case Reports, News, and Letters on all aspects of the field of intractable and rare diseases research. All contributions should seek to promote international collaboration.


IRCA-BSSA Group Journals



ISSN: 1881-7815
Online ISSN: 1881-7823
CODEN: BTIRCZ
Issues/Year: 6
Language: English
Publisher: IACMHR Co., Ltd.
www.biosciencetrends.com



ISSN: 1881-7831
Online ISSN: 1881-784X
CODEN: DDTRBX
Issues/Year: 6
Language: English
Publisher: IACMHR Co., Ltd.
www.ddtjournal.com



ISSN: 2186-3644
Online ISSN: 2186-361X
CODEN: IRDRA3
Issues/Year: 4
Language: English
Publisher: IACMHR Co., Ltd.
www.irdrjournal.com

Intractable & Rare Diseases Research

Editorial and Head Office

Pearl City Koishikawa 603, 2-4-5 Kasuga, Bunkyo-ku,
Tokyo 112-0003, Japan

Tel: +81-3-5840-9968, Fax: +81-3-5840-9969
E-mail: office@irdrjournal.com
URL: www.irdrjournal.com

Editorial Board

Editor-in-Chief:

Masatoshi MAKUUCHI
Japanese Red Cross Medical Center, Tokyo, Japan

Chief Director & Executive Editor:

Wei TANG
The University of Tokyo, Tokyo, Japan

Co-Editors-in-Chief:

Jinxiang HAN
Shandong Academy of Medical Sciences, Jinan, China

Jose-Alain SAHEL
Pierre and Marie Curie University, Paris, France

Editorial Board Members

Tetsuya ASAKAWA <i>(Hamamatsu, Japan)</i>	Si JIN <i>(Wuhan, China)</i>	Shinichi SATO <i>(Tokyo, Japan)</i>	Jiayi ZHOU <i>(Boston, MA, USA)</i>
Karen BRØNDUM-NIELSEN <i>(Glostrup, Denmark)</i>	Yasuhiro KANATANI <i>(Saitama, Japan)</i>	Yasuyuki SETO <i>(Tokyo, Japan)</i>	Wenxia ZHOU <i>(Beijing, China)</i>
Yazhou CUI <i>(Jinan, China)</i>	Mureo KASAHARA <i>(Tokyo, Japan)</i>	Qingfang SUN <i>(Shanghai, China)</i>	Web Editor:
John DART <i>(Crowthorne, UK)</i>	Jun-ichi KIRA <i>(Fukuoka, Japan)</i>	ZhiPeng SUN <i>(Beijing, China)</i>	Yu CHEN <i>(Tokyo, Japan)</i>
Masahito EBINA <i>(Sendai, Japan)</i>	Toshiro KONISHI <i>(Tokyo, Japan)</i>	Samia TEMTAMY <i>(Cairo, Egypt)</i>	Proofreaders:
Clodoveo FERRI <i>(Modena, Italy)</i>	Masato KUSUNOKI <i>(Mie, Japan)</i>	Yisha TONG <i>(Heidelberg, Australia)</i>	Curtis BENTLEY <i>(Roswell, GA, USA)</i>
Toshiyuki FUKAO <i>(Gifu, Japan)</i>	Shixiu LIAO <i>(Zhengzhou, China)</i>	Hisanori UMEHARA <i>(Ishikawa, Japan)</i>	Thomas R. LEBON <i>(Los Angeles, CA, USA)</i>
Ruoyan GAI <i>(Jinan, China)</i>	Zhibin LIN <i>(Beijing, China)</i>	Chenglin WANG <i>(Shenzhen, China)</i>	Office Staff:
Shiwei GONG <i>(Wuhan, China)</i>	Reymundo LOZANO <i>(New York, NY, USA)</i>	Haibo WANG <i>(Hong Kong, China)</i>	Apolline SONG <i>(Tokyo, Japan)</i>
Jeff GUO <i>(Cincinnati, OH, USA)</i>	Kuansheng MA <i>(Chongqing, China)</i>	Huijun WANG <i>(Shanghai, China)</i>	Editorial and Head Office:
Toshiro HARA <i>(Fukuoka, Japan)</i>	Katia MARAZOVA <i>(Paris, France)</i>	Qinghe XING <i>(Shanghai, China)</i>	Pearl City Koishikawa 603
Lihui HUANG <i>(Beijing, China)</i>	Chikao MORIMOTO <i>(Tokyo, Japan)</i>	Zhenggang XIONG <i>(New Orleans, LA, USA)</i>	2-4-5 Kasuga, Bunkyo-ku
Reiko HORIKAWA <i>(Tokyo, Japan)</i>	Noboru MOTOMURA <i>(Tokyo, Japan)</i>	Toshiyuki YAMAMOTO <i>(Tokyo, Japan)</i>	Tokyo 112-0003, Japan
Takahiko HORIUCHI <i>(Fukuoka, Japan)</i>	Masanori NAKAGAWA <i>(Kyoto, Japan)</i>	Huijun YUAN <i>(Beijing, China)</i>	Tel: +81-3-5840-9968
Yoshinori INAGAKI <i>(Tokyo, Japan)</i>	Jun NAKAJIMA <i>(Tokyo, Japan)</i>	Wenhong ZHANG <i>(Shanghai, China)</i>	Fax: +81-3-5840-9969
Masaru IWASAKI <i>(Yamanashi, Japan)</i>	Takashi NAKAJIMA <i>(Kashiwazaki, Japan)</i>	Xianqin ZHANG <i>(Wuhan, China)</i>	E-mail: office@irdrjournal.com
Baoan JI <i>(Houston, TX, USA)</i>	Ming QIU <i>(Shanghai, China)</i>	YanJun ZHANG <i>(Cincinnati, OH, USA)</i>	<i>(As of January 2016)</i>
Xunming JI <i>(Beijing, China)</i>	Phillips ROBBINS <i>(Boston, MA, USA)</i>	Yumin ZHANG <i>(Bethesda, MD, USA)</i>	
Guosheng JIANG <i>(Jinan, China)</i>	Hironobu SASANO <i>(Sendai, Japan)</i>	Yuesi ZHONG <i>(Guangzhou, China)</i>	

Reviews

- 1 - 5 **Rosai-Dorfman disease and the heart.**
Kevin O'Gallagher, Luke Dancy, Aish Sinha, Daniel Sado
- 6 - 16 **The progress of angiogenic factors in the development of leukemias.**
Yang Han, Xidi Wang, Bingping Wang, Guosheng Jiang

Original Articles

- 17 - 24 **Insulin-driven translational capacity is impaired in primary fibroblasts of Prader Willi.**
Cristiana Meneghello, Daniela Segat, Elisabetta Fortunati
- 25 - 30 **Importance of glucokinase -258G/A polymorphism in Asian Indians with post-transplant and type 2 diabetes mellitus.**
Imran Ali Khan, Kiran Kumar Vattam, Parveen Jahan, Qurratulain Hasan, Pragna Rao
- 31 - 35 **Using inpatient data to estimate the prevalence of Wegener's granulomatosis in China.**
Xiao Liu, Yazhou Cui, Yan Li, Chao Wang, Heng Zhao, Jinxiang Han

Case Reports

- 36 - 41 **Castleman's disease of a submandibular mass diagnosed on Fine Needle Cytology: Report of a case with histopathological, immunocytochemical and imaging correlations.**
Maria Gabriella Malzone, Anna Cipolletta Campanile, Veronica Sanna, Franco Ionna, Francesco Longo, Annarosaria De Chiara, Sergio Venanzio Setola, Gerardo Botti, Franco Fulciniti
- 42 - 43 **Peutz-Jeghers syndrome: Four cases in one family.**
Ran Wang, Xingshun Qi, Xu Liu, Xiaozhong Guo
- 44 - 46 **A rare case of giant vaginal fibromyoma.**
Mona Asnani, Kumkum Srivastava, Hem Prabha Gupta, Shipra Kunwar, A N Srivastava

CONTENTS

(Continued)

- 47 - 49 **Spontaneous rectus sheath hematoma in a patient treated with apixaban.**
Halil Aktas, Sinan Inci, Pinar Dogan, Ibrahim Izgu
- 50 - 55 **Coexistence of tinnitus and hyperacusis in individuals with auditory dyssynchrony:
A single case study.**
K. N. Megha, Sugathan Adithya, K. P. Keerthana, Sreeraj Konadath
- 56 - 57 **Contact dermatitis after implantable cardiac defibrillator implantation for
ventricular tachycardia.**
Pinar Dogan, Sinan Inci, Mevlut Serdar Kuyumcu, Ozgur Kus
- 58 - 60 **A large spontaneous intrahepatic portosystemic shunt in a cirrhotic patient.**
Xingshun Qi, Chun Ye, Yue Hou, Xiaozhong Guo

Guide for Authors

Copyright

(This journal was partially supported by a Grant-in-Aid for Scientific Research from Japan Society for the Promotion of Science.)

Rosai-Dorfman disease and the heart

Kevin O'Gallagher*, Luke Dancy, Aish Sinha, Daniel Sado

Cardiology Department, King's College Hospital NHS Foundation Trust, London, UK.

Summary Rosai-Dorfman disease (RDD) is a non-malignant pathology of histiocyte proliferation. The classical clinical presentation is with painless cervical lymphadenopathy, but extranodal involvement is frequent, occurring in approximately 40% of cases. The literature was systematically reviewed to identify reported cases of RDD with cardiac involvement. Eighteen cases were identified (3 pediatric and 15 adult). In adult cardiac RDD (cRDD), three patterns of disease were noted: an intra-cardiac mass, epicardial involvement, and pulmonary artery involvement. Reported cases suggest that surgical excision of intra-cardiac masses confers a good prognosis.

Keywords: Histiocytosis, non-Langerhans, cardiac

1. Introduction

First described in 1965 (1) and subsequently characterized in 1969 (2), Rosai-Dorfman disease (RDD) is a non-malignant disease of histiocyte proliferation. Although the classical clinical presentation is with painless cervical lymphadenopathy (hence the alternative term "sinus histiocytosis with massive histiocytosis", or SHML), extranodal involvement is frequent, occurring in approximately 40% of cases. Common sites of extranodal involvement include the skin, nasal cavities, and paranasal sinuses. Cardiac involvement (cRDD) has previously been documented as occurring in < 0.1% of cases (3).

The etiology of RDD is as yet poorly defined and is, in the absence of convincing evidence to the contrary, currently considered to be idiopathic. A viral cause has been postulated, either *via* direct infection or as a result of an exaggerated immune response to the viral agent. Human herpes virus 6 (HHV6) DNA has been detected in RDD histiocytes (4), but in other cases HBV6 has not been detected (5). Epstein-Barr virus (EBV) infection has been identified in approximately half of patients

with RDD (6), but no evidence of EBV RNA has been found in isolated RDD histiocytes or lymphocytes (7). Parvovirus B19 has been found in RDD lymphocytes (but not histiocytes) (8). A genetic form of RDD – Faisalabad histiocytosis, mapped to a mutation in the *SLC29A3* gene on chromosome 10q22.1 (9) – has been identified but is isolated to 3 consanguineous families.

Definitive diagnosis is by histological assessment, the two cornerstones of which are identification of emperipolesis and appropriate immunohistochemical analysis. Emperipolesis in relation to RDD refers to the presence of histiocytes containing intact lymphocytes within their cytoplasm. Emperipolesis is differentiated from phagocytosis due to the intact nature of the engulfed cell, which by definition is viable and can exit the engulfing cell without any structural or functional abnormality (10). In addition to RDD, emperipolesis is also seen in malignant disease processes, such as lymphoma, leukaemia, myelodysplasia, and myeloma. Immunohistochemical staining for S100 protein is considered diagnostic. Cells will also be positive for CD68 and negative for CD1a, helping to distinguish RDD histiocytes from Langerhans cells (11).

Management of RDD is greatly dependent on the extent and site of disease and also on the presence or absence of symptoms (12). Surgical resection is appropriate for localized disease, with radiation therapy an option for residual disease after resection. In systemic/extensive extranodal disease, first line therapy is corticosteroids. Other options include immunomodulators, and/or cytotoxic chemotherapeutic agents. Due to the infrequency of reported cases of

Released online in J-STAGE as advance publication February 1, 2016.

*Address correspondence to:

Dr. Kevin O'Gallagher, Cardiology Department, King's College Hospital NHS Foundation Trust, Denmark Hill, London, UK.

E-mail: k.o'gallagher@nhs.net

cRDD, no current treatment algorithm has been defined. In general, RDD is considered a benign process, but extensive lymph node or cutaneous involvement can lead to disfigurement, and deaths have also been noted (13) (mortality 7% (14)). RDD tends not to have an adverse prognosis unless the disease has a profound effect on vital organs or is extensive/disseminated.

2. Literature review

The literature was systematically reviewed (in line with PRISMA guidance) to identify cases of RDD involving the heart and/or great vessels. A search was carried out *via* PubMed using the terms "Rosai Dorfman" and "sinus histiocytosis" combined with "heart" and "cardiac". Only English language publications were considered. Nine hundred and forty-three results were obtained. Those results yielded 17 papers describing 18 individual cases of cRDD (Table 1). Of the 18 individual cases, 3 were pediatric cases (< 16 years of age) while 15 were adult (≥ 16 years of age).

Two of the identified papers cited an additional reported case of cRDD (15). It was, however, impossible to obtain the full text of that report, so it has been excluded from the current analysis. A further case report was also cited (16), but it has been excluded as it was not written in English.

3. Pediatric cRDD

Of the 3 cases of pediatric cardiac involvement in RDD, 2 had very similar presentations: young male patients with sickle cell disease, presenting with chest pain and fever. Both of these patients had a mass in the interatrial septum (IAS) with infiltration of other cardiac structures. Both patients also presented with conduction disease requiring permanent pacing. Despite the similar presentations, the subsequent course was strikingly different. Patient 1 suffered from a progressive deterioration and required a cardiac transplant, while patient 2 had an indolent course. Both patients survived. The other case of pediatric cRDD involved a 14-year-old Afro-Caribbean boy with tricuspid and pulmonary valve involvement who underwent multiple surgical interventions but who ultimately died from disease progression.

4. Adult cRDD

The 15 adult cases involved 10 males and 5 females ranging in age from 22-79 years (mean 49.5 years). Ethnic origin was reported for only 3 patients, making comment impossible. Three patterns were identified for the primary reported site of cardiac involvement: an intra-cardiac mass with or without underlying infiltration, pericardial/epicardial involvement, and a pulmonary arterial mass (Figure 1). Of the 15 adult

Table 1. Reported cases of cardiac involvement in Rosai-Dorfman disease

Patient/Ref.	Age /Sex	Ethnic Origin	Symptoms at presentation	Type of cardiac involvement	Main site	Other sites	Extra-cardiac RDD	Treatment	Other pmh	Diagnostic Tool	Outcome**
1 ^P / (17)	12/M	A-C*	Chest pain, fever	Intra-cardiac infiltration and mass, complete heart block	IAS	RA mass, LV, aortic root	None	CRT, cardiac transplant	Sickle cell	Needle biopsy, explant biopsy	Alive 18 months post-transplant
2 ^P / (18)	12/M	U/c	Chest pain, fever	Intra-cardiac infiltration and mass, complete heart block	IAS	RA, LA, AV groove, aortic root+arch	LLL bronchus, oesophagus, posterior mediastinum, renal	Pacemaker, conservative treatment	Sickle cell	Needle biopsy, PET-CT	Alive
3 ^P / (19)	14/M	A-C*			Tricuspid, pulmonary valve			Multiple surgical procedures and radiation therapy		CT, cMR, PET-CT, CT-guided biopsy, excision biopsy	Death from disease progression, autopsy
4 ^A / (20)	27/M	A-C*	Palpitations	Intra-cardiac mass	LA	None	Mediastinal lymphadenopathy	Excision of mass			Alive
5 ^A / (21)	55/M	u/c	Atypical chest pain	Intra-cardiac mass	LA	LV, ascending aorta, SVC	Lungs, femur	No specific treatment	Concurrent necrotizing pneumonia	CT guided lung biopsy, VATS biopsy, surgical cardiac biopsy,	Stable

^P, Pediatric; ^A, Adult; A-C*, Afro-Caribbean; Outcome**, at discharge unless otherwise stated.

Table 1. Reported cases of cardiac involvement in Rosai-Dorfman disease (continued)

Patient/Ref	Age /Sex	Ethnic Origin	Symptoms at presentation	Type of cardiac involvement	Main site	Other sites	Extra-cardiac RDD	Treatment	Other pmh	Diagnostic Tool	Outcome**
6 ^A / (22)	69/M	u/c	Incidental findings	Pericardial mass	Pericardium, epicardial LV surface with infiltration of myocardium	None	None	Surgical excision	Bronchitis, hypertension, gout	CT, PET-CT	Alive
7 ^A / (23)	62/M	u/c	Atypical chest pain, SOB	Intra-cardiac mass	RA	Invasion of IAS and RV	None	Surgical excision (incomplete)	None	Echo, CT, cMR, excision biopsy	Alive
8 ^A / (24)	40/M	A-C*	Edema, night sweats, weight loss, ARDS	Intra-cardiac mass	RA	None	None	N/a	CMML	Post-mortem diagnosis	Death (from other causes)
9 ^A / (24)	57/F	Caucasian	Atypical chest pain	Intra-cardiac mass	RA	None	Mediastinal lymphadenopathy	Conservative, corticosteroids,	None	MRI	Alive
10 ^A / (25)	60/M	u/c	SOB, fatigue	Intra-cardiac mass	RA	Invasion of RA wall	None	Surgical excision	Bilateral RAS, meningioma	Echo, CT, excision biopsy	No change in size of mass after 2 years
11 ^A / (26)	61/M	u/c	Chest pain, SOB, atrial flutter, hypotension	Intra-cardiac mass	RA	Invasion of RA wall	None	Surgical excision	Retropertoneal fibrosis, bilateral hydronephrosis, meningioma, hypertension, hypercholesterolaemia	Excision biopsy	Alive
12 ^A / (27)	29/M	u/c	Palpitations	Intra-cardiac mass	LV	Invasion of LV	None	Intra-operative biopsy with subsequent excision	Cocaine use	Echo, CT, cMR	Alive
13 ^A / (28)	51/F	u/c	Chest pain, SOB, edema, recurrent pericardial effusion	Recurrent pericardial effusion, Epicardial infiltration	Epicardium	None	Pleura, lungs, mediastinum, colon	Corticosteroids, repeated pericardial drainage	None	Post-mortem	Dead
14 ^A / (29)	51/F	u/c	Chest pain, SOB, edema	Recurrent pericardial effusion	Pericardium	None	Lungs, mesentery	Repeated drainage	None	Post-mortem	Dead
15 ^A / (30)	62/M		Dry cough	PA	PA	None	None	Surgical pulmonary endarterectomy	Neuroendocrine tumour	PET-CT, endovascular biopsy	Alive
16 ^A / (31)	61/F	u/c	Syncope	PA mass	PA	None	None	N/a	None	Needle biopsy, post-mortem diagnosis	Died during biopsy
17 ^A / (32)	22/F	u/c	SOB, edema	Bilateral PA masses, right heart failure	L+R PA	Aorta, RA	Skin, mesentery	Surgical debulking	None	CT, PET-CT, excision biopsy	Alive
18 ^A / (33)	36/M	U/c	SOB	Main pulmonary artery, RVOT and pericardium	Main pulmonary artery	RVOT and pericardium	None	Surgical resection plus low-dose corticosteroids	None	TTE cardiac MRI, RV biopsy	Alive

^P ; Pediatric; ^A , Adult; A-C* , Afro-Caribbean; Outcome** , at discharge unless otherwise stated.

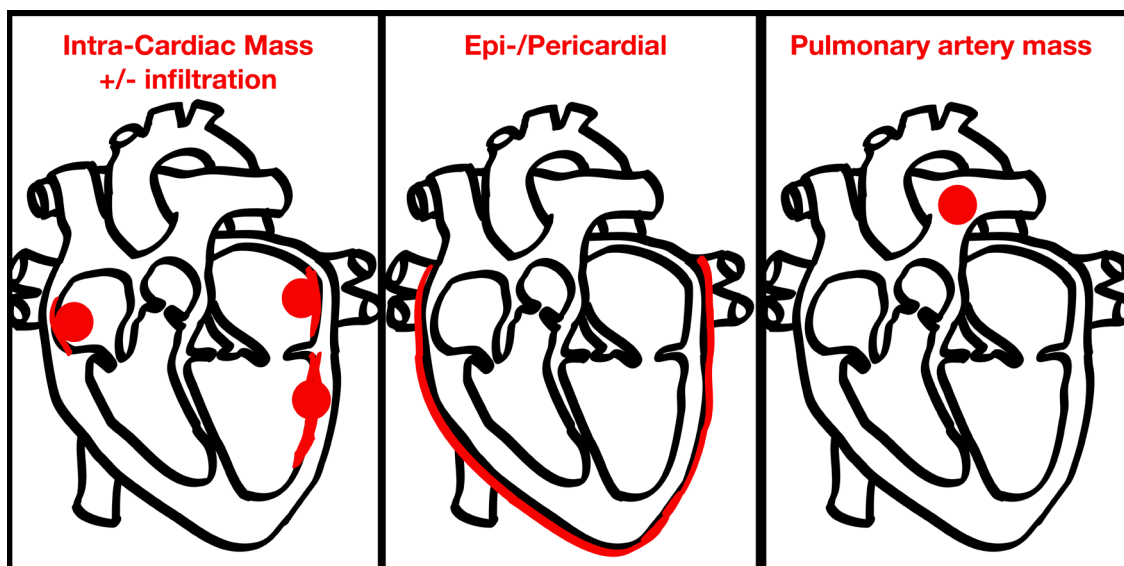


Figure 1. Patterns of cardiac involvement in adults with Rosai-Dorfman disease.

patients, 4 had pericardial/epicardial involvement, 4 had involvement of the pulmonary artery, and 9 had an intra-cardiac mass. Of those cases involving intra-cardiac masses, 2 had a mass in the left atrium (LA), 5 had a mass in the right atrium (RA), 1 had a mass in the left ventricle (LV), and 1 had a mass in the right ventricular outflow tract (RVOT). Seven cases presented with multi-focal cardiac involvement, *i.e.* invasion/extension beyond the reported primary cardiac involvement.

5. Management of and outcomes for patients with cRDD

Of the 15 adult patients, 3 received corticosteroid treatment. This resulted in stabilization of disease in 2 patients. The other patient who received corticosteroids died of multi-organ failure related to cRDD. Affected tissue/the mass was excised in 7 patients with good results. Of the 4 patients with PA involvement, three had a lesion that was successfully treated. The other patient died during an invasive examination.

Five deaths in the cohort (18) were reported (1 pediatric patient and 4 adults). Of the deaths, 3 were related to the cRDD itself. One patient died of other causes while 1 patient died during an invasive biopsy procedure.

6. Discussion

Cardiac involvement in RDD is a rare manifestation of a rare disease, occurring in 0.1-0.2% of cases. The most common mode of presentation appears to be with an intracardiac mass, which in the majority of cases represents multi-focal underlying cardiac involvement. This literature review suggests that successful surgical excision of affected tissue carries a good prognosis.

This literature review has two main limitations. First, it relies on case reports, so there is very limited information on the subsequent follow-up of the patients involved. Thus, no comment can be made on the long-term clinical course, or indeed the frequency of disease recurrence in patients. Second, the condition is rare, so there are likely to be cases that have yet to be diagnosed, either due to unfamiliarity with the disease or due to lack of access to appropriate examinations.

References

1. Destombes P. Adenitis with lipid excess, in children or young adults, seen in the Antilles and in Mali (4 cases). *Bull Soc Pathol Exot Filiales*. 1965; 58:1035-1039. (in French)
2. Rosai J, Dorfman RF. Sinus histiocytosis with massive lymphadenopathy. A newly recognized benign clinicopathological entity. *Arch Pathol*. 1969; 87:63-70.
3. Gaitonde S. Multifocal, extranodal sinus histiocytosis with massive lymphadenopathy: An overview. *Arch Pathol Lab Med*. 2007; 131:1117-1121.
4. Levine PH, Jahan N, Murari P, Manak M, Jaffe ES. Detection of human herpesvirus 6 in tissue involved by sinus histiocytosis with massive lymphadenopathy (Rosai-Dorfman disease). *J Infect Dis*. 1992; 166:291-295.
5. Ortonne N, Fillet AM, Kosuge H, Bagot M, Frances C, Wechsler J. Cutaneous Destombes-Rosai-Dorfman disease: Absence of detection of HHV-6 and HHV-8 in skin. *J Cutan Pathol*. 2002; 29:113-118.
6. Foucar E, Rosai J, Dorfman R. Sinus histiocytosis with massive lymphadenopathy (Rosai-Dorfman disease): Review of the entity. *Semin Diagn Pathol*. 1990; 7:19-73.
7. Tsang WY, Yip TT, Chan JK. The Rosai-Dorfman disease histiocytes are not infected by Epstein-Barr virus. *Histopathology*. 1994; 25:88-90.
8. Mehraein Y, Wagner M, Remberger K, Füzési L, Middel P, Kaptur S, Schmitt K, Meese E. Parvovirus B19 detected in Rosai-Dorfman disease in nodal and extranodal manifestations. *J Clin Pathol*. 2006; 59:1320-1326.

9. Morgan NV, Morris MR, Cangul H, *et al.* Mutations in *SLC29A3*, encoding an equilibrative nucleoside transporter ENT3, cause a familial histiocytosis syndrome (Faisalabad histiocytosis) and familial Rosai-Dorfman disease. *PLoS Genet.* 2010; 6:e1000833.
10. Humble JG, Jaynee WHM, Pulvertaft RJ. Biological interaction between lymphocyte and other cells. *Br J Hematol.* 1956; 2:283.
11. Rastogi V, Sharma R, Misra SR, Yadav L, Sharma V. Emperipolesis - A review. *J Clin Diagn Res.* 2014; 8:ZM01-2.
12. Dalia S, Sagatys E, Sokol L, Kubal T. Rosai-Dorfman disease: Tumor biology, clinical features, pathology, and treatment. *Cancer Control.* 2014; 21:322-327.
13. Foucar E, Rosai J, Dorfman RF. Sinus histiocytosis with massive lymphadenopathy. An analysis of 14 deaths occurring in a patient registry. *Cancer.* 1984; 54:1834-1840.
14. Liu L, Perry AM, Cao W, Smith LM, Hsi ED, Liu X, Mo JQ, Dotlic S, Mosunjac M, Talmon G, Weisenburger DD, Fu K. Relationship between Rosai-Dorfman disease and IgG4-related disease: Study of 32 cases. *Am J Clin Pathol.* 2013; 140:395-402.
15. Halabe-Cherem J, Cuan-Perez M, Wacher N. A case of sinusoidal histiocytosis with possible invasion of the heart. *Rev Med Inst Mex Seguro Soc.* 1988; 26:295-298.
16. Scheffel H, Vogt P, Alkadhi H. Cardiac manifestations of Rosai-Dorfman disease. *Herz.* 2006; 31:715-716. (in German)
17. Schaffer LR, Caltharp SA, Milla SS, Kogon BF, Cundiff CA, Dalal A, Quigley PC, Shehata BM. Rare presentation of four primary pediatric cardiac tumors. *Cardiovasc Pathol.* 2016; 25:72-77.
18. Yontz L, Franco A, Sharma S, Lewis K, McDonough C. A case of Rosai-Dorfman disease in a pediatric patient with cardiac involvement. *J Radiol Case Rep.* 2012; 6:1-8.
19. Buchino JJ, Byrd RP, Kmetz DR. Disseminated sinus histiocytosis with massive lymphadenopathy: Its pathologic aspects. *Arch Pathol Lab Med.* 1982; 106:13-16.
20. Daruwalla VJ, Parekh K, Tahir H, Collins JD, Carr J. Extranodal Rosai-Dorfman disease involving the left atrium: Cardiac MRI, CT, and PET scan findings. *Case Rep Radiol.* 2015; 2015:753160.
21. Richter JT, Strange RG Jr, Fisher SI, Miller DV, Delvecchio DM. Extranodal Rosai-Dorfman disease presenting as a cardiac mass in an adult: Report of a unique case and lack of relationship to IgG4-related sclerosing lesions. *Human Pathol.* 2010; 41:297-301.
22. Lao IW, Dong Y, Wang J. Rosai-Dorfman disease of the pericardium: A case report and review of literature. *Int J Clin Exp Pathol.* 2014; 7:3408-3412.
23. Özbudak E, Arıkan AA, Yavuz S, Halıcı U, Berki T. A very rarely seen cardiac mass (Rosai-Dorfman disease). *Anadolu Kardiyol Derg.* 2014; 14:475-483.
24. Maleszewski JJ, Hristov AC, Halushka MK, Miller DV. Extranodal Rosai-Dorfman disease involving the heart: Report of two cases. *Cardiovasc Pathol.* 2010; 19:380-384.
25. Bi Y, Huo Z, Meng Y, Wu H, Yan J, Zhou Y, Liu X, Song L, Lu Z. Extranodal Rosai-Dorfman disease involving the right atrium in a 60-year-old male. *Diagn Pathol.* 2014; 9:115.
26. Ajise OE, Stahl-Herz J, Goozner B, Cassai N, McRae G, Wiczorek R. Extranodal Rosai-Dorfman disease arising in the right atrium: A case report with literature review. *Int J Surg Pathol.* 2011; 19:637-642.
27. Sarraj A, Zarra KV, Jimenez Borreguero LJ, Caballero P, Nuche JM. Isolated cardiac involvement of Rosai-Dorfman disease. *Ann Thorac Surg.* 2012; 94:2118-2120.
28. Chen J, Tang H, Li B, Xiu Q. Rosai-Dorfman disease of multiple organs, including the epicardium: An unusual case with poor prognosis. *Heart Lung.* 2011; 40:168-171.
29. Da Xu J, Cao XX, Liu XP, Li QQ, Wang WJ, De Xu Z. Hydropericardium prevented diagnosis of constrictive pericarditis: An unusual case of Rosai-Dorfman disease. *BMJ Case Rep.* 2009; pii: bcr03.2009.1688.
30. Morsolini M, Nicola M, Paulli M, D'Armini AM. Primary pulmonary artery Rosai-Dorfman disease mimicking sarcoma. *J Thorac Cardiovasc Surg.* 2013; 146:e57-e59.
31. Rehman T, deBoisblanc BP, Kantrow SP. Extranodal Rosai-Dorfman disease involving the pulmonary artery. *Eur J Cardiothorac Surg.* 2013; 44:964.
32. Walters DM, Dunnington GH, Dustin SM, Frierson HF, Peeler BB, Kozower BD, Ailawadi G, Jones DR, Lau CL. Rosai-Dorfman disease presenting as a pulmonary artery mass. *Ann Thorac Surg.* 2010; 89:300-302.
33. Chaitanya V, Gupta N. Isolated cardiac involvement of extranodal Rosai-Dorfman disease: An atypical presentation. *J Cardiol Curr Res.* 2015; 3:99.

(Received December 19, 2015; Revised January 7, 2016; Accepted January 17, 2015)

The progress of angiogenic factors in the development of leukemias

Yang Han^{1,2}, Xidi Wang³, Bingping Wang⁴, Guosheng Jiang^{1,*}

¹Key Laboratory for Rare & Uncommon Diseases of Shandong Province, Institute of Basic Medicine, Shandong Academy of Medical Sciences, Ji'nan, Shandong, China;

²School of Medicine and Life Sciences, Ji'nan University, Ji'nan, Shandong, China;

³Laboratory Department, People's Hospital of Zhangqiu City, Zhangqiu, Shandong, China;

⁴Department of Hematology, Shengli Oilfield Central Hospital, Dongying, China.

Summary

Angiogenic factors have been demonstrated to play important roles in modulating angiogenesis of solid tumors. Recently, accumulating studies extensively indicated that some angiogenic factors widely exist in malignant cells of hematologic malignancy, which regulated the expression of a number of genes that were involved in abnormal proliferation, differentiation and apoptosis of these cells. With deep research of angiogenic factors, its expression, function and regulatory mechanism were gradually elucidated, and some of them were related to the development and prognosis of leukemia, or provide more possible strategies for treatment of patients with leukemia. Herein, we summarize the progress in study of some important angiogenic factors and hematological malignancies.

Keywords: Angiogenesis, angiogenic factors, leukemia

1. Introduction

Angiogenesis, new blood vessel formation, is fundamental to tumor progression and metastasis, which has been documented for solid tumors. In addition, it is also proved that the induction of new blood vessel formation is a dependent factor of hematological malignancies (1). For example, it was first reported by Perez-Atayde *et al.* in 1997 that the angiogenesis phenomenon existed in the bone marrow of childhood acute lymphoblastic leukemia (ALL) (2). Much subsequent research also discovered that a number of hematological malignancies were accompanied with angiogenesis which was related to the prognosis of childhood ALL or made a contribution to the development and progression of chronic lymphocytic leukemia (CLL) (3,4). Usually, angiogenesis is regulated by a balance of angiogenic and antiangiogenic cytokines, and

angiogenesis can be induced by leukemia cells in the bone marrow, and leukemia may be more likely to be angiogenesis dependent, which raises the probability for antiangiogenic drugs in the treatment of leukemia. For example, some evidence indicated that several antiangiogenic drugs, such as targeting vascular endothelial growth factor (VEGF) or its receptors, are able to treat patients with cancer (5). Moreover inhibition of VEGF only is not as effective as first believed. Therefore, it is necessary to develop more effective targets for treatment of patients with leukemia (6). A lot of angiogenesis-inducing factors so far have been discovered, such as VEGF, fibroblast growth factor (FGF), angiogenin (Ang), hypoxia-inducible factor 1 (HIF-1), matrix metalloproteinase (MMP), *c-myc* gene, endothelin (ET), transforming growth factor (TGF), tumor necrosis factor (TNF), interleukin (IL), integrin, hepatocyte growth factor (HGF), placenta growth factor (PIGF) and so on. By way of combination with their ligand-receptors, these growth factors can promote the division of vascular endothelial cells and induce formation of new vessels, which will provide favorable conditions for the occurrence and progression of the tumors. In addition to the above-mentioned relationship between angiogenic factors and angiogenesis in patients with leukemia, their roles in modulating proliferation, differentiation and apoptosis were also gradually elucidated. This review will briefly

Released online in J-STAGE as advance publication February 1, 2016.

*Address correspondence to:

Dr. Guosheng Jiang, Key Laboratory for Rare & Uncommon Diseases of Shandong Province, Institute of Basic Medicine, Shandong Academy of Medical Sciences, NO.18877 of Jingshi Road, Ji'nan, Shandong, China.

E-mail: jiangguosh@163.com

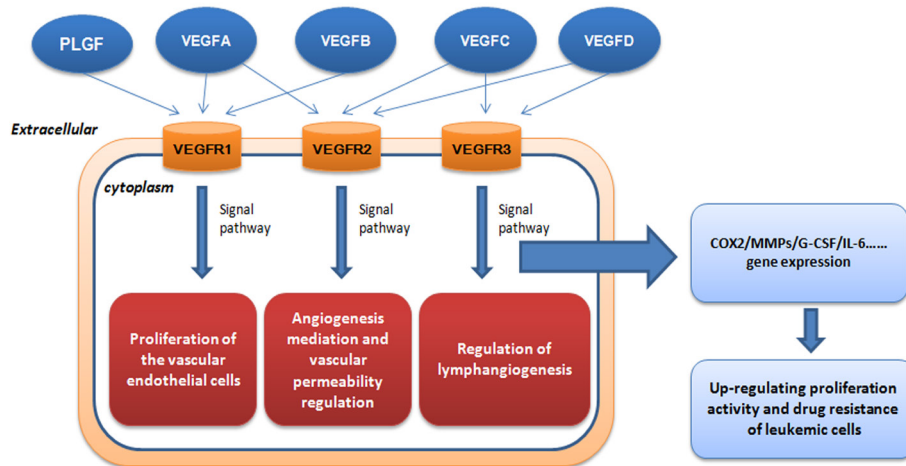


Figure 1. The role of VEGF in leukemia progression. VEGF can act on vascular endothelial cells with high efficiency and specificity to promote endangium regeneration and increase vascular permeability *via* three tyrosine kinase receptors (TKR).

introduce roles of some of these angiogenic factors in development of leukemias.

2. The role of VEGF involved in leukemia

More than 40 molecules that play an important role in blood vessel recruitment have been identified, especially the roles of VEGF and its receptors (3). VEGF has at least six isoforms (VEGF-A, VEGF-B, VEGF-C, VEGF-D, VEGF-E and PIGF) and all the isoforms are secreted as dimeric glycoproteins (7). First of all, VEGF becomes the most well characterized proangiogenic factor, and it was first purified from the *in vitro* culture medium of bovine pituitary folliculo-stellate cells by Ferrara *et al* (8). Named after its mitogenic activity for vascular endothelial cells, VEGF is thought to be the highly specific co-mitogen for vascular endothelial cells and promoting factor of vascular permeability (9). As is shown in Figure 1, VEGF can act on vascular endothelial cells with high efficiency and specificity promote endangium regeneration and increase vascular permeability *via* three tyrosine kinase receptors (TKR): VEGFR-1 (also known as Flt-1), VEGFR-2 (also known as KDR/Flk-1) and VEGFR-3 (also known as Flt4) (10). It has been discovered that VEGF-2 plays a major role in VEGF-induced angiogenesis, and the binding between VEGF and receptor Flk-1 can activate the mitogen-activated protein kinase (MAPK) system *via* protein kinase C (PKC) or Ras protein to induce proliferation of vascular endothelial cells (11). It has been proved so far that VEGF is the only specific growth factor for angiogenesis, while other growth factors such as FGF and PDGF can act on various kinds of cells in addition to vascular endothelial cells with low specificity (12). VEGF can regulate development of hemopoietic stem cells, remodeling of extracellular matrix and regeneration of inflammatory cytokines. Furthermore, it seems that activation of VEGFR-2

plays a necessary and sufficient role mediating VEGF-dependent angiogenesis and induction of vascular permeability. In addition, VEGFR-1 and VEGFR-2 were predominantly expressed on vascular endothelial cells (13), and VEGFR-1 was expressed on other diverse cells, including hematopoietic stem cells (HSCs), vascular smooth muscle cells, monocytes and leukemia cells (14). However, VEGFR-2 is chiefly expressed on endothelial progenitor cells and megakaryocytes (15). Regulation of lymphangiogenesis was mainly dependent on binding of VEGF homologs VEGF-C, VEGF-D and VEGFR-3, which is largely restricted to lymphatic endothelial cells (6). In addition, expression of VEGF-D was found to be strongly expressed both in non-HL (NHL) and HL by HRS cells in line with a high number of tumor microvessels, suggesting a role for this cytokine in angiogenesis (16).

The induction of tumor angiogenesis by an angiogenic switch has become a characteristic of cancer (17). As the angiogenesis switch of tumors, VEGF can markedly increase vascular permeability. Many leukemic cell strains and primary cells can synthesize and secrete VEGF (18), which can modulate the malignant biological behavior of leukemic cells by two positive-feedback loops: paracrine and autocrine. VEGF secreted by leukemic cells interacts with the relevant receptors on the endothelial cell surface, and the endothelial cells produce growth factors such as G-CSF that acts on the leukemic cells in return to increase their proliferation activity and drug resistance, or directly acts on relevant receptors on the autologous cell surface to increase autologous proliferation activity and drug resistance (19). The functional interaction between VEGF-A and formyl peptide receptor-like 1 (FPRL1) mediated by secretion of connective tissue growth factor (CTGF) was demonstrated by some scientists (20). CTGF activates the downstream signals of FPRL1 by binding to FPRL1 directly, such as increase in

intracellular Ca^{2+} concentration and extracellular signal-regulated kinase (ERK) phosphorylation. In recent studies, VEGF is thought to be closely related to MMPs (21), which showed the complexity of VEGF-mediated regulation of MMP-9 expression. In the other reports, it is demonstrated that repeated social defeat stress (RSDS) made a contribution to cancer angiogenesis and metastasis, which was partially associated with increased secretion of VEGF (22). The combination has the possibility to be used in clinical trials if it can be considered as a possible therapeutic option when conducting suitable further investigations.

Emerging evidence suggests that it is also involved in proliferation, abnormal differentiation, prognosis and treatment of acute myeloid leukemia (AML) (23,24). The upregulation of bone marrow microvessel density and the levels of plasma pro-angiogenic cytokines also support this above-mentioned theory (6). Simultaneously, the representative cytokines, VEGFs and their receptors are expressed on AML blasts in vascular and osteoblast niches in both the BM and the peripheral circulation (25). In the present review, we just focus on the discussion of VEGF as a therapy target for leukemia. Interestingly, as an anti-angiogenic therapeutic approach, it is becoming more and more effective and promising by using immunomodulatory drugs, for example, anti-VEGF monoclonal antibodies, VEGFR inhibitor and Histone deacetylase inhibitors (26,27).

Hence, anti-angiogenesis therapy based on the principle of inhibiting the physiological function of VEGF has become the hotspot of oncotherapies. For example, Ilorasertib (ABT-348) is a novel inhibitor of aurora kinase, and could inhibit biomarkers for aurora kinase and VEGF receptors (28). Heparan sulfate D-glucosaminyl 3-O-sulfotransferase-3B1 (HS3ST3B1) can promote angiogenesis and proliferation by induction of VEGF in AML cells. It was positively contributed to AML progression, and these activities were associated with an induction of proangiogenic factor VEGF expression and shedding (29). Ginsenoside Rg3 has been not only used in anti-angiogenic therapy of solid tumors, but also exhibits an anti-leukemia effect in part due to its anti-angiogenic activity *via* inhibiting PI3K/Akt and ERK1/2 pathways, which act to regulate expression of HIF-1 α and VEGF (30). Histone deacetylase (HDAC) inhibitors have been reported to inhibit tumor angiogenesis *via* downregulation of angiogenic factors (31). The mechanism underlying VPA induced antiangiogenesis is associated with suppression of VEGF and its receptors (31). Furthermore, the combined use of histone deacetylase inhibitor VPA, all-trans retinoic acid (ATRA), and deoxyribonucleic acid polymerase- α inhibitor cytarabine (Ara-C) is now considered for disease-stabilizing treatment of AML, which was related to antiproliferative effects, and modulation of release of angiogenic mediator of endothelial

cells respectively (32). Foretinib is a multiple kinase inhibitor undergoing clinical trials and it could suppress activity of VEGFR-2 (33). It could be able to inhibit VEGF-A, VEGF-C and Angiopoetin-2 stimulated tube formation by reducing VEGFR-2, VEGFR-3 and TIE-2 activation (34). However, although VEGF receptor inhibition is one potential mechanism by which AML could be treated, the receptor tyrosine kinase inhibitor AZD2171, against VEGF receptors KDR and FLT-1, could not get confirmed responses in other groups (35). Understanding the intricate cellular components of the bone marrow microenvironment can lead to discovery of novel extrinsic factors that are responsible for initiation and progression of leukemic disease. Activation of endothelial cells (ECs) by VEGF-A provides cues that enable leukemic cells to proliferate at higher rates and also increases adhesion of leukemia to ECs. Development of drugs that target the activation state of the vascular niche could prove to be an effective adjuvant therapy in combination with chemotherapeutic agents (36). On the other hand, high-level expression of VEGF-C is associated with chemoresistance and adverse prognosis in AML. VEGF-C induces COX-2-mediated resistance to chemotherapy through induction of ET-1 expression. Acting as a key regulator in the VEGF-C/COX-2 axis, ET-1 represents a potential target for ameliorating resistance to chemotherapy in AML patients (37). Lenalidomide is an IMiD immunomodulatory agent clinically active in patients with CLL, the anti-CLL effect of lenalidomide is mediated through the alteration of microenvironmental elements, implying the modulation of several angiogenesis-related factors and disruption of CLL crosstalk with endothelial cells (38). Indeed, the leukemic environment is highly enriched with lymphangiogenic stimuli, and that inhibition of VEGFR-3 restored function of NK cells, providing therapeutic value of modulation of NK cells by blocking VEGFR-3 and provided a possibility of advanced therapeutic approaches using immune cells against myelogenous leukemia (39). Understanding the functional characterization of lymphangiogenic factors in the BM niche in AML will also be helpful in interrupting the engraftment of leukemic stem cells and enhancing immune cell function by modulating the tumor microenvironment (25).

3. C-myc as an important tumor angiogenesis factor in leukemia

The *c-myc* gene is a member of the Myc proto-oncogene family, and it is a pleiotropic transcription regulator. It can induce the instability of the genome and affect the occurrence and progression of tumors directly or indirectly, so it plays an important role in cell proliferation and programmed cell death (40). Binding DNA in a sequence-specific manner and having a basic

helix-loop-helix leucine zipper transcription factor can be attributed to *c-myc* (41). Heterodimerizing with corresponding protein partner, MAX, binding the enhancer box (E-box) sequence and stimulating transcription of some corresponding downstream genes provide support for the biological activities of *c-myc* (42). With E-box binding sites, these genes include *ODC*, *ECA39*, *eIF4E*, *CDC25*, *CAD*, *CDK4*, *eIF4G1*, *hTert*, and *CCND1* which belong to the direct target genes of *c-myc* (43).

In recent years, it has been discovered that *c-myc* also acts as an important tumor angiogenesis factor (TAF) and participates in tumor angiogenesis, and *c-myc* was related to the expression of VEGF (44). There is a *c-myc*-binding region located at the 271bp of the VEGF promoter. This region can bind *c-myc* after the directed mutagenesis of the VEGF promoter and induce VEGF expression in hypoxic conditions to promote angiogenesis and tumorigenesis. On the other hand, some other reports also elucidated the role of *c-myc* in modulating angiogenesis. For example, tumor angiogenesis could be promoted by miRNA-induced *c-myc* activation (45), and IL-1 β is the effector of the *c-myc*-induced angiogenesis initiation (46).

Moreover, *c-myc* is highly expressed in HL-60 leukemic cells and is related to proliferation and differentiation of the leukemic cells. The *c-myc* gene can be abnormally activated by amplification activation or gene rearrangement, and its expression level is related to the cell growth state and highly expressed in the undifferentiated stage. It is an interesting target for novel drug therapies because of its oncogenic activities and overexpression in a majority of human cancers (47). Binding inhibition of *c-myc* on gene promoters by some small molecule inhibitors has been tried (48,49), and found that some of them were effective in disrupting essential protein-DNA interactions, for example, Pyrrole-imidazole (PI) polyamides, specific sequence DNA-binding small molecules (50-52), and can inhibit a part of E-box-mediated *c-myc* downstream gene expression (47). EGFR variant III (EGFRvIII), which strongly induces neovascularization in tumors, could induce Angptl4 expression through the ERK/*c-myc* pathway. Therefore, ERK/*c-myc*, EGFRvIII or Angptl4 may be a possible therapeutic target (53). Tumor-associated macrophages (TAMs) can also express *c-myc*, which can regulate their phenotype and pro-tumor activities *in vivo*. Targeting *c-myc* function in TAMs may control tumor growth (54,55). As discovered in the above-mentioned reports, *c-myc* has become an ideal target of gene therapies for tumors or leukemias.

4. MMPs family in hematologic malignancies are gradually elucidated

MMPs are a series of zinc-finger-dependent proteinases with high homology (56). There are three common

domains of the MMPs: pro-peptide, catalytic domain and hemopexin-like C-terminal domain. According to the distinct specificities of their amino acid sequences and substrates, they can be classified into five types: collagenases (MMP-1, MMP-8, MMP-13, and MMP-18), gelatinases (MMP-2, MMP-9), stromelysins (MMP-3, MMP-10 and MMP-11), matrilysins (MMP-7, MMP-26), and other types. MMPs can degrade the extracellular matrix which is thought to be the start signal and important pathway of angiogenesis, invasion and metastasis of tumors.

Some studies have reported that MMPs expression was related to metastatic potential of various human tumors, and plays an essential part during the development of leuko-diapedesis (57) and disseminated intravascular coagulation (DIC) (58). As to the modulation of MMPs, there are some important transcription factors, such as activator protein-1 (AP-1), Ets transcription factors PEA3, nuclear factor kappa-light-chain-enhancer of activated B cells (NFkB) and signal transducer and activator of transcription (STAT) families, which are involved in the regulation of MMPs expression, and many growth factors enhance the levels of transcriptional regulation of VEGF (59). The enhancement of the invasive properties of human tumor cells was also related to the low expression of tissue inhibitors of matrix metalloproteinases (TIMP) (60), including TIMP-1, -2, -3 and -4. In addition, the expression of TIMP levels could directly affect the activity level of MMPs (61). Constitutive release of several MMPs and TIMPs can be secreted by primary human AML cells and affect the behavior of leukemia cells. As for clinical use of MMPs and TIMPs, this must be better clarified before we use such therapeutic agents in the treatment of human AML (62). The amount of ECM molecules including type IV, V and XI collagens, laminin and aggrecan core protein will also be digested by MMPs and was related to the angiogenesis and metastasis of tumors (63), for example, MMP-1 as a negative regulatory factor in angiogenesis, growth and metastasis of tumors (64), MMP-13 promoting secretion of VEGF and inducing tumor angiogenesis *in vivo* (65), and important roles of stromelysin members MMP-3, MMP-10 and MMP-11 in activation of proMMPs or activation of tumor cells (66). Due to lack of a hemopexin domain, matrilysins (MMP-7 and -26) can be considered as MMPs, and it has been discovered that MMP-7 not only plays an important role in the degradation of the extracellular matrix proteins, but also plays an equally important role in protein activation, degradation, abscission and other biochemical processes of non-extracellular matrix proteins, which is essential for tumor growth and tumor angiogenesis (67). The role of MMP-26 is different from most other MMPs and needs further investigation (68). Meanwhile, MMPs are usually overly expressed in tumors, and overexpression of the gelatinases including MMP-2 and

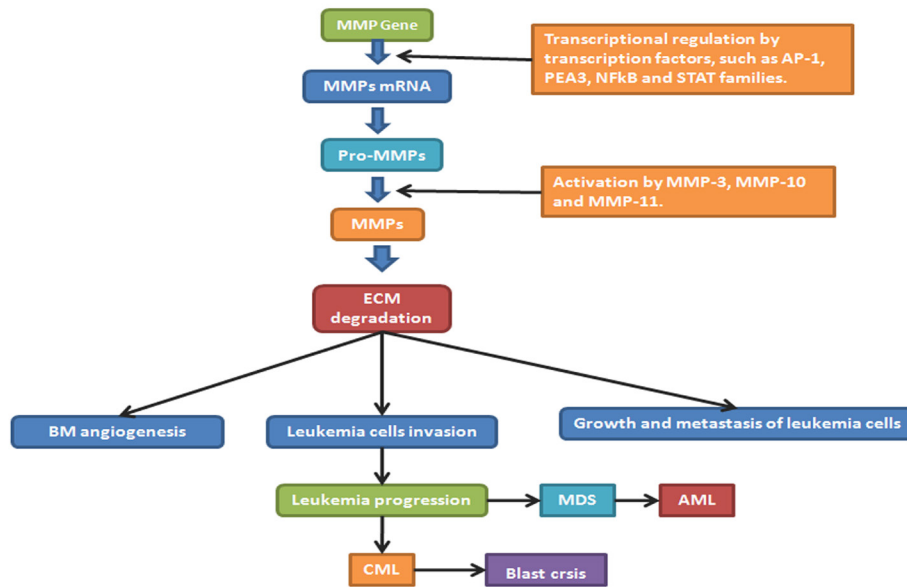


Figure 2. The regulation of MMPs and their roles in leukemia progression. AP-1: activator protein-1 ; NFkB : nuclear factor kappa-light-chain-enhancer of activated B cells; STAT: signal transducer and activator of transcription; BM: bone marrow; ECM: extra cellular matrix; GF: growth factor; EGFR: epidermal growth factor; MDS: myelodysplastic syndrome; AML: acute myeloid leukemia; CML: chronic myeloid leukemia.

MMP-9 is always accompanied by growth, metastasis and angiogenesis of the tumors, with different roles concerning collagenases, for example MMP-2 targeting collagens I,II and III, but not MMP-9 (63).

Reports about the functions of MMP-2 and MMP-9 in hematologic malignancies are gradually increasing, and it is thought they are closely related to VEGF (69). Serum MMP-9 not only can be likely to predict clinical outcome of patients with early CLL but also can help to refine the prognosis of CLL (70). In MDS, MMPs expression may produce a useful tool for diagnosis, prognosis and a possible target for clinical treatment. Similar to chemokines, primary human AML cells usually show constitutive release of several MMPs (71), such as matrix MMP-2 and MMP-9, TIMP1 and VEGF (26). In addition, the proteolytic release of VEGF from tumor matrix by MMPs, predominantly by MMP-9, which was delivered into the tumor microenvironment by tumor-infiltrating leukocytes, plays an important role in modulating proliferation of leukemia cells (72). Moreover, as for a mutually coordinated manner on a transcriptional level, it can regulate expression and secretion of VEGF and MMPs. According to a common master regulator, a hypoxia-inducible factor HIF-1 was closely related to expression of both VEGF and MMP-9 (73), and VEGF could significantly reduce MMP-9 production in B-cell leukemia cells (21). MMPs blockade can completely inhibit VEGF production and significantly reduce the volume of angiogenic vasculature (22). It has been confirmed in some research that activation of MMP-2 is dependent on metalloproteinase inhibitor 2 (TIMP-2) and membrane type-1 matrix metalloproteinase (MT1-MMP). TIMP-

2 is the activity inhibitor of MMP-2, whereas, when the concentration of TIMP-2 increases to a certain level, it will combine with MT1-MMP and activate MMP-2, which will give rise to a succession of tumor activation (66). Figure 2 shows the role of MMPs and its inhibitors in the progression of hematological malignancies such as MDS, AML and chronic myeloid leukemia (CML) (74). Because of the role of MMP in development of leukemias, specific MMP inhibitors are currently not only being developed but also being considered for cancer therapy. However, there is nothing harvested in passing clinical trials so far (75). More attention should be paid on targeting of MMPs as an antileukemic strategy due to the importance in future clinical development of this therapeutic strategy (71). Therefore, in multiple ways, MMPs directly and indirectly influence the VEGF-mediated development of an angiogenic vasculature.

5. VEGF-related HIF-1 involved in hematological malignancy

HIF-1 was first discovered as a hypoxia-inducible nuclear factor connected to the hypoxia response element (HRE) of the erythropoietin (EPO) gene. It is an oxygen-sensitive transcription activator that can activate the expression of many hypoxia response genes. In hypoxia HIF-1 α becomes stable and can interact with the auxiliary co-stimulatory factor CBP/P300 to regulate activity of oncogenes (76). Nuclear translocation of HIF-1 α is in need of the participation of its innate PAS domain and C-terminal nuclear transport signal, but how these sequences interact with oxygen-sensitive signals

in detail still needs further clarification. HIF-1 could be negatively regulated by inhibitory PAS domain protein (IPAS), of which the pro-apoptotic activity is by way of binding to pro-survival Bcl-2 family proteins (77). To date it has been confirmed that in aerobic conditions the conserved proline residue in HIF-1 α can be hydroxylated so that it can be recognized by the E3 ubiquitin ligase complex containing the tumor suppressor gene product VHL protein and undergo further proteasomal degradation (78). HIF-1 α not only stimulates Ang production but also regulates the expression level of the Ang receptor; In addition, HIF-1 α also plays an important role in the metabolism of the extracellular matrix. HIF- α has various other effects after activation such as causing adaptive changes in cell metabolism, shifting aerobic metabolism to glycolysis-centered anaerobic metabolism and meanwhile stimulating renal cells to produce EPO which will act as the main regulator inducing angiogenesis in malignant tumors (79). HIF-1 α can also affect angiogenesis and promote the growth and development of tumor cells by enhancing the expression of downstream target genes including VEGF (80).

It has been discovered in some research that with accumulation of HIF-1 α in myeloid leukemic cells and normal hematologic stem cells the simulacrum of hypoxia or anoxia will lead to cell differentiation (81). The Guoqiang Chen research group has discovered that hypoxia can lead to differentiation of leukemic cells accompanied by accumulation of the hypoxia inducible factor HIF-1 α , and thereafter, that hypoxia can induce differentiation and maturation of leukemic cells into neutrophils (82). In addition, HIF-1 α protein promotes tumor growth, angiogenesis, and metastasis (83), and it could be increased by hypoxia in primary human AML cells. Similarly, low HIF-1 α expression and also release of several proangiogenic cytokines by leukemia cells can be induced by low oxygen concentration (84). It is reported in some research that HIF-1 α protein can motivate differentiation of AML cells through an independent transcription mechanism, inhibiting AML progress (85). Studies showed that HIF-1 α suppresses the expression of miR-17 and miR-20a, two miRNAs that can alleviate HIF-1 α -induced differentiation and hypoxia of AML cells, by downregulating c-Myc expression (86). Moreover, miR-17 and miR-20a immediately inhibit p21 and STAT3 expression (86). Some observations indicated that HIF-1 α , which plays an important role in the survival of ALL blasts, may be conducive to chemoresistance. It is proposed that targeting HIF-1 α itself (87), its upstream mediators such as mTOR, or the glycolytic pathways will improve therapeutic efficacy in ALL (88).

6. Angiogenin (Ang) family related to leukemogenesis

Ang is the secreted type of the angiogenic factors and the angiogenin family includes Ang-1, Ang-2, Ang-

3, Ang-4 and the Ang-like proteins. These family members have similar structures including secreted protein signal sequence, coiled-coil domain and fibrinogen-like domain. The angiogenin promoter contains the binding site for TCF/LEF, and TCF/LEF is a transcription factor with bilateral regulatory effects which acts as the intermediate medium of the Wnt/ β -catenin signaling pathway (89). Ang-1 can support remodeling and maturation of vascular endothelial cells, and promote establishment of local collateral circulation. Furthermore, depending on an attributed anti-inflammatory role, Ang1 not only can promote pericyte-dependent vessel integrity but also can support a Tie2-constitutively activated state. As a result of this, Ang-1 is able to modulate the quiescent vascular endothelium (90). Acting in a mutually complementary manner in angiogenesis, VEGF mainly functions in early stages and Ang-1 mainly functions in later stages. Although Ang-1 doesn't take part in initiation of angiogenesis, it can maintain stability of the vessels and promote maturation of the newly formed vessels. Ang1 and Ang-2 are widely different in their biological roles although they are homologous (91). As the antagonist of Ang-1, on the one hand, during vasculogenesis and inflammation Ang-2 can be strongly released. On the other hand, Ang-2 can be considered as an angiogenic inhibitor that is involved in destabilization and vascular remodelling (90,92). Ang-2 is related to angiogenesis initiation and extension and affects cell growth and metastasis. With high Ang-2 levels, there is an associated upregulation of VEGF (93). Ang-2 doesn't directly stimulate angiogenesis, but in the presence of VEGF, Ang-2 can inhibit the stabilizing effects of Ang-1 on the vessels, eliminate restriction on angiogenesis caused by the basal membrane and peripheral stromal cells and enhance sensitivity of endothelial cells to growth factors, so that angiogenesis in tumors is promoted (94).

This is an important reason that tumor initiation and development contribute to the increasing levels of Ang in malignancies (95). Ang upregulation was investigated in AML, myelodysplastic syndrome (MS), and a variety of other malignancies (96). CLL patients may have a negative impact on their disease course with a notable increase of Ang-2 ligand expression (97), which is accompanied with an aberrant vascularization in (bone marrow) BM sections (98). Recent epigenetic evidence showed that Ang-2 displays lower DNA methylation in CLL and correlates with poor prognosis and shorter survival (97). Additionally, Binet staging can be linked to elevated levels of Ang-2 (93). It was shown in a series of experiments that Ang-2 regulates the pathophysiology of CLL cells through the Ang-Tie signalling pathways (5). The theory of suggesting that Ang is a possible prognostic marker and potential target of anti-angiogenic therapy was proposed by Pavlov *et al.*, previously (99). Ang-1 expression in

BM sections, which is an independent prognostic factor towards overall survival of MDS patients, has potential to be a new biomarker for predicting clinical treatment (100). In human acute myelogenous leukemia (AML) the balance between Ang-1 and the Ang-2 plays an important role for both in leukemogenesis. The release from AML cells, is a major source of Ang-1 in leukemic BM. On the contrary, local Ang-2 is released less commonly (101). Further investigation will make a contribution to act on the angiopoietin system as a possible therapeutic target in AML patients.

7. The relationship between FGF and leukemias

FGF is a kind of mitogen-activated angiogenic factor, which plays an important role in many tumors. FGF is a protein family composed of at least 23 members: FGF1 to FGF23. Acidic FGF (aFGF or FGF1) and basic FGF (bFGF or FGF2) were discovered earliest and also are the most widely studied ones with the most important functions so far. With their respective acidic isoelectric point and alkaline isoelectric point, FGF1 and FGF2 are called acidic fibroblast growth factor and alkaline fibroblast growth factor respectively. They are transported with the same mechanisms that can be enhanced in the presence of heparin. They act on the same receptor but the affinity of aFGF is 30 to 100 times stronger than that of bFGF. It was first reported by Gospodarowicz that the alkaline fibroblast growth factor was extracted and purified from the cerebrum and pituitary with physical and chemical methods (102). During the 80's, the amino acid sequence of bFGF was clarified, and during the 90's, recombinant bFGF was produced by genetic engineering abroad and home successively, which forcefully propelled research concerning bFGF.

Various studies have shown that bFGF can stimulate and regulate proliferation and differentiation of various types of cells stemming from mesoderm and neuroectoderm such as vascular endothelial cells, epithelial cells, myoblasts, osteoblasts and neurogliaocytes which play an important role in embryogenesis and tissue healing, and additionally up-regulate VEGF expression (103). As a strong mitogenic factor and chemokine of vascular endothelial cells, bFGF is produced by paracrine and autocrine cells, and can combine with different receptors on the surface of vascular endothelial cells including TKR, heparan sulfate proteoglycan and cell adhesion molecules (CAMs) to activate their vasogenic characteristics (104,105). bFGF can also activate the P13K signaling pathway to inhibit apoptosis of vascular endothelial cells and promote angiogenesis (106). As a chemokine, bFGF can attract many kinds of vascular intimal cells by chemotaxis and induce them to produce proteolytic enzymes and collagenase which can promote the proliferation and migration of vascular endothelial

cells as well as degrade extracellular matrix proteins to induce angiogenesis (107).

It is reported that upregulation of bFGF can be detected in acute myelocytic leukemia (AML), chronic myelomonocytic leukemia (CML), and CLL, and is correlated with poorer prognosis (108). Through the FGF receptor 3/RAS/c-RAF/mitogen-activated protein kinase pathway, it was indicated that FGF2 is able to promote the growth of both short- and long-term assays (109). At the same time, FGF2 in the marrow was decreased relating to ponatinib, which furthermore suggests that FGF receptor inhibition can interrupt FGF2-mediated resistance (110). In addition, developing combinations of kinase inhibitors that circumvent resistance can provide a potential chance to identify critical ligand-RTK pathways of resistance(110).

8. Perspectives

As angiogenic factors and their functions are more and more deeply understood, targeted therapy aiming at angiogenesis in hematologic malignancies is attached to more and more importance. In targeted therapy based on antibodies against the vessels of hematologic malignancies, it is crucial to detect new specific target molecules of tumor vessels. Targeting to each segment of tumor angiogenesis and relevant regulatory factors, developing angiogenesis inhibitors to restrict tumor growth and metastasis has become a new approach and effective means in oncotherapies. In recent years, combination therapy with multiple targets has provided a brand-new research direction for anti-angiogenesis. Although this research is still confined to basic experimentation and clinical trials without reflection of its value in clinical practice, with the development of basic research and anti-angiogenic agents, the deepening of tumor vascular targeting therapy will open up a new area for treatment of hematologic malignancies.

Acknowledgements

This study was supported by the National Natural Science Foundation of China (81101605, 81172792, 81573467), the 'Twelfth Five-Year' National Science and Technology Support Program (2013BAI07B02), the Natural Science Foundation of Shandong Province of China (ZR2011HL045, ZR2015YL028, 2015ZRC03102) and the Project for Laureate of Taishan Scholar (NO.ts201511075).

References

1. Medinger M, Passweg J. Angiogenesis in myeloproliferative neoplasms, new markers and future directions. *Memo.* 2014; 7:206-210.

2. Perez-Atayde AR, Sallan SE, Tedrow U, Connors S, Allred E, Folkman J. Spectrum of tumor angiogenesis in the bone marrow of children with acute lymphoblastic leukemia. *Am J Pathol.* 1997; 150:815-821.
3. Jain RK. Antiangiogenesis strategies revisited: From starving tumors to alleviating hypoxia. *Cancer Cell.* 2014; 26:605-622.
4. Piechnik A, Dmoszynska A, Omiotek M, Mlak R, Kowal M, Stilgenbauer S, Bullinger L, Giannopoulos K. The VEGF receptor, neuropilin-1, represents a promising novel target for chronic lymphocytic leukemia patients. *Int J Cancer.* 2013; 133:1489-1496.
5. Aguirre Palma LM, Gehrke I, Kreuzer KA. Angiogenic factors in chronic lymphocytic leukaemia (CLL): Where do we stand? *Crit Rev Oncol Hematol.* 2015; 93:225-236.
6. Medinger M, Passweg J. Role of tumour angiogenesis in haematological malignancies. *Swiss Med Wkly.* 2014; 144:w14050.
7. Dor Y, Porat R, Keshet E. Vascular endothelial growth factor and vascular adjustments to perturbations in oxygen homeostasis. *Am J Physiol Cell Physiol.* 2001; 280:C1367-1374.
8. Ferrara N, Henzel WJ. Pituitary follicular cells secrete a novel heparin-binding growth factor specific for vascular endothelial cells. *Biochem Biophys Res Commun.* 1989; 161:851-858.
9. Senger DR, Galli SJ, Dvorak AM, Perruzzi CA, Harvey VS, Dvorak HF. Tumor cells secrete a vascular permeability factor that promotes accumulation of ascites fluid. *Science.* 1983; 219:983-985.
10. de Vries C, Escobedo JA, Ueno H, Houck K, Ferrara N, Williams LT. The fms-like tyrosine kinase, a receptor for vascular endothelial growth factor. *Science.* 1992; 255:989-991.
11. Brekken RA, Overholser JP, Stastny VA, Waltenberger J, Minna JD, Thorpe PE. Selective inhibition of vascular endothelial growth factor (VEGF) receptor 2 (KDR/Flk-1) activity by a monoclonal anti-VEGF antibody blocks tumor growth in mice. *Cancer Res.* 2000; 60:5117-5124.
12. Yancopoulos GD, Davis S, Gale NW, Rudge JS, Wiegand SJ, Holash J. Vascular-specific growth factors and blood vessel formation. *Nature.* 2000; 407:242-248.
13. Ferrara N, Gerber HP, LeCouter J. The biology of VEGF and its receptors. *Nat Med.* 2003; 9:669-676.
14. Hattori K, Dias S, Heissig B, Hackett NR, Lyden D, Tateno M, Hicklin DJ, Zhu Z, Witte L, Crystal RG, Moore MA, Rafii S. Vascular endothelial growth factor and angiopoietin-1 stimulate postnatal hematopoiesis by recruitment of vasculogenic and hematopoietic stem cells. *J Exp Med.* 2001; 193:1005-1014.
15. Casella I, Feccia T, Chelucci C, Samoggia P, Castelli G, Guerriero R, Parolini I, Petrucci E, Pelosi E, Morsilli O, Gabbianelli M, Testa U, Peschle C. Autocrine-paracrine VEGF loops potentiate the maturation of megakaryocytic precursors through Flt1 receptor. *Blood.* 2003; 101:1316-1323.
16. Bardelli M, Leucci E, Schürfeld K, Bellan C, Passiatore G, Rocchigiani M, Bartolommei S, Orlandini M, Zagursky J, Lazzi S, De Falco G, Tosi P, Oliviero S, Leoncini L. VEGF-D is expressed in activated lymphoid cells and in tumors of hematopoietic and lymphoid tissues. *Leuk Lymphoma.* 2007; 48:2014-2021.
17. Hanahan D, Weinberg RA. The hallmarks of cancer. *Cell.* 2000; 100:57-70.
18. Adams J, Carder PJ, Downey S, Forbes MA, MacLennan K, Allgar V, Kaufman S, Hallam S, Bicknell R, Walker JJ, Cairnduff F, Selby PJ, Perren TJ, Lansdown M, Banks RE. Vascular endothelial growth factor (VEGF) in breast cancer: Comparison of plasma, serum, and tissue VEGF and microvessel density and effects of tamoxifen. *Cancer Res.* 2000; 60:2898-2905.
19. Dias S, Hattori K, Heissig B, Zhu Z, Wu Y, Witte L, Hicklin DJ, Tateno M, Bohlen P, Moore MA, Rafii S. Inhibition of both paracrine and autocrine VEGF/VEGFR-2 signaling pathways is essential to induce long-term remission of xenotransplanted human leukemias. *Proc Natl Acad Sci U S A.* 2001; 98:10857-10862.
20. Lee MS, Ghim J, Kim SJ, Yun YS, Yoo SA, Suh PG, Kim WU, Ryu SH. Functional interaction between CTGF and FPRL1 regulates VEGF-A-induced angiogenesis. *Cell Signal.* 2015; 27:1439-1448.
21. Woenne EC, Lederle W, Zwick S, Palmowski M, Krell H, Semmler W, Mueller MM, Kiessling F. MMP inhibition blocks fibroblast-dependent skin cancer invasion, reduces vascularization and alters VEGF-A and PDGF-BB expression. *Anticancer Res.* 2010; 30:703-711.
22. Wu X, Liu BJ, Ji S, Wu JF, Xu CQ, Du YJ, You XF, Li B, Le JJ, Xu HL, Duan XH, Dong JC. Social defeat stress promotes tumor growth and angiogenesis by upregulating vascular endothelial growth factor/extracellular signal-regulated kinase/matrix metalloproteinase signaling in a mouse model of lung carcinoma. *Mol Med Rep.* 2015; 12:1405-1412.
23. Haouas H. Angiogenesis and acute myeloid leukemia. *Hematology.* 2014; 19:311-323.
24. Song G, Li Y, Jiang G. Role of VEGF/VEGFR in the pathogenesis of leukemias and as treatment targets (Review). *Oncol Rep.* 2012; 28:1935-1944.
25. Lee JY, Kim HJ. (Lymph)angiogenic influences on hematopoietic cells in acute myeloid leukemia. *Exp Mol Med.* 2014; 46:e122.
26. Marinaccio C, Nico B, Maiorano E, Specchia G, Ribatti D. Insights in Hodgkin Lymphoma angiogenesis. *Leuk Res.* 2014; 38:857-861.
27. Kon Kim T, Gore SD, Zeidan AM. Epigenetic Therapy in Acute Myeloid Leukemia: Current and Future Directions. *Semin Hematol.* 2015; 52:172-183.
28. Garcia-Manero G, Tibes R, Kadia T, *et al.* Phase 1 dose escalation trial of ilorasertib, a dual Aurora/VEGF receptor kinase inhibitor, in patients with hematologic malignancies. *Invest New Drugs.* 2015; 33:870-880.
29. Zhang L, Song K, Zhou L, Xie Z, Zhou P, Zhao Y, Han Y, Xu X, Li P. Heparan sulfate D-glucosaminyl 3-O-sulfotransferase-3B1 (HS3ST3B1) promotes angiogenesis and proliferation by induction of VEGF in acute myeloid leukemia cells. *Journal of cellular biochemistry.* 2015; 116:1101-1112.
30. Zeng D, Wang J, Kong P, Chang C, Li J, Li J. Ginsenoside Rg3 inhibits HIF-1 α and VEGF expression in patient with acute leukemia *via* inhibiting the activation of PI3K/Akt and ERK1/2 pathways. *J Cell Biochem.* 2014; 7:2172-2178.
31. Zhang ZH, Hao CL, Liu P, Tian X, Wang LH, Zhao L, Zhu CM. Valproic acid inhibits tumor angiogenesis in mice transplanted with Kasumi1 leukemia cells. *Mol Med Rep.* 2014; 9:443-449.
32. Kvestad H, Evensen L, Lorens JB, Bruserud O, Hatfield KJ. *In Vitro* Characterization of Valproic Acid, ATRA, and Cytarabine Used for Disease-Stabilization in Human Acute Myeloid Leukemia: Antiproliferative Effects of

- Drugs on Endothelial and Osteoblastic Cells and Altered Release of Angioregulatory Mediators by Endothelial Cells. *Leuk Res Treatment*. 2014; 2014:143479.
33. Huynh H, Ong R, Soo KC. Foretinib demonstrates anti-tumor activity and improves overall survival in preclinical models of hepatocellular carcinoma. *Angiogenesis*. 2012; 15:59-70.
 34. Chen HM, Tsai CH, Hung WC. Foretinib inhibits angiogenesis, lymphangiogenesis and tumor growth of pancreatic cancer *in vivo* by decreasing VEGFR-2/3 and TIE-2 signaling. *Oncotarget*. 2015; 6:14940-14952.
 35. Mattison R, Jumonville A, Flynn PJ, Moreno-Aspitia A, Erlichman C, LaPlant B, Juckett MB. A phase II study of AZD2171 (cediranib) in the treatment of patients with acute myeloid leukemia or high-risk myelodysplastic syndrome. *Leukemia & lymphoma*. 2015; 56:2061-2066.
 36. Poulos MG, Gars EJ, Gutkin MC, Kloss CC, Ginsberg M, Scandura JM, Rafii S, Butler JM. Activation of the vascular niche supports leukemic progression and resistance to chemotherapy. *Exp Hematol*. 2014; 42:976-986 e971-973.
 37. Hua KT, Lee WJ, Yang SF, Chen CK, Hsiao M, Ku CC, Wei LH, Kuo ML, Chien MH. Vascular endothelial growth factor-C modulates proliferation and chemoresistance in acute myeloid leukemic cells through an endothelin-1-dependent induction of cyclooxygenase-2. *Biochim Biophys Acta*. 2014; 1843:387-397.
 38. Maffei R, Fiorcari S, Bulgarelli J, *et al*. Endothelium-mediated survival of leukemic cells and angiogenesis-related factors are affected by lenalidomide treatment in chronic lymphocytic leukemia. *Exp Hematol*. 2014; 42:126-36.e1.
 39. Lee JY, Park S, Min WS, Kim HJ. Restoration of natural killer cell cytotoxicity by VEGFR-3 inhibition in myelogenous leukemia. *Cancer Lett*. 2014; 354:281-289.
 40. Wang F, Chan LW, Cho WC, Tang P, Yu J, Shyu CR, Tsui NB, Wong SC, Siu PM, Yip SP, Yung BY. Novel approach for coexpression analysis of E2F1-3 and MYC target genes in chronic myelogenous leukemia. *Biomed Res Int*. 2014; 2014:439840.
 41. Blackwood EM, Eisenman RN. Max: A helix-loop-helix zipper protein that forms a sequence-specific DNA-binding complex with Myc. *Science*. 1991; 251:1211-1217.
 42. Liu YC, Li F, Handler J, Huang CR, Xiang Y, Neretti N, Sedivy JM, Zeller KI, Dang CV. Global regulation of nucleotide biosynthetic genes by c-Myc. *PLoS One*. 2008; 3:e2722.
 43. Lin CJ, Cencic R, Mills JR, Robert F, Pelletier J. c-Myc and eIF4F are components of a feedforward loop that links transcription and translation. *Cancer Res*. 2008; 68:5326-5334.
 44. Mizukami Y, Fujiki K, Duerr EM, Gala M, Jo WS, Zhang X, Chung DC. Hypoxic regulation of vascular endothelial growth factor through the induction of phosphatidylinositol 3-kinase/Rho/ROCK and c-Myc. *J Biol Chem*. 2006; 281:13957-13963.
 45. Dews M, Homayouni A, Yu D, Murphy D, Sevignani C, Wentzel E, Furth EE, Lee WM, Enders GH, Mendell JT, Thomas-Tikhonenko A. Augmentation of tumor angiogenesis by a Myc-activated microRNA cluster. *Nat Genet*. 2006; 38:1060-1065.
 46. Shchors K, Shchors E, Rostker F, Lawlor ER, Brown-Swigart L, Evan GI. The Myc-dependent angiogenic switch in tumors is mediated by interleukin 1beta. *Genes Dev*. 2006; 20:2527-2538.
 47. Mishra R, Watanabe T, Kimura MT, *et al*. Identification of a novel E-box binding pyrrole-imidazole polyamide inhibiting MYC-driven cell proliferation. *Cancer Sci*. 2015; 106:421-429.
 48. Wang H, Chauhan J, Hu A, Pendleton K, Yap JL, Sabato PE, Jones JW, Perri M, Yu J, Cione E, Kane MA, Fletcher S, Prochownik EV. Disruption of Myc-Max heterodimerization with improved cell-penetrating analogs of the small molecule 10074-G5. *Oncotarget*. 2013; 4:936-947.
 49. Delmore JE, Issa GC, Lemieux ME, *et al*. BET bromodomain inhibition as a therapeutic strategy to target c-Myc. *Cell*. 2011; 146:904-917.
 50. Nickols NG, Szablowski JO, Hargrove AE, Li BC, Raskatov JA, Dervan PB. Activity of a Py-Im polyamide targeted to the estrogen response element. *Mol Cancer Ther*. 2013; 12:675-684.
 51. Yang F, Nickols NG, Li BC, Marinov GK, Said JW, Dervan PB. Antitumor activity of a pyrrole-imidazole polyamide. *Proc Natl Acad Sci U S A*. 2013; 110:1863-1868.
 52. Raskatov JA, Nickols NG, Hargrove AE, Marinov GK, Wold B, Dervan PB. Gene expression changes in a tumor xenograft by a pyrrole-imidazole polyamide. *Proc Natl Acad Sci U S A*. 2012; 109:16041-16045.
 53. Katanasaka Y, Kodera Y, Kitamura Y, Morimoto T, Tamura T, Koizumi F. Epidermal growth factor receptor variant type III markedly accelerates angiogenesis and tumor growth *via* inducing c-myc mediated angiopoietin-like 4 expression in malignant glioma. *Mol Cancer*. 2013; 12:31.
 54. Pello OM, Andres V. Role of c-MYC in tumor-associated macrophages and cancer progression. *Oncoimmunology*. 2013; 2:e22984.
 55. Pello OM, De Pizzol M, Mirolo M, Soucek L, Zammataro L, Amabile A, Doni A, Nebuloni M, Swigart LB, Evan GI, Mantovani A, Locati M. Role of c-MYC in alternative activation of human macrophages and tumor-associated macrophage biology. *Blood*. 2012; 119:411-421.
 56. Eisen AZ, Jeffrey JJ, Gross J. Human skin collagenase. Isolation and mechanism of attack on the collagen molecule. *Biochim Biophys Acta*. 1968; 151:637-645.
 57. Tschesche H. Leukodiapedesis, function, and physiological role of leucocyte matrix metalloproteinases. *Adv Exp Med Biol*. 1997; 421:285-301.
 58. Ries C, Loher F, Zang C, Ismail MG, Petrides PE. Matrix metalloproteinase production by bone marrow mononuclear cells from normal individuals and patients with acute and chronic myeloid leukemia or myelodysplastic syndromes. *Clin Cancer Res*. 1999; 5:1115-1124.
 59. Yan C, Boyd DD. Regulation of matrix metalloproteinase gene expression. *Journal of cellular physiology*. 2007; 211:19-26.
 60. Alexander CM, Werb Z. Targeted disruption of the tissue inhibitor of metalloproteinases gene increases the invasive behavior of primitive mesenchymal cells derived from embryonic stem cells *in vitro*. *J Cell Biol*. 1992; 118:727-739.
 61. Chaudhary AK, Pandya S, Ghosh K, Nadkarni A. Matrix metalloproteinase and its drug targets therapy in solid and hematological malignancies: An overview. *Mutat Res*. 2013; 753:7-23.

62. Reikvam H, Hatfield KJ, Oyan AM, Kalland KH, Kittang AO, Bruserud O. Primary human acute myelogenous leukemia cells release matrix metalloproteases and their inhibitors: Release profile and pharmacological modulation. *European journal of haematology*. 2010; 84:239-251.
63. Patterson ML, Atkinson SJ, Knauper V, Murphy G. Specific collagenolysis by gelatinase A, MMP-2, is determined by the hemopexin domain and not the fibronectin-like domain. *FEBS Lett*. 2001; 503:158-162.
64. Jost M, Folgueras AR, Frerart F, Pendas AM, Blacher S, Houard X, Berndt S, Munaut C, Cataldo D, Alvarez J, Melen-Lamalle L, Foidart JM, Lopez-Otin C, Noel A. Earlier onset of tumoral angiogenesis in matrix metalloproteinase-19-deficient mice. *Cancer Res*. 2006; 66:5234-5241.
65. Kudo Y, Iizuka S, Yoshida M, Tsunematsu T, Kondo T, Subarnbhesaj A, Deraz EM, Siriwardena SB, Tahara H, Ishimaru N, Ogawa I, Takata T. Matrix metalloproteinase-13 (MMP-13) directly and indirectly promotes tumor angiogenesis. *J Biol Chem*. 2012; 287:38716-38728.
66. Friehs I, Margossian RE, Moran AM, Cao-Danh H, Moses MA, del Nido PJ. Vascular endothelial growth factor delays onset of failure in pressure-overload hypertrophy through matrix metalloproteinase activation and angiogenesis. *Basic research in cardiology*. 2006; 101:204-213.
67. Li M, Yamamoto H, Adachi Y, Maruyama Y, Shinomura Y. Role of matrix metalloproteinase-7 (matrilysin) in human cancer invasion, apoptosis, growth, and angiogenesis. *Exp Biol Med (Maywood)*. 2006; 231:20-27.
68. Marchenko ND, Marchenko GN, Weinreb RN, Lindsey JD, Kyshtoobayeva A, Crawford HC, Strongin AY. Beta-catenin regulates the gene of MMP-26, a novel metalloproteinase expressed both in carcinomas and normal epithelial cells. *Int J Biochem Cell Biol*. 2004; 36:942-956.
69. Zheng H, Takahashi H, Murai Y, Cui Z, Nomoto K, Niwa H, Tsuneyama K, Takano Y. Expressions of MMP-2, MMP-9 and VEGF are closely linked to growth, invasion, metastasis and angiogenesis of gastric carcinoma. *Anticancer research*. 2006; 26:3579-3583.
70. Buggins AG, Levi A, Gohil S, Fishlock K, Patten PE, Calle Y, Yallop D, Devereux S. Evidence for a macromolecular complex in poor prognosis CLL that contains CD38, CD49d, CD44 and MMP-9. *Br J Haematol*. 2011; 154:216-222.
71. Hatfield KJ, Reikvam H, Bruserud O. The crosstalk between the matrix metalloprotease system and the chemokine network in acute myeloid leukemia. *Current medicinal chemistry*. 2010; 17:4448-4461.
72. Bergers G, Brekken R, McMahon G, Vu TH, Itoh T, Tamaki K, Tanzawa K, Thorpe P, Itohara S, Werb Z, Hanahan D. Matrix metalloproteinase-9 triggers the angiogenic switch during carcinogenesis. *Nat Cell Biol*. 2000; 2:737-744.
73. Liao D, Johnson RS. Hypoxia: A key regulator of angiogenesis in cancer. *Cancer Metastasis Rev*. 2007; 26:281-290.
74. Yu XF, Han ZC. Matrix metalloproteinases in bone marrow: Roles of gelatinases in physiological hematopoiesis and hematopoietic malignancies. *Histol Histopathol*. 2006; 21:519-531.
75. Fingleton B. Matrix metalloproteinases as valid clinical targets. *Curr Pharm Des*. 2007; 13:333-346.
76. Ke Q, Costa M. Hypoxia-inducible factor-1 (HIF-1). *Mol Pharmacol*. 2006; 70:1469-1480.
77. Torii S, Goto Y, Ishizawa T, Hoshi H, Goryo K, Yasumoto K, Fukumura H, Sogawa K. Pro-apoptotic activity of inhibitory PAS domain protein (IPAS), a negative regulator of HIF-1, through binding to pro-survival Bcl-2 family proteins. *Cell Death Differ*. 2011; 18:1711-1725.
78. Ivan M, Kondo K, Yang H, Kim W, Valiando J, Ohh M, Salic A, Asara JM, Lane WS, Kaelin WG, Jr. HIF1alpha targeted for VHL-mediated destruction by proline hydroxylation: Implications for O2 sensing. *Science*. 2001; 292:464-468.
79. Willam C, Warnecke C, Schefold JC, Kugler J, Koehne P, Frei U, Wiesener M, Eckardt KU. Inconsistent effects of acidosis on HIF-alpha protein and its target genes. *Pflugers Arch*. 2006; 451:534-543.
80. Hirota K, Semenza GL. Regulation of angiogenesis by hypoxia-inducible factor 1. *Crit Rev Oncol Hematol*. 2006; 59:15-26.
81. Huang Y, Du KM, Xue ZH, Yan H, Li D, Liu W, Chen Z, Zhao Q, Tong JH, Zhu YS, Chen GQ. Cobalt chloride and low oxygen tension trigger differentiation of acute myeloid leukemic cells: Possible mediation of hypoxia-inducible factor-1alpha. *Leukemia*. 2003; 17:2065-2073.
82. Chen GQ, Peng ZG, Liu W, Song LP, Jiang Y, Huang Y, Zhao Q. Hypoxia inducible factor-1alpha and leukemic cell differentiation. *Sheng li xue bao : [Acta physiologica Sinica]*. 2006; 58:5-13.
83. Hanahan D, Weinberg RA. Hallmarks of cancer: The next generation. *Cell*. 2011; 144:646-674.
84. Hatfield KJ, Bedringsaas SL, Rynningen A, Gjertsen BT, Bruserud O. Hypoxia increases HIF-1alpha expression and constitutive cytokine release by primary human acute myeloid leukaemia cells. *Eur Cytokine Netw*. 2010; 21:154-164.
85. Song LP, Zhang J, Wu SF, Huang Y, Zhao Q, Cao JP, Wu YL, Wang LS, Chen GQ. Hypoxia-inducible factor-1alpha-induced differentiation of myeloid leukemic cells is its transcriptional activity independent. *Oncogene*. 2008; 27:519-527.
86. He M, Wang QY, Yin QQ, Tang J, Lu Y, Zhou CX, Duan CW, Hong DL, Tanaka T, Chen GQ, Zhao Q. HIF-1alpha downregulates miR-17/20a directly targeting p21 and STAT3: A role in myeloid leukemic cell differentiation. *Cell Death Differ*. 2013; 20:408-418.
87. Semenza GL. Evaluation of HIF-1 inhibitors as anticancer agents. *Drug Discov Today*. 2007; 12:853-859.
88. Frolova O, Samudio I, Benito JM, *et al*. Regulation of HIF-1alpha signaling and chemoresistance in acute lymphocytic leukemia under hypoxic conditions of the bone marrow microenvironment. *Cancer Biol Ther*. 2012; 13:858-870.
89. Katoh Y, Katoh M. Comparative integromics on Angiopoietin family members. *Int J Mol Med*. 2006; 17:1145-1149.
90. Kawaguchi M, Sugaya M, Suga H, Miyagaki T, Ohmatsu H, Fujita H, Asano Y, Tada Y, Kadono T, Sato S. Serum levels of angiopoietin-2, but not angiopoietin-1, are elevated in patients with erythrodermic cutaneous T-cell lymphoma. *Acta Derm Venereol*. 2014; 94:9-13.
91. Yu X, Seegar TC, Dalton AC, Tzvetkova-Robev D, Goldgur Y, Rajashankar KR, Nikolov DB, Barton WA. Structural basis for angiopoietin-1-mediated signaling

- initiation. *Proc Natl Acad Sci U S A*. 2013; 110:7205-7210.
92. Moss A. The angiopoietin:Tie 2 interaction: A potential target for future therapies in human vascular disease. *Cytokine Growth Factor Rev*. 2013; 24:579-592.
 93. Maffei R, Martinelli S, Castelli I, Santachiara R, Zucchini P, Fontana M, Fiorcari S, Bonacorsi G, Ilariucci F, Torelli G, Marasca R. Increased angiogenesis induced by chronic lymphocytic leukemia B cells is mediated by leukemia-derived Ang2 and VEGF. *Leukemia research*. 2010; 34:312-321.
 94. Saito M, Watanabe J, Fujisawa T, Kamata Y, Nishimura Y, Arai T, Miyamoto T, Obokata A, Kuramoto H. Angiopoietin-1, 2 and Tie2 expressions in endometrial adenocarcinoma--the Ang2 dominant balance up-regulates tumor angiogenesis in the presence of VEGF. *Eur J Gynaecol Oncol*. 2006; 27:129-134.
 95. Thiagarajan N, Acharya KR. Crystal structure of human angiogenin with an engineered loop exhibits conformational flexibility at the functional regions of the molecule. *FEBS Open Bio*. 2013; 3:65-70.
 96. Gao X, Xu Z. Mechanisms of action of angiogenin. *Acta Biochim Biophys Sin (Shanghai)*. 2008;40:619-624.
 97. Martinelli S, Kanduri M, Maffei R, Fiorcari S, Bulgarelli J, Marasca R, Rosenquist R. ANGPT2 promoter methylation is strongly associated with gene expression and prognosis in chronic lymphocytic leukemia. *Epigenetics*. 2013; 8:720-729.
 98. Maffei R, Martinelli S, Santachiara R, *et al*. Angiopoietin-2 plasma dosage predicts time to first treatment and overall survival in chronic lymphocytic leukemia. *Blood*. 2010; 116:584-592.
 99. Pavlov N, Badet J. (Angiogenin: Involvement in angiogenesis and tumour growth). *Bull Cancer*. 2001; 88:725-732.
 100. Cheng CL, Hou HA, Jhuang JY, *et al*. High bone marrow angiopoietin-1 expression is an independent poor prognostic factor for survival in patients with myelodysplastic syndromes. *Br J Cancer*. 2011; 105:975-982.
 101. Hatfield KJ, Hovland R, Oyan AM, Kalland KH, Rynningen A, Gjertsen BT, Bruserud O. Release of angiopoietin-1 by primary human acute myelogenous leukemia cells is associated with mutations of nucleophosmin, increased by bone marrow stromal cells and possibly antagonized by high systemic angiopoietin-2 levels. *Leukemia*. 2008; 22:287-293.
 102. Gospodarowicz D. Localisation of a fibroblast growth factor and its effect alone and with hydrocortisone on 3T3 cell growth. *Nature*. 1974; 249:123-127.
 103. Bryan BA, Walshe TE, Mitchell DC, Havumaki JS, Saint-Geniez M, Maharaj AS, Maldonado AE, D'Amore PA. Coordinated vascular endothelial growth factor expression and signaling during skeletal myogenic differentiation. *Molecular biology of the cell*. 2008; 19:994-1006.
 104. Rapraeger AC, Krufka A, Olwin BB. Requirement of heparan sulfate for bFGF-mediated fibroblast growth and myoblast differentiation. *Science*. 1991; 252:1705-1708.
 105. Yayon A, Klagsbrun M, Esko JD, Leder P, Ornitz DM. Cell surface, heparin-like molecules are required for binding of basic fibroblast growth factor to its high affinity receptor. *Cell*. 1991; 64:841-848.
 106. Nakashio A, Fujita N, Tsuruo T. Topotecan inhibits VEGF- and bFGF-induced vascular endothelial cell migration *via* downregulation of the PI3K-Akt signaling pathway. *Int J Cancer*. 2002; 98:36-41.
 107. Presta M, Dell'Era P, Mitola S, Moroni E, Ronca R, Rusnati M. Fibroblast growth factor/fibroblast growth factor receptor system in angiogenesis. *Cytokine & growth factor reviews*. 2005; 16:159-178.
 108. Smolej L, Andrys C, Maisnar V, Pour L, Maly J. Plasma concentrations of vascular endothelial growth factor and basic fibroblast growth factor in lymphoproliferative disorders. *Acta Medica (Hradec Kralove)*. 2005; 48:57-58.
 109. Cao R, Brakenhielm E, Pawliuk R, Wariaro D, Post MJ, Wahlberg E, Leboulch P, Cao Y. Angiogenic synergism, vascular stability and improvement of hind-limb ischemia by a combination of PDGF-BB and FGF-2. *Nature medicine*. 2003; 9:604-613.
 110. Traer E, Javidi-Sharifi N, Agarwal A, Dunlap J, English I, Martinez J, Tyner JW, Wong M, Druker BJ. Ponatinib overcomes FGF2-mediated resistance in CML patients without kinase domain mutations. *Blood*. 2014; 123:1516-1524.

(Received December 24, 2015; Revised January 12, 2016; Accepted January 17, 2016)

Insulin-driven translational capacity is impaired in primary fibroblasts of Prader Willi

Cristiana Meneghello, Daniela Segat, Elisabetta Fortunati*

"Mauro Baschirotto" Institute for Rare Diseases - B.I.R.D., Vicenza. Italy.

Summary

Prader-Willi (PW) syndrome is a rare genetic disorder characterized by hypothalamic-pituitary abnormalities and severe hypotonia, hyperphagia, behavioural and psychiatric problems. Absence of satiety leads to severe obesity and frequently to diabetes. Furthermore, adult patients suffer from a severe loss of muscle mass, which severely impacts their quality of life. The mechanisms underlying alterations in muscle growth in PW remain to be clarified. In this study we explored the hypothesis that, in PW cells, alterations of protein synthesis are determined by dysfunctions in the promotion of cell growth. In order to study the molecular changes leading to dysfunction in protein translation, primary fibroblasts derived from four PW patients and five control subjects were used to study the insulin-mediated signaling pathway implicated in the control of protein synthesis by immunoblotting. Here we present, for the first time, evidences that the protein translation response to insulin is impaired in PW fibroblasts. Insulin alone has a major upregulatory effect on protein kinase B (AKT), glycogen synthase kinase (GSK3beta), while phosphorylation of p70S6K1 protein elongation factor controlled by mammalian target of rapamycin complex I (mTORC1) is reduced. In addition, we provide data that the response to insulin in PW cells can be restored by previous treatment with the amino acid L-Leucine (L-Leu). Our experiments in primary cell cultures demonstrate an impairment of insulin signaling that can be rescued by supplementation with the branched aminoacid L-Leu, indicating a possible therapeutic approach for alleviating muscle mass loss in PW patients.

Keywords: Prader Willi Syndrome, protein synthesis, primary fibroblasts, p70-kDa S6 protein kinase, L-Leucine

1. Introduction

Prader-Willi (PW) syndrome is a complex neurogenetic disorder caused by the lack of expression of genes located on paternal chromosome 15q11-q13. It is characterized by severe obesity, mild to severe mental retardation and hypotonia. Muscle hypotonia and weakness is present during the neonatal stage and in childhood. It improves with time but adults remain mildly hypotonic with a decreased muscle mass (1). As consequence, patients show an altered motor performance, abnormal gait pattern and overall

a decreased physical activity that it is considered to contribute to overweight and frailty. Physical rehabilitation is commonly used to improve skeletal mass performance and to control obesity of adult PW patients. A retrospective analysis of a PW patient cohort, trained at our institute, showed that intense physical exercise programs have beneficial effects on body weight, but do not improve muscle mass of patients, despite normal calories intake (2). Our data suggested that the regulation of muscle mass was defective in PW patients.

Atrophy is a complex physiological process in which wasting or decreasing in size of tissues or organs undermine their functions. Various cells and tissues, including muscles, undergo atrophy in response to factors such ageing (sarcopenia), disuse, in fasting or disease states such as cancer cachexia, diabetes (3), obesity (4). The extent of cell atrophy is determined, at least in part, by changes in cell capacity of promoting

Released online in J-STAGE as advance publication December 14, 2015.

*Address correspondence to:

Dr. Elisabetta Fortunati, "Mauro Baschirotto" Institute for Rare Diseases - B.I.R.D., 36023 Costozza di Longare, Vicenza. Italy.
E-mail: elisabetta.fortunati@birdfoundation.org

cell growth through the modulation of the protein synthesis process. The mammalian target of rapamycin complex 1 (mTORC1) is the key regulator of initiation and elongation of mRNA translation in response to diverse upstream signals including insulin (and other growth factors), amino acids and energy availability (5). The insulin signaling pathway sequentially involves the insulin receptor substrate-1 and -2 (IRS-1 and -2), phosphatidylinositol (PI) 3-kinase, and protein kinase B (PKB), also known as protein kinase B (AKT), that regulates the mTORC1 activity and the downstream effectors: the p70-kDa S6 protein kinase (p70S6K1) and the eukaryotic initiation factor 4E-binding protein (4E-BP1) (6). Both proteins modulate translation initiation, by controlling the binding of mRNA to the 40S ribosomal subunit (7).

mTORC1 can also be activated independently by branched-chain amino acids such as L-Leucine (L-Leu), through an inside-out mechanism recently described (8), where leucyl-tRNA synthetase is identified as the intracellular sensor for amino acid signaling to mTORC1 (9). The stimulatory effects of L-Leu on protein synthesis have been recorded in several model systems and it is known to interact with insulin signaling pathway by modulating its phosphorylation events (10). The key role of mTORC1 in muscular trophism has been shown in several mouse models where the specific ablation of mTOR or Rictor induced specifically in the muscle, resulted in progressive dystrophic phenotypes (11). Furthermore, some evidences in humans suggest that mTORC1 and p70S6K1 protein expression (12) or phosphorylation status (13) is reduced in muscles from sarcopenic individuals, underlying the importance of the signaling through mTORC1 in the metabolic regulation of cell atrophy.

At present there are no evidences of the existence of molecular dysfunctions leading to PW cell wasting, or the role of protein translation in PW's muscle loss. Giving the hypothesis that cell atrophy is associated with alterations in protein synthesis, we wanted to verify the protein synthesis activity in response to insulin in PW cells and, if altered, whether stimulation of mTORC1 by L-Leu might rescue the associated defect.

In order to circumvent possible health complications arising from muscle biopsies taken from patients, and in absence of suitable muscle models for our exploratory investigations, we decided to use skin fibroblasts from PW individuals, hoping that the supposed alterations would be maintained in this type of cells.

In this report, we show for the first time, evidences that the protein synthesis response to insulin is impaired in PW primary fibroblasts, and that L-Leu treatment restores the defective response. Our data support the therapeutic potential of the mTORC1 stimulation in Prader Willi disease.

2. Materials and Methods

2.1. Human primary cell cultures

Human primary skin cells were obtained from 4 adult patients with a clinical diagnosis of PW syndrome established by fluorescent in situ hybridization and DNA methylation-specific PCR assay. All analysed patients showed deletions in chromosome 15q11-q13. Informed written consent was obtained from each subject before participation in the study, after the nature, purpose and risks of the study were explained. All experimental procedures involved in this study were formally approved by the Research Ethics Committee of the Foundation. Primary cell lines used in this study were established starting from sterile, non-necrotic biopsy samples, taken from the forearm of PW patients and directly transported in laboratory facilities in 50 ml tubes containing culture medium supplemented with antimycotic (fungizone, Sigma-Aldrich, St. Louis, MO, USA) and a double concentration of antibiotics (pen/strep, Sigma-Aldrich, St. Louis, MO, USA). Skin punches were then thoroughly washed with PBS and tissue was mechanically fragmented into 1-2 mm in size. The fragments were distributed in 24-well plates and grown in Chang culture medium (Irvine scientific CA, USA) containing 30% foetal bovine serum (FBS, Thermo Fisher Scientific Waltham, Ma, USA), antibiotic-antimycotic solution (1X), L-glutamine (2 mM). After 72 h, the extent of tissue adhesion and cell growth was assessed using phase-contrast microscopy. Subsequently tissue fragments were removed and primary cells were expanded in Chang medium supplemented with 10%FBS until freezing. Control fibroblasts were obtained at surgery from the neck or arm skin of 5 control subjects. Biopsies were processed as described above and the primary fibroblasts isolated from skin tissue were used as controls. Primary cells maintained the proliferative capacity with a doubling time of 24h for more than 15 passages. Cells between passages 3 and 15 were used for experiments. Cells were routinely tested for Mycoplasma contamination and for senescence by the senescence-associated β galactosidase assay (14).

2.2. Insulin, Serum and L-Leu stimulation experiments

Human control and PW fibroblasts were seeded one day before at 0.15×10^6 cells in Chang medium containing 10% FBS. Cells were thoroughly washed with PBS and incubated with 20% serum containing medium or deprived of serum for 2h prior to exposure to 100 nM insulin (Sigma-Aldrich, St. Louis, MO, USA) for 15 min. In the experiments with L-Leu (Sigma-Aldrich, St. Louis, MO, USA), serum deprived cells were pre-incubated with L-Leu for one hour and then stimulated with 100 nM insulin for additional 15 min. We used

a 100 nM concentration because it represents a well-accepted level of insulin stimulation in cell cultures commonly found in the literature (10). At the end of the treatment, cells were washed twice with cold PBS and cells were lysed. Total proteins were extracted as indicated in the immunoblotting paragraph. Each experiment was repeated at least three times including cell cultures, in order to have available biological replicates. Measurements of each biological replicate were repeated in a number of 3 technical replicates, performed on different blots.

2.3. Immunoblotting

Cells were lysed with a buffer containing 50 mM Tris-HCl, 0.5% NP40, 150 mM NaCl, 1 mM EDTA, 1 mM PMSF and proteases inhibitors (Cocktail set II, Calbiochem, Merck, Darmstadt, Germany). After centrifugation at 12000xg at 4°C for 15 min, supernatants were removed and total protein concentration was measured using the QuantiPro™ BCA Assay (Sigma-Aldrich, St. Louis MO, USA). 40 µg of protein homogenates were run on 10% SDS polyacrylamide gels and transferred onto a polyvinylidene fluoride membrane (PVDF, Bio-Rad Laboratories, Carlsbad, CA, USA) using a semi dry system Trans-blot apparatus. Even transfer of proteins on membranes was evaluated by Ponceau S (Sigma-Aldrich, St. Louis MO, USA) according to the manufacturing protocol. Membranes were then incubated in Tris-buffered saline (pH 7.5) containing 5% BSA and 0.1% tween-20 (TBST buffer) for 1 h at room temperature. The following phospho-specific antibodies were added and incubated overnight at 4°C in blocking buffer: p70S6K Thr389, GSK3betaSer9 (Cell Signaling Technology, Danvers, MA, USA) and AKTSer473 (Santa Cruz Biotechnology, Inc., Santa Cruz, CA, USA). Membranes were subsequently washed and incubated with anti-rabbit HRP-conjugated secondary antibody (1:10000; EDM Millipore) for 1 h at room temperature. Following this, membranes were washed repeatedly as before, and immune complexes were visualised on films, (Kodak, Sigma-Aldrich, St. Louis MO, USA) using enhanced chemiluminescence solution (Supersignal West Pico, Pierce, Thermo Fisher Scientific Waltham, Ma, USA). For normalisation, blots were mild stripped and then subsequently reprobed for total p70S6K, total GSK3beta, and AKT proteins to verify the relative amount of analysed proteins. Scanned images of photographic films were produced on a flatbed scanner and the intensity of the bands was quantified using ImageJ open source software (<http://rsb.info.nih.gov/ij/index.html>). Images were adjusted in size and brightness, and backgrounds removed by using the "rolling ball" algorithm and transformed to bright background with dark protein bands. Intensity of bands was measured as optical density (O.D.) units

by using a calibrated tablet with a density range of 0.05 to 3.05 O.D. In addition, for comparison between different blots, the phosphorylated fraction of kinases was corrected for the total fraction of the protein.

2.4. Protein synthesis measured by the Surface Sensing of Translation

A recent developed method, known as surface sensing of translation (SUnSET) allows the measurement of protein synthesis *in vitro* and *in vivo* (15,16). This non-radioactive technique involves the use of puromycin, a structural analog of tyrosyl-tRNA, and of an anti-puromycin antibody for the detection of nascent puromycin-labelled peptides by Western blot. Briefly, primary PW fibroblasts and control cells were cultured on 6-well dishes in Chang medium supplemented with 10%FBS. Upon confluence, cells have been switched to serum free Dulbecco's modified Eagle's medium (DMEM, Thermo Fisher Scientific, Waltham, Ma, USA) for 16 h. The medium was then replaced with fresh medium with or without 100 nM insulin for 60 min. Subsequently, 1 µM Puromycin (Merck, Darmstadt, Germany) was added to all wells for an additional 30 min. Cells were then lysed and total proteins were subjected to western blot. For the detection of puromycin-conjugated peptides, PVDF membranes were incubated overnight at 4°C with a mouse IgG2a monoclonal anti-puromycin antibody (clone 12D10, 1:5000, Merck, Darmstadt, Germany) dissolved in TBST containing 1% BSA. After several washes, membranes were incubated for 1 h at room temperature in 5% milk-TBST containing horseradish peroxidase conjugated anti-mouse IgG Fc 2a antibody (1:50,000 Jackson ImmunoResearch Laboratories Inc., West Grove, PA, USA). The immune complexes were visualized by enhanced chemiluminescence solution. After the capture of relevant images on photographic films the PVDF membranes were stained with Coomassie Blue to verify equal loading of proteins. The rate of protein synthesis was calculated by determining the intensity of each whole lane (incorporating the entire molecular weight range of puromycin-labeled peptides) of the three replicate samples and by correcting for total protein intensity measured on PVDF stained membranes using the ImageJ software. Experiments were performed in triplicates and data are expressed as arbitrary units (a.u.).

2.5. Statistics

All analyses were performed by the statistical package SPSS, v.16.0 (SPSS Inc., Chicago, IL, USA). Student *t*-test and one-way analysis of variance assay were used for comparison of untreated and stimulated conditions in control and PW cells. A *p* value of *p* < 0.05 was accepted as the statistically significant.

3. Results

3.1. PW cells do not increase protein synthesis in response to insulin

Skin fibroblasts from PW patients were used as cellular model for the verification of possible dysfunctions in the regulation of protein synthesis. Insulin and its related growth factors, has been shown to stimulate protein synthesis in a variety of cells in culture (17). Hence, we measured the insulin capacity of promoting protein synthesis in PW cells, using the non-radioactive SUnSET method. This technique quantifies the puromycin-labeled peptides by immunodetection, as measurement of global protein synthesis (15). Fibroblasts from control and patients were serum deprived for an overnight and stimulated for 1h with insulin, followed by 30 min incubation with puromycin. The translation activity recorded in 5 independent control samples increased significantly after exposure to insulin (5260 a.u. \pm 972 vs. stimulated cells 8205

a.u. \pm 193, $p < 0.05$), whereas the rate of puromycin incorporation was unaltered in skin fibroblasts derived from 4 PW individuals (6933 a.u. \pm 862 vs. stimulated cells 6134 a.u. \pm 193, $p = 0.43$) (Figure 1 C and 1D). We measured no significant difference between PWs and controls in the rate of protein translation at baseline (without serum), although the puromycin incorporation was 25% higher in patients compared to controls (compare Figure 1 A and 1B, Puro panels). We conclude that protein synthesis is unresponsive to insulin in PW fibroblasts.

3.2. PW fibroblasts do not activate p70S6K1 after insulin treatment

In order to gain insight into the changes of the insulin signaling pathway occurring in PW cells and responsible of the observed reduction of protein synthesis, we monitored the main phosphorylation events on pivotal kinases. Initially, we analyzed the activity of AKT/PKB in consideration of its central role as mediator of insulin signaling (18). Subsequently we focused on the action of active AKT/PKB that promotes initiation of protein translation (17) by phosphorylating the GSK3beta. As last, we considered the effects of AKT/PKB activation on mTORC1, which in turns regulates p70S6K1, leading to an increased protein elongation during protein synthesis. The phosphorylation profile of these 3 kinases was determined after exposure to 20% serum or to insulin

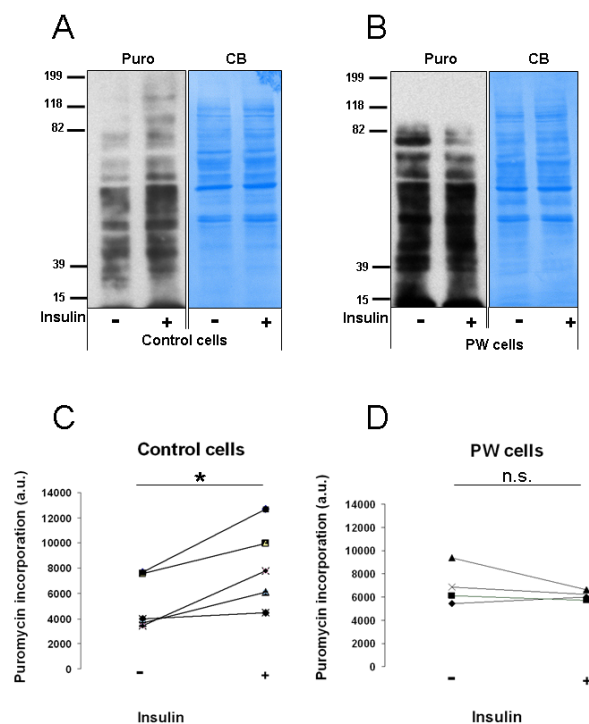


Figure 1. Insulin fails to stimulate protein synthesis in PW cells. A non-radioactive assay (SUnSet test) was used to evaluate protein synthesis in 5 controls and 4 PW-derived fibroblasts. Primary cells were serum deprived for 16 h. The medium was then replaced with fresh serum-free DMEM with (+) or without (-) 100 nM insulin for 1h and the incorporation of puromycin-labeled peptides was determined as described in materials and methods. (A) and (B): Representative images of WB analysis for puromycin (Puro) - and Coomassie Blue staining (CB) to verify equal loading of proteins - in Controls (A) and PW cells (B). (C) and (D): Quantification of protein translation in response to insulin is expressed as arbitrary units (a.u.) and it is shown in panel (C) (Controls $n = 5$) and (D) (PW cells $n = 4$). Each data points are the mean of experiments conducted in triplicates. Data reported are means \pm SEM. The statistical significance level was set at $p < 0.05$ (*); n.s. non significant.

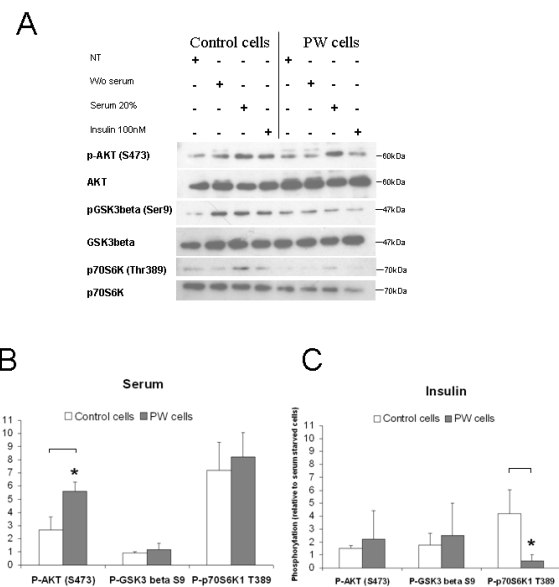


Figure 2. Insulin activates AKT but not p70S6K1. (A): Representative Western blots of PW and control cells for pAKT S473 and total AKT, pGSK3betaS9 and total GSK3beta, p70S6K1T389 and total p70S6K1, after exposure to 20% serum or to 100 nM Insulin. NT, Not treated; W/o serum, without serum. (B) and (C): Phosphorylation profile obtained by densitometric quantification of the effects of insulin and serum respectively. Data are means \pm SEM ($n = 3$). The statistical significance level was set at $p < 0.05$ (*). Open bars, control cells; solid bar, PW cells.

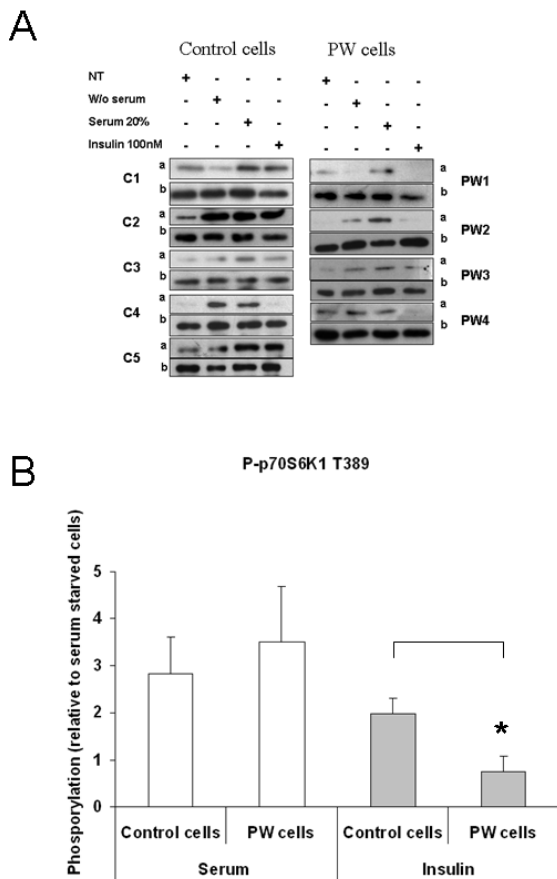


Figure 3. PW cells show low p70S6K1 activation in response to insulin. (A): Representative blots of the expression level of p70S6K1 T389 (a) and total p70S6K1 (b), after treatment with 20% serum or insulin of controls (C1-5) and patients (PW1-4). NT, Not treated cells; W/o serum, without serum. (B): Densitometric quantification of the effects of treatments on the analyzed cells. Open bars, serum stimulation; solid bar, Insulin stimulation. Data reported are means \pm SEM. The statistical significance level was set at $p < 0.05$ (*).

(Figure 2). Serum increased the phosphorylation of all 3 kinases, with a significant upregulatory effect on AKT/PKB in patient compared to control cells (Figure 2A and 2B). Likewise, insulin treatment induced a phosphorylation increment of AKT/PKB and GSK3 β , although to a less extent compared to serum. A substantial difference was recorded for the phosphorylation of p70S6K1 that was significantly higher in control and PW fibroblasts stimulated with serum while no insulin-mediated increase of p70S6K1 phosphorylation was observed in PW fibroblasts (Figure 2C).

To assess whether the dysfunctional insulin response is a feature of PW fibroblasts, we extended the analysis to 3 additional PW patients and 4 controls. The AKT/PKB phosphorylation profile resembles that one shown in Figure 2, confirming that insulin activates the AKT/PKB-mediated signaling in both control and patient groups (data not shown). By focusing on signaling downstream of AKT/PKB, we quantified the p70S6K1 phosphorylation in response to stimulations.

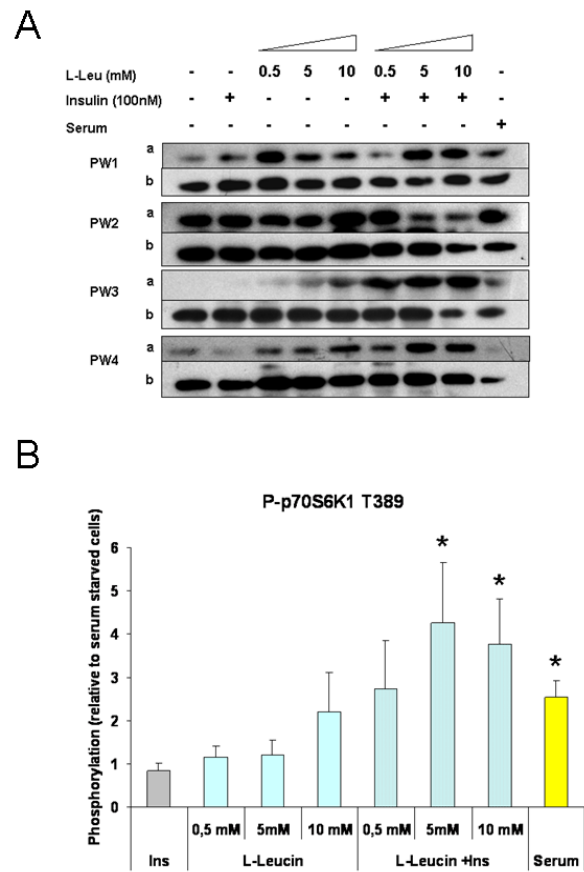


Figure 4. Leucine pretreatment augments insulin effect on p70S6K1 in PW cells. (A): Representative blots of the expression level of p70S6K1 T389 (a) and total p70S6K1 (b), after pre-treatment with L-Leu (0.5, 5, 10mM) alone or in combination with insulin (Ins, 100 nM) in PW cells (PW1-4). 20% serum stimulation was used as positive control (serum). (B): Densitometric quantification of the effects of stimuli on PW cells. Data are means \pm SEM. The statistical significance level was set at $p < 0.05$ (*).

All control fibroblasts showed an increment of the p70S6K1 phosphorylation at T389 following exposure to serum and four in five control samples to insulin. On the contrary, none of the four PW patients responded to insulin by increasing the p70S6K1 activation, while all responded to serum (Figure 3A and 3B). Overall, our data support the existence in PW cells of a dysfunctional protein translation response to insulin, mediated by AKT/mTORC1/p70S6K1 axis.

3.3. L-Leu pretreatment augments insulin effect on p70S6K1 signaling

Protein synthesis is stimulated by the availability of amino acids and energy (ATP). Besides their use as substrate for the building of polypeptide chains, the essential amino acids have been shown to directly activate the regulatory proteins of mRNA translation (19). Particularly interesting is the effect of the branched amino acid L-Leu, which enhances translation initiation and protein synthesis via induction

of the mTOR pathway (6,20,21) and activation of the downstream target p70S6K1. Therefore L-Leu is considered the main anabolic signal responsible for the increase of protein synthesis.

Since both L-Leu and insulin are known activators of p70S6K1, we wondered whether L-Leu could rescue the insulin-mediated p70S6K1 response in PW fibroblasts. The addition to serum deprived cells of 0.5, 5 or 10 mM L-Leu for 1h followed by 15 min insulin stimulation, resulted in a significant activation of p70S6K1 quantified in 2.7-folds at 0.5 mM, 4.2-folds at 5 mM and 3.7-folds at 10 mM (Figure 4 A and 4B). No significant effects on the kinase activity of L-Leu alone were detected, despite a slight improvement observed at 5 mM (1.2-folds) and at 10 mM (2.2-folds) L-Leu. These results suggest beneficial effects of L-Leu administration to PW cells and confirmed the role of L-Leu as modulator of the insulin signaling pathway and in particular of the protein translation via mTORC1.

4. Discussion

The regulation of protein synthesis by specific metabolic signaling pathways is crucial for normal cell growth. In a patient cohort trained at our institute we observed that muscular mass did not increase after training in a normal dietary regimen (2). Muscle mass loss in PW patients has been pointed out by others (1,22) and contributes to alterations in motor performance that leads to obesity and severe disabilities. The causes of muscle weakness, and motor problems in PW patients are not clear. In this paper we explored the possibility that muscle mass loss at cellular level may be caused by alteration in protein translation, impairing cellular growth. Our hypothesis was tested on skin primary fibroblasts of control and PW group exposed to growth stimuli. As mentioned earlier, the choice of this model was determined by the absence of a suitable *in vitro* model for PW muscle, and by the risks associated with muscular biopsies for patients. Although we are aware of the limitations of this model, our data may represent a useful step forward in the comprehension of muscle atrophy in PW disease.

Our major finding is that the translation response to insulin is impaired in the PW group compared to controls (Figure 1). The baseline of translational activity in absence of serum was overall higher in diseased cells (Figure 1A and 1B, Puro panel), suggesting that their metabolic phenotype could be slightly more active compared to controls. Additionally, we recorded more variable response to insulin in control cells as evidenced by the lack of p70S6K1 activation in one of the control sample (Figure 3A, Control cells, C4a, Insulin 100nM). It may be possible that the variability of control group selected on the absence of apparent diseases and availability of biopsies, mirrors underestimated biological factors in few samples.

Nevertheless, we considered more appropriate to include all control samples in the statistical analysis. Overall our data showed a dysfunctional translation response in PW patients.

The analysis of the phosphorylation profile induced by serum showed no changes in the activation in diseased or control cells. On the contrary, the molecular analysis of the insulin mediated signaling pathway showed that while AKT/PKB and GSK3beta activity is unchanged (Figure 2), the phosphorylation of p70S6K1 is decreased in PW cells (Figure 2 and Figure 3). Since the AKT activity, as well as the downstream target GSK3beta, is comparable in PW and control fibroblasts, our data suggest that the dysfunction to insulin response resides in mTORC1/p70S6K1 axis. A further support to the existence of an alteration in the mTORC1/p70S6K1 signaling pathway is the rescue effect exerted by L-Leu treatment on Insulin mediated phosphorylation of p70S6K1 recorded in PW fibroblasts (Figure 4).

It is known that L-Leu is a modulator of the insulin activity in several *in vitro* and *in vivo* models (10,23) by regulating the mTORC1 activity. The mechanism by which L-Leu activates mTORC1 has been recently elucidated (8). According to this model, L-Leu stimulates mTORC1 activity in a manner that requires v-ATPase, the Ragulator and the Reg GTPase, and favours the translocation of mTORC1 to the membrane compartment of the lysosomes, where Rheb (small GTPase Ras homolog enriched in brain), phosphorylates mTORC1 activating it (Figure 5).

In our experimental settings, L-Leu alone shows slight effects of p70S6K1 phosphorylation, indicating that mTORC1 is not fully active (Figure 4). Since the magnitude and rate at which mTORC1 is activated by L-Leu is reduced in KO cells for Reg GTPase (8), it is tempting to speculate that dysregulation of RegGTPase, which binds to and recruits mTORC1 to lysosomes, might be the possible cause of the modest effects of L-Leu treatment.

Addition of insulin to L-Leu treated cells resulted in a significant enhancement of the p70S6K1 phosphorylation levels and therefore of mTORC1 activity (Figure 4). Insulin activates mTORC1 through AKT/PKB mediated phosphorylation of PRAS40 and TSC1/TSC2 complex, preventing their inhibitory effects on mTORC1 (24,25) and favours the docking of mTORC1 to lysosome where mTORC1 is activated by Rheb (Figure 5). It is conceivable that alterations of mTORC1 activation observed in PW fibroblasts are the result of pathological modifications in the interaction between mTORC1 and regulatory proteins, Rags, Rheb and PRAS40, induced by L-Leu or insulin.

Given the complexity of the mTORC1 pathway and the presence of feedback loops between components, further investigations are needed to establish the mechanisms underlying our observations. In addition we cannot exclude that other pathways in addition to

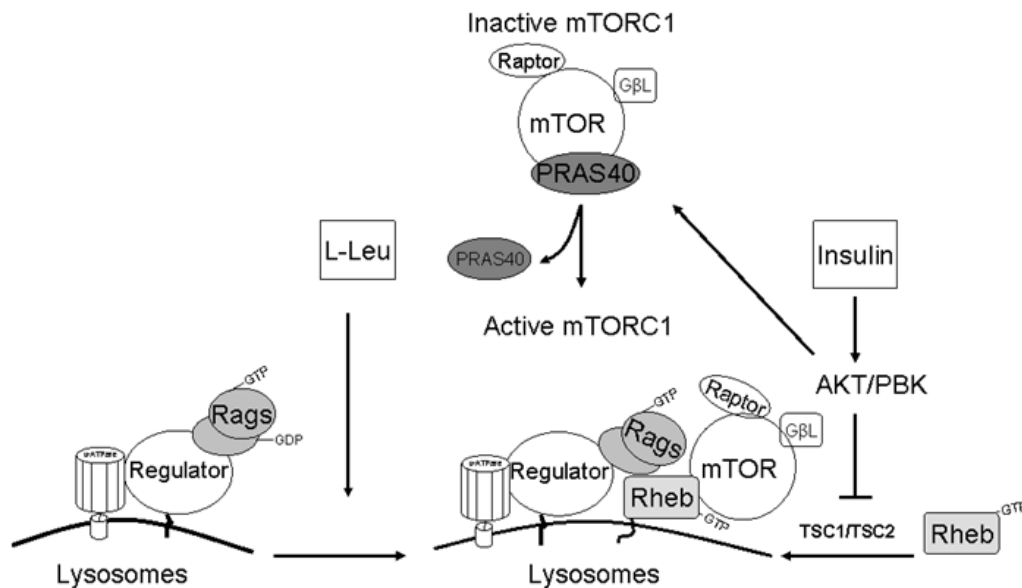


Figure 5. Critical regulatory proteins in leucin and insulin signaling to mTORC1. Protein translation is controlled by the activity of mTOR. L-Leu or insulin activates mTOR through Rag GTPase or Rheb GTPase, respectively. Insulin stimulation after pre-treatment with L-Leu favours the modulation of regulatory proteins such as raptor, PRAS40, Rheb, and the Rag GTPases that leads to increase protein stimulation in PW cells. Critical proteins are filled in grey. mTORC1 is composed of the serine/threonine protein kinase, mTOR, the regulatory associated protein of TOR, raptor, and the G-protein β -subunit like protein, G β L. PRAS40 (proline-rich Akt substrate of 40-kDa); TSC1/TSC2 (tuberous sclerosis complex 1 and 2); RagsGTPase (small guanosine triphosphatases).

mTORC1/p70S6k1 may play a role in the regulation of protein translation in response to growth factors. In this context p70S6K1 has emerged as a critical signaling component in the development of insulin resistance through phosphorylation and inhibition of insulin Receptor 1 and 2 functions (26).

The evidences reported in this manuscript were obtained from a limited number of patients, but they represent a good starting point for further investigations. Our data suggest a common dysfunction in the regulation mechanism of protein translation in response to insulin in PW fibroblasts. In addition, our *in vitro* data show a possible molecular link between alterations in protein synthesis *in vitro* and reduced muscle mass growth observed *in vivo* in PW patients (23).

We are aware that the results obtained with patient fibroblasts, cannot reproduce the complexities of what occurs in muscle cells *in vivo*. Therefore our findings must be further evaluated in different models such as patient muscle biopsies or PW reprogrammed fibroblasts differentiated into muscle cells. Nevertheless, patient-derived skin fibroblasts have been proven to be suitable disease models for studying phosphorylation events in response to growth factors because of their dependency to trophic signals. PW primary fibroblasts therefore must be regarded as a useful *in vitro* model for studying signal transduction.

In conclusion, in this study we showed for the first time that protein translation in response to insulin is dysfunctional in PW primary fibroblasts and it is associated with a decrease in P70S6K1 phosphorylation. Since protein synthesis regulation is

crucial for maintenance of cellular growth, our data support a molecular basis for the motor problems observed in PW patients. Finally we show that pre-incubation with the branched amino acid L-Leu can restore the insulin sensitivity suggesting its possible use in the treatment of muscle mass loss of PW patients.

Acknowledgements

This work was supported by a research grant from the Canadian Foundation for Prader Willi Research (FPWR) in 2013-2014 and co-founded by the Mauro Baschiroto Foundation for Rare Diseases.

References

1. Cassidy SB, Schwartz S, Miller JL, Driscoll DJ. Prader-Willi syndrome. *Genet Med.* 2011; 14:10-26.
2. Grolla E, Andrighetto G, Parmigiani P, Hladnik U, Ferrari G, Bernardelle R, Lago MD, Albarello A, Baschiroto G, Filippi G, Lovato R, Dolcetta D. Specific treatment of Prader-Willi syndrome through cyclical rehabilitation programmes. *Disabil Rehabil.* 2011; 33:1837-1847.
3. Krause MP, Riddell MC, Hawke TJ. Effects of type 1 diabetes mellitus on skeletal muscle: Clinical observations and physiological mechanisms. *Pediatr Diabetes.* 2011; 12:345-364.
4. Akhmedov D, Berdeaux R. The effects of obesity on skeletal muscle regeneration. *Front Physiol.* 2013; 4:371.
5. Laplante M, Sabatini DM. mTOR signaling in growth control and disease. *Cell.* 2012; 149:274-293.
6. Kimball SR, Shantz LM, Horetsky RL, Jefferson LS. Leucine regulates translation of specific mRNAs in

- L6 myoblasts through mTOR-mediated changes in availability of eIF4E and phosphorylation of ribosomal protein S6. *J Biol Chem.* 1999; 274:11647-11652.
7. Kimball SR, Farrell PA, Jefferson LS. Invited review: Role of insulin in translational control of protein synthesis in skeletal muscle by amino acids or exercise. *J Appl Physiol* (1985). 2002; 93:1168-1180.
 8. Jewell JL, Kim YC, Russell RC, Yu FX, Park HW, Plouffe SW, Tagliabracci VS, Guan KL. Metabolism. Differential regulation of mTORC1 by leucine and glutamine. *Science.* 2015; 347:194-198.
 9. Han JM, Jeong SJ, Park MC, Kim G, Kwon NH, Kim HK, Ha SH, Ryu SH, Kim S. Leucyl-tRNA synthetase is an intracellular leucine sensor for the mTORC1-signaling pathway. *Cell.* 2012; 149:410-424.
 10. Di Camillo B, Eduati F, Nair SK, Avogaro A, Toffolo GM. Leucine modulates dynamic phosphorylation events in insulin signaling pathway and enhances insulin-dependent glycogen synthesis in human skeletal muscle cells. *BMC Cell Biol.* 2014; 15:9.
 11. Risson V, Mazelin L, Roceri M, et al. Muscle inactivation of mTOR causes metabolic and dystrophin defects leading to severe myopathy. *J Cell Biol.* 2009; 187:859-874.
 12. Cuthbertson D, Smith K, Babraj J, Leese G, Waddell T, Atherton P, Wackerhage H, Taylor PM, Rennie MJ. Anabolic signaling deficits underlie amino acid resistance of wasting, aging muscle. *FASEB J.* 2005; 19:422-424.
 13. Li M, Verdijk LB, Sakamoto K, Ely B, van Loon LJ, Muijsers W. Reduced AMPK-ACC and mTOR signaling in muscle from older men, and effect of resistance exercise. *Mech Ageing Dev.* 2012; 133:655-664.
 14. Itahana K, Itahana Y, Dimri GP. Colorimetric detection of senescence-associated beta galactosidase. *Methods Mol Biol.* 2013; 965:143-156.
 15. Schmidt EK, Clavarino G, Ceppi M, Pierre P. SUnSET, a nonradioactive method to monitor protein synthesis. *Nat Methods.* 2009; 6:275-277.
 16. Goodman CA, Mabrey DM, Frey JW, Miu MH, Schmidt EK, Pierre P, Hornberger TA. Novel insights into the regulation of skeletal muscle protein synthesis as revealed by a new nonradioactive *in vivo* technique. *FASEB J.* 2011; 25:1028-1039.
 17. Proud CG. Regulation of protein synthesis by insulin. *Biochem Soc Trans.* 2006; 34:213-216.
 18. Lizcano JM, Alessi DR. The insulin signalling pathway. *Curr Biol.* 2002; 12:R236-R238.
 19. Norton LE, Layman DK. Leucine regulates translation initiation of protein synthesis in skeletal muscle after exercise. *J Nutr.* 2006; 136:533S-537S.
 20. Peyrollier K, Hajduch E, Blair AS, Hyde R, Hundal HS. L-leucine availability regulates phosphatidylinositol 3-kinase, p70 S6 kinase and glycogen synthase kinase-3 activity in L6 muscle cells: Evidence for the involvement of the mammalian target of rapamycin (mTOR) pathway in the L-leucine-induced up-regulation of system A amino acid transport. *Biochem J.* 2000; 350:361-368.
 21. Gran P, Cameron-Smith D. The actions of exogenous leucine on mTOR signalling and amino acid transporters in human myotubes. *BMC Physiol.* 2011; 11:10.
 22. Reus L, Zwarts M, van Vlimmeren LA, Willemsen MA, Otten BJ, Nijhuis-van der Sanden MW. Motor problems in prader-willi syndrome: A systematic review on body composition and neuromuscular functioning. *Neurosci Biobehav Rev.* 2011; 35:956-969.
 23. Zhang Y, Guo K, LeBlanc RE, Loh D, Schwartz GJ, Yu YH. Increasing dietary leucine intake reduces diet-induced obesity and improves glucose and cholesterol metabolism in mice via multimechanisms. *Diabetes.* 2007; 56:1647-1654.
 24. Sancak Y, Thorene CC, Peterson TR, Lindquist RA, Kang SA, Spooner E, Carr SA, Sabatini DM. PRAS40 is an insulin-regulated inhibitor of the mTORC1 protein kinase. *Mol Cell.* 2007; 25:903-915.
 25. Vander Haar E, Lee SI, Bandhakavi S, Griffin TJ, Kim DH. Insulin signalling to mTOR mediated by the Akt/PKB substrate PRAS40. *Nat Cell Biol.* 2007; 9:316-323.
 26. Tremblay F, Brûlé S, Hee Um S, Li Y, Masuda K, Roden M, Sun XJ, Krebs M, Polakiewicz RD, Thomas G, Marette A. Identification of IRS-1 ser-1101 as a target of S6K1 in nutrient- and obesity-induced insulin resistance. *Proc Natl Acad Sci U S A.* 2007; 104:14056-14061.

(Received October 22, 2015; Accepted November 30, 2015)

Importance of glucokinase -258G/A polymorphism in Asian Indians with post-transplant and type 2 diabetes mellitus

Imran Ali Khan^{1,2,3}, Kiran Kumar Vattam¹, Parveen Jahan³, Qurratulain Hasan^{1,2}, Pragna Rao^{4,*}

¹Department of Genetics and Molecular medicine, Kamineni Hospitals, Hyderabad, India;

²Department of Genetics, Vasavi Medical and Research Centre, Khairathabad, Hyderabad, India;

³Department of Genetics and Biotechnology, Osmania University, Tarnaka, Hyderabad, India;

⁴Department of Biochemistry, Kasturba Medical College, Manipal University, Manipal, Karnataka, India.

Summary

Type 2 diabetes mellitus (T2DM) and post-transplant diabetes mellitus (PTDM) are non-synonymous forms of diabetes. Glucokinase (GCK) plays a key role in glucose metabolism. The relationship between the *GCK* promoter and specific types of diabetes, such as PTDM and T2DM, in the Asian Indian population is unknown. We examined the occurrence of a specific *GCK* promoter variant (-258G/A) in patients with T2DM and PTDM. The case-control study enrolled 640 Asian Indian subjects, including controls ($n = 250$) and T2DM ($n = 250$), PTDM ($n = 42$), and non-post-transplant diabetes mellitus (non-PTDM) ($n = 98$) patients. Purified Deoxyribonucleic acid (DNA) was genotyped with the polymerase chain reaction (PCR) and restriction fragment length polymorphism (RFLP) analysis. The digested PCR products were analyzed on 12% polyacrylamide gels. The anthropometric, biochemical, and clinical details of each group were documented. *GCK* -258G/A alleles and genotypes were not associated with T2DM. However, among PTDM subjects, we detected a higher frequency of heterozygotes (52.4%) and a positive association with alleles/genotypes. The results suggest that the promoter region (-258G/A) of *GCK* plays an important role in PTDM in Asian Indians.

Keywords: GCK, -258G/A, T2DM, PTDM, Asian Indians

1. Introduction

Multifactorial metabolic disorders in humans include type 2 diabetes mellitus (T2DM) and post-transplant diabetes mellitus (PTDM), an irreversible form of diabetes that occurs in men and women. Impaired β -cell function and insulin resistance are key determinants of T2DM (1). The etiology of T2DM is thought to involve genetic and environmental factors, and the disease is characterized by decreased insulin secretion and insulin resistance (2). Hyperglycemia in the fasting state is one criterion that defines the disease; it can predict hard clinical endpoints in non-diabetic individuals, as well as in T2DM patients

when corrected (3). PTDM, also known as new-onset diabetes after transplantation (NODAT), is a frequent complication in renal transplant (RT) patients who receive immunosuppressive therapy with calcineurin inhibitors (4). Recipients with PTDM/NODAT and non-PTDM receive immunosuppressive drugs such as cyclosporine (CsA) and Tacrolimus (Tac) after renal transplantation and exhibit complications similar to those of T2DM patients in the general population, but with an accelerated rate of onset (5,6). Previous investigations have focused on candidate genes expressed in pancreatic β -cells that modulate insulin secretion and resistance and predispose individuals to PTDM and T2DM in later life. One such gene, glucokinase (*GCK*), encodes an enzyme in the glycolysis pathway that regulates glucose-stimulated insulin secretion from pancreatic β -cells and metabolizes glucose in the liver (7).

Hepatic *GCK* activity is closely and rapidly adapted by short and long term regulatory mechanisms. Peter *et al.* (8) group for the first time demonstrated the positive correlation between hepatic *GCK* expression and liver

Released online in J-STAGE as advance publication December 31, 2015.

*Address correspondence to:

Dr. Pragna Rao, Department of Biochemistry, Kasturba Medical College, Manipal University, Manipal-576104, Karnataka, India.

E-mail: drpragnarao@gmail.com

triglyceride content in humans. A reduction in GCK levels or activity in β -cells could increase the glucose threshold for insulin secretion, leading to atypical hyperglycaemic status (9). The *GCK* gene is located at chromosome 7p15.3 and has 12 exons (10). *GCK* genetic variants contribute to the risk of T2DM in men and women of different ethnicities, but their frequencies in Asian Indians with PTDM and T2DM have not been examined. There are no studies that have been carried out with -258G/A variants in the Indian population with any of these diseases. Hence, the current study investigated whether the -258G/A variant in the promoter region of *GCK* modifies the risk of T2DM and PTDM in Asian Indians with and without a family history of T2DM.

2. Materials and Methods

2.1. Ethical approval

The study was approved by the ethics committee of Kamineni Hospitals, Hyderabad, India (KHL No. e373/07). The participants signed written informed consent forms before enrolment.

2.2. Selection of subjects

For this study, we recruited 640 Asian Indian subjects: 250 subjects with T2DM, 250 healthy controls, 42 subjects with PTDM, and 98 subjects without PTDM (non-PTDM). The selection of T2DM subjects, controls, and PTDM subjects and the inclusion and exclusion criteria for the specific groups are described in previous publications (1,5,11). We collected 3 mL of serum for biochemical analysis and 2 mL of anticoagulated blood for mutational analysis. The anthropometric, biochemical, and clinical measurements for T2DM, PTDM, and non-PTDM cases and control subjects are described in our previous reports (1,5,11).

2.3. Mutational analysis

DNA was routinely purified at Kamineni Hospitals using a salting out procedure (12,13). The region 173 bp upstream of the *GCK* coding region was genotyped with polymerase chain reaction (PCR) and restriction fragment length polymorphism (RFLP) analysis. Primers were designed according to previous studies (14) and synthesized by BioServe Biotechnologies (Hyderabad, India). The amplified products were digested with the *AccI* restriction enzyme (GTG⁺TAC) for 2 hours, and the fragments were analyzed on 12% polyacrylamide gels stained with ethidium bromide (Figure 1).

2.4. Statistical analysis

Clinical data were expressed as the mean \pm standard deviation (SD). Differences in genotype and allele

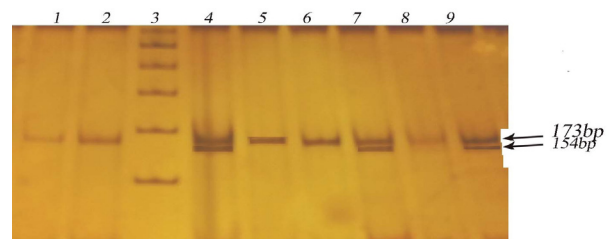


Figure 1: Digested products separated by 12% polyacrylamide gel electrophoresis for assessment of -258G/A *GCK* variants. Lane: 1, 2, 5, 6, 8 Homezygous GG 173bp; Lane: 3 Ladder (100bp); Lane: 4, 7, 9 Heterozygous GA 173/154bp.

frequencies were determined with the gene counting method for T2DM vs. controls and PTDM vs. non-PTDM subjects. An odds ratio (OR) with a 95% confidence interval (CI) was calculated for the -258G/A mutation. The chi-square (χ^2) test was used to compare expected and observed frequencies of categorical variables, at a significance level $p = 0.05$. The Yates correction was also used to analyze genotype frequencies. The Hardy-Weinberg equilibrium (HWE) was measured using the χ^2 test to assess goodness of fit (15). A value of $p < 0.05$ was considered to indicate a significant disequilibrium. Statistical calculations were performed with Openepi software.

3. Results

3.1. Baseline characteristics of T2DM patients and controls

The anthropometric, biochemical, and clinical characteristics of the study groups are shown in Table 1. The average age was 57.19 ± 8.22 years for T2DM patients and 53.93 ± 6.32 years for controls. The mean body mass index (BMI) was 27.5 ± 4.1 kg/m² for T2DM cases and 25.8 ± 3.9 kg/m² for controls. There were significant differences between T2DM patients and controls in the levels of fasting blood sugar, post-lunch blood sugar, triglycerides, HDL-C, and total cholesterol ($p < 0.05$). Gender, BMI, LDL-C, and family history were not significantly associated with T2DM ($p > 0.05$), although family history was closely associated with T2DM (58.4%).

3.2. Characteristics of the PTDM and non-PTDM subjects

The characteristics of the PTDM and non-PTDM subjects are given in Table 2. Biochemical tests were used to assess PTDM in 140 RT patients; 30% of RT recipients developed PTDM. The study included 42 patients diagnosed with PTDM and 98 patients diagnosed as non-PTDM subjects. The PTDM patient group contained 30 men and 12 women, with similar mean ages, 39.39 ± 2.12 and 40.01 ± 11.63 ,

Table 1. Clinical details of T2DM patients and the healthy controls

Characteristics	T2DM Cases (n = 250)	Healthy Controls (n = 250)	p value
Age (Years)	41-82 (57.19 ± 8.22)	41-60 (53.93 ± 6.32)	0.0003
Males/Females (%)	138 (55.2%)/112 (44.8%)	144 (57.6%)/106(42.4%)	0.3461
BMI (kg/m ²)	27.5 ± 4.1	25.8 ± 3.9	0.4306
T2DM Interval	13.1 ± 6.3	NA	NA
FBS (mg/dL)	143.61 ± 55.66	93.54 ± 12.13	0.0001
PPBG (mg/dL)	201.29 ± 25.25	117.29 ± 19.07	0.0001
TG (mg/dL)	156.42 ± 78.97	138.77 ± 53.69	0.0001
TC (mg/dL)	183.95 ± 51.54	175.06 ± 33.05	0.0001
HDL-C (mg/dL)	88.72 ± 23.1	82.61 ± 20.6	0.01
LDL-C (mg/dL)	38.76 ± 4.4	35.53 ± 4.1	0.2658
Family History, n (%)	146 (58.4%)	138 (55.2%)	0.3745

NA = Not Analyzed/ Not Applicable.

Table 2. Clinical characteristics of PTDM and non-PTDM subjects

Baseline characteristics	PTDM (n = 42)	non-PTDM (n = 98)	p value
Males / Females	0/12	75/23	0.001
Age:			
a) Males (Mean ± SD)	39.39 ± 12.12	39.55 ± 10.58	0.27
b) Females (Mean ± SD)	40.01 ± 11.63	39.26 ± 10.87	0.58
Weight:			
a) Males (Mean ± SD)	62.73 ± 15.81	66.03 ± 12.73	0.08
b) Females (Mean ± SD)	61.71 ± 16.93	65.49 ± 13.68	0.09
Therapy:			
a) On CsA therapy	22	58	0.01
b) On Tac therapy	20	40	0.02
Dose:			
a) CsA Dose (mg)	163.88 ± 57.4	201.29 ± 76.86	0.03
b) Tac Dose (mg)	3.15 ± 1.24	3.11 ± 1.62	0.05
Levels:			
a) C2 levels (ng/mL) CsA	750 ± 299.03	1024.8 ± 353.42	0.23
b) Trough levels (ng/mL) Tac	9.55 ± 3.38	8.0 ± 3.32	0.86
Levels:			
a) C2 levels/dose of CsA	5.24 ± 2.59	5.52 ± 1.97	0.02
b) Trough levels/dose of Tac	3.62 ± 1.96	2.98 ± 1.49	0.02

respectively. Of the 42 patients with PTDM, 22 (54%) were receiving cyclosporine A (CsA) treatment, whereas 20 (47.6%) were receiving tacrolimus (Tac). The mean age of the PTDM patients on the date of post-transplant blood sample collection was 20.4 ± 15.3 years. The t-test was performed between PTDM and non-PTDM subjects, gender, weight, subjects with cyclosporine drugs (*i.e.*, CsA, Tac) and along with the dosage were found statistically significant ($p < 0.05$).

3.3. Hardy-Weinberg Equilibrium

The distributions of the genotype frequencies of the -258G/A variants in case and control subjects were in accordance with the HWE (Table 3). The genotypic distribution of GCK variants and their allelic frequencies in the patients (T2DM and PTDM) and controls enrolled in this study are shown in Table 4.

3.4. Association of the -258G/A variant with T2DM and PTDM

The genotype and allele distributions in cases (T2DM

Table 3. Details of Hardy Weinberg equilibrium

Gene	Glucokinase
SNP ID	rs1799831
Chromosome	7p15.3
Position (Build36.3)	44,199,142
PMID	11112984
Organism	Homo sapiens
Alleles 1/2	G/A
Risk allele	A
T2DM genotypes (11/12/22)	246/04/00
PTDM genotypes (11/12/22)	20/22/00
Non-PTDM genotypes (11/12/22)	92/06/00
Control Genotypes (11/12/22)	248/02/00
Risk allele frequency (T/P*)	0.8/26.2
HWE (Chi square) (T/P*)	0.02/1.73
HWE (p value) (T/P*)	0.99/0.9

(T/P*) indicates T2DM/PTDM.

and PTDM) and controls (healthy controls and non-PTDM) are shown in Table 4. The genotype frequency of GG and GA was 98.4% and 1.6% in T2DM cases and 99.2% and 0.8% in controls, respectively. In the statistical analysis, we did not find any association

Table 4. Genotype and allele distribution of -258G/A GCK variants in all cases (T2DM and PTDM) and controls (healthy controls and non-PTDM)

GCK	T2DM (n = 250)	Controls (n = 250)	χ^2	Odds ratio ^{a,b} (95% CI)	p value
GG	246 (98.4%)	248 (99.2%)	Reference*	-	-
GA	04 (1.6%)	02 (0.8%)	0.67	2.0 (0.36, 11.1)	0.41
AA	00 (00)	00 (00)	0.001	1.0 (0.01-51)	0.31
GA+AA	04 (1.6%)	02 (0.8%)	0.57	1.8 (0.38, 8.6)	0.70
G	496 (99.2%)	498 (99.6%)	Reference*	-	-
A	04 (0.8%)	02 (0.4%)	0.67	2.0 (0.36, 11.0)	0.41
	PTDM (n = 42)	Non-PTDM (n = 98)	χ^2	Odds ratio ^{a,b} (95% CI)	p value
GG	20 (47.6%)	92 (93.9%)	Reference*	-	-
GA	22 (52.4%)	06 (6.1%)	39.04	16.8 (6.0, 46.9)	0.0001
AA	00 (00)*	00 (00)	0.66	4.5 (0.08, 234.1)	0.63
GA+AA	22 (52.4%)	06 (6.1%)	38.35	15.6 (5.7, 42.2)	0.0001
G	62 (0.74)	190 (0.97)	Reference*	-	-
A	22 (0.26)	06 (0.03)	34.83	11.2 (4.3, 28.9)	0.0001

^a Crude odds ratio (95 % CI); ^b odds ratio (95 % CI) Adjusted for Yates correction. *Reference indicated the normal allele/genotypes *i.e.* GG is normal/homozygous genotype and G allele is wild allele.

between alleles and genotypes (G vs. A: OR = 2.0 [95% CI: 0.36-11.0], $p = 0.41$; GA vs. GG: OR = 2.0 [95% CI: 0.36-11.1], $p = 0.41$). Statistically significant differences in allele and genotype frequencies were observed when PTDM and non-PTDM subjects were compared (G vs. A: OR = 11.2 [95% CI: 4.3-28.9], $p < 0.0001$; GA vs. GG: OR = 16.8 [95% CI: 6.0-46.9], $p < 0.0001$). The dominant model also showed a significant association (GA+AA vs. AA: OR = 15.6 [95% CI: 5.7-42.2], $p < 0.0001$).

4. Discussion

Gene identification is important for understanding the pathophysiology of disease and for improving diagnosis, prevention, and treatment (16). We performed a case-control study to evaluate the association between -258G/A GCK variants and PTDM and T2DM in the Asian Indian population. To our knowledge, this study is the first to find that alleles and genotypes are associated with an increased risk of PTDM ($p < 0.0001$). T2DM and PTDM are chronic disorders characterized by hyperglycemia, insulin resistance, and impaired insulin secretion due to pancreatic β -cell defects; the diseases have a strong genetic component (7). In India, 65.1 million adults have been diagnosed with T2DM (17). PTDM has become a serious health complication worldwide. Insulin is used to monitor glucose values for more than 6 months after transplantation, in PTDM subjects and lifelong without transplantation. In those with T2DM, the disease develops in the later thirties and early forties and progresses. Those with PTDM develop diabetes 3 months after RT and may later develop T2DM.

One of our goals was to investigate whether -258 G/A variants in the promoter region of GCK are associated with T2DM in the Asian Indian population. We compared T2DM cases with control subjects and found no significant differences in allele or genotype

frequencies. This was the first study carried out in this population. The discrepancy between the results of the present study (T2DM vs. controls) and those of Chinese studies can be attributed to the GCK gene in the Chinese population (18). Our study is consistent with three previous studies of T2DM in different races and ethnicities, which found that GCK was not associated with T2DM (19-21). Our results also showed that the -258G/A GCK variant had no significant effect on abnormal glucose levels in T2DM patients receiving noninsulin treatment. The extent to which the GCK promoter variants affect these traits might vary, possibly explaining the contrasting results. Mutations in GCK can alter the reaction. Some rare exonic mutations have been investigated previously, and the role of these mutations in the pathogenesis of reduced fetal growth and in adult insulin resistance has been established. GCK is associated with reduced β -cell function, impaired glucose tolerance, and T2DM (22). Yang *et al.* (23) performed a meta-analysis of the -30G>A GCK polymorphism in gestational diabetes mellitus (GDM) and T2DM and concluded that the A allele was a risk factor for GDM and T2DM among whites. Fu *et al.* (7) also performed meta-analysis studies of T2DM with 298,468 subjects, and the results agree with those of Yang *et al.* (23). Our study is not in agreement with these studies. The small sample size could be one reason.

In the comparison of PTDM vs. non-PTDM patients, promoter region variants were significantly associated with PTDM ($p < 0.0001$). Our results in PTDM subjects are in accordance with those from a study of a Korean population (24). In our study population, PTDM and GDM (unpublished data) were strongly associated with GCK. Given these results, we cannot conclude that mutations in GCK have no role in the Asian Indian population. The lack of any significant association between the variants and disease might be due to several

factors, including ethnicity, low sample size, and low statistical power. Of 640 subjects, none had the AA genotype, suggesting that the AA genotype is associated with disease development.

The current study has several limitations. Firstly, we enrolled a small number of PTDM ($n = 42$), and non-PTDM ($n = 98$) subjects. Secondly, only promoter region variants were selected. Thirdly, GDM data was excluded to strengthen the study. In addition, insulin levels were not measured. Finally, biochemical data for PTDM and non-PTDM subjects were not obtained. Our study suggests that large, unbiased epidemiological studies of genetic predisposition can provide insight into the *in vivo* relationship between candidate genes and diseases. The reproduction of genetic association studies can be problematic because of insufficient power, multiple hypothesis testing, population stratification, source of controls, publication bias, and phenotypic heterogeneity (25).

5. Discussion

The findings of this study indicate that PTDM has a strong genetic association with *GCK*. Our findings also indicate that the -258G/A variant in the promoter region of *GCK* is not an independent risk factor for the development of T2DM in Asian Indian subjects.

Acknowledgements

We are deeply thankful to Dr. Kamal Kiran Mukkavali, a nephrologist who assisted with the RT samples, and to Dr. Sireesha Movva, who assisted with the DNA samples for T2DM. We are grateful to ICMR for funding this work (Sanction no.5-3-8-39-2007; RHN).

References

1. Khan IA, Movva S, Shaik NA, Chava S, Jahan P, Mukkavali KK, Kamineni V, Hasan Q, Rao P. Investigation of Calpain 10 (rs2975760) gene polymorphism in Asian Indians with gestational diabetes mellitus. *Meta Gene*. 2014; 2:299-306.
2. Saitoh S, Shimoda T, Hamamoto Y, Nakaya Y, Nakajima S. Correlations among obesity-associated gene polymorphisms, body composition, and physical activity in patients with type 2 diabetes mellitus. *Indian J Endocrinol Metab*. 2015; 19:66-71.
3. Dupuis J, Langenberg C, Prokopenko I, *et al*. New genetic loci implicated in fasting glucose homeostasis and their impact on type 2 diabetes risk. *Nat Genet*. 2010; 42:105-116.
4. Tavira B, Gomez J, Diaz-Corte C, Llobet L, Ruiz-Pesini E, Ortega F, Coto E. Mitochondrial DNA haplogroups and risk of new-onset diabetes among tacrolimus-treated renal transplanted patients. *Gene*. 2014; 538:195-198.
5. Khan IA, Vattam KK, Jahan P, Mukkavali KK, Hasan Q, Rao P. Correlation between *KCNQ1* and *KCNJ11* gene polymorphisms and type 2 and post-transplant diabetes mellitus in the Asian Indian population. *Genes & Diseases*. 2015; 2:276-282.
6. Ghisdal L, Van Laecke S, Abramowicz MJ, Vanholder R, Abramowicz D. New-onset diabetes after renal transplantation: Risk assessment and management. *Diabetes Care*. 2012; 35:181-188.
7. Fu D, Cong X, Ma Y, Cai H, Cai M, Li D, Lv M, Yuan X, Huang Y, Lv Z. Genetic polymorphism of glucokinase on the risk of type 2 diabetes and impaired glucose regulation: Evidence based on 298,468 subjects. *PLoS One*. 2013; 8:e55727.
8. Peter A, Stefan N, Cegan A, Walenta M, Wagner S, Konigsrainer A, Königsrainer I, Machicao F, Schick F, Häring HU, Schleicher E. Hepatic glucokinase expression is associated with Lipogenesis and fatty livers in Humans. *J Clin Endocrinol Metab*. 2011; 96:E1126-E1130.
9. Naylor R, Philipson LH. Who should have genetic testing for maturity-onset diabetes of the young? *Clin Endocrinol (Oxf)*. 2011; 75:422-426.
10. Sotos-Prieto M, Luben R, Khaw KT, Wareham NJ, Forouhi NG. The association between Mediterranean Diet Score and glucokinase regulatory protein gene variation on the markers of cardiometabolic risk: An analysis in the European Prospective Investigation into Cancer (EPIC)-Norfolk study. *Br J Nutr*. 2014; 112:122-131.
11. Khan IA, Jahan P, Hasan Q, Rao P. Validation of the association of *TCF7L2* and *SLC30A8* gene polymorphisms with post-transplant diabetes mellitus in Asian Indian population. *Intractable Rare Dis Res*. 2015; 4:87-92.
12. Khan IA, Shaik NA, Kamineni V, Jahan P, Hasan Q, Rao P. Evaluation of gestational diabetes mellitus risk in south Indian women based on *MTHFR (C677T)* and *FVL (G1691A)* Mutations. *Front Pediatr*. 2015; 3:34.
13. Khan IA, Vasundhara K, Poornima S, Jahan P, Hasan Q, Rao P. Tumor necrosis factor alpha promoter polymorphism studies in pregnant women. *J Reprod Health Med*. 2015; 1:18-22.
14. Chiu KC, Chuang LM, Yoon C, Saad MF. Hepatic glucokinase promoter polymorphism is associated with hepatic insulin resistance in Asian Indians. *BMC Genet*. 2000; 1:2.
15. Rodriguez S, Gaunt TR, Day IN. Hardy-Weinberg equilibrium testing of biological ascertainment for Mendelian randomization studies. *Am J Epidemiol*. 2009; 169:505-514.
16. Butler, M, Bliss D, Drekonja D, Filice G, Rectar T, Mac Donald R, *et al*. Effectiveness of Early Diagnosis, Prevention, and Treatment of Clostridium difficile Infection. 2011; Report No.: 11(12)-EHC051-EF.
17. Saboo B, Reddy GC, Juneja S, Kedia AK, Manjrekar P, Rathod R, behalf of GLOBE Investigators. Effectiveness and safety of fixed dose combination of acarbose/metformin in Indian type 2 diabetes patients: Results from observational GLOBE Study. *Indian J Endocrinol Metab*. 2015; 19:129-135.
18. Liu Z, Deng H, Tang WL. Mutation of *GCK* gene of Chinese patients with late-onset type 2 diabetes. *Hunan Yi Ke Da Xue Xue Bao*. 2003; 28:99-101. (in Chinese)
19. Plengvidhya N, Boonyasrisawat W, Chongjaroen N, Jungtrakoon P, Sriussadaporn S, Vannaseang S, Banchuin N, Yenchitsomanus PT. Mutations of maturity-onset diabetes of the young (MODY) genes in Thais with

- early-onset type 2 diabetes mellitus. *Clin Endocrinol (Oxf)*. 2009; 70:847-853.
20. Holmkvist J, Almgren P, Lyssenko V, Lindgren CM, Eriksson KF, Isomaa B, Tuomi T, Nilsson P, Groop L. Common variants in maturity-onset diabetes of the young genes and future risk of type 2 diabetes. *Diabetes*. 2008; 57:1738-1744.
 21. Lukasova P, Vcelak J, Vankova M, Vejrazkova D, Andelova K, Bendlova B. Screening of mutations and polymorphisms in the glucokinase gene in Czech diabetic and healthy control populations. *Physiol Res*. 2008; 57:S99-S108.
 22. Marz W, Nauck M, Hoffmann MM, Nagel D, Boehm BO, Koenig W, Rothenbacher D, Winkelmann BR. G(-30)A polymorphism in the pancreatic promoter of the glucokinase gene associated with angiographic coronary artery disease and type 2 diabetes mellitus. *Circulation*. 2004; 109:2844-2849.
 23. Yang S, Du Q. Association of GCK -30G> a polymorphism with gestational diabetes mellitus and type 2 diabetes mellitus risk: A meta-analysis involving 18 case-control studies. *Genet Test Mol Biomarkers*. 2014; 18:289-298.
 24. Nam JH, Lee HC, Kim YH, Cha BS, Song YD, Lim SK, Kim KR, Huh KB. Identification of glucokinase mutation in subjects with post-renal transplantation diabetes mellitus. *Diabetes Res Clin Pract*. 2000; 50:169-176.
 25. Ni X, Zhang J. Association between 9p21 genomic markers and ischemic stroke risk: Evidence based on 21 studies. *PLoS One*. 2014; 9:e9025

(Received October 6, 2015; Revised December 7, 2015; Accepted December 14, 2015)

Using inpatient data to estimate the prevalence of Wegener's granulomatosis in China

Xiao Liu^{1,2,*}, Yazhou Cui^{1,2,*}, Yan Li^{1,2}, Chao Wang^{1,2}, Heng Zhao^{1,2}, Jinxiang Han^{1,2,**}

¹ Shandong Medicinal Biotechnology Center, Key Laboratory for Biotech Drugs of the Ministry of Health, Key Laboratory for Rare Diseases of Shandong Province, Shandong Academy of Medical Sciences, Ji'nan, Shandong, China;

² College of Life Science and Medicine, Ji'nan University, Shandong Academy of Medical Sciences, Ji'nan, Shandong, China.

Summary

China lacks a registry for most rare diseases, so specific epidemiological data on those diseases are lacking. A strategy involving the DISMOD II model was recently formulated to estimate the epidemiological parameters of rare diseases, and this strategy has been used to study several rare diseases. The current study used this strategy to estimate the prevalence of one such rare disease, Wegener's granulomatosis (WG), in China based on its incidence, mortality, and rate of remission according to the software tool DISMOD II. The incidence of WG was calculated based on inpatient data from 100 hospitals throughout China. The cause-specific mortality from WG was estimated based on data from the National Vital Statistics System of the United States and adjusted for the Chinese population. The rate of disease remission was based on the results of previous study. The current results indicated that the prevalence of WG in China is 1.94/100,000, which is slightly lower than that in Europe and the United States. The mean age at onset of WG in China was calculated to be 38.9 years for males and 39.3 years for females and the duration of disease was 28 years for both male and female patients. These figures are similar to published data from other countries. In conclusion, the DISMOD II model was used to estimate the prevalence of WG in China, providing a basis to evaluate the potential disease burden and orphan drug use by patients with WG. The DISMOD II model could be used to estimate the prevalence of other rare diseases.

Keywords: Wegener's granulomatosis, prevalence, rare diseases, DISMOD II, China

1. Introduction

Epidemiological data such as disease prevalence is particularly useful in establishing healthcare policies for patients with rare diseases. A conventional sampling approach in an epidemiological study is not suitable for rare diseases because of their extremely low incidence

rates. In developed countries such as the United States, patient registries are used to obtain key epidemiological data on rare diseases, but data on only some of those diseases are available. Compared to developed countries, China lacks rare disease registries. Therefore, epidemiological data on most rare diseases are lacking.

DISMOD II is a software tool that is widely used to check the consistency of estimates of incidence, prevalence, duration, and case fatality for different diseases (1). Recently, several studies have formulated a strategy of using DISMOD II to extrapolate the epidemiological parameters of several rare diseases. For example, Yang LP *et al.* (2) entered incidence, cause-specific mortality, and remission data into DISMOD II to evaluate the prevalence of scleroderma in Spain. Chung *et al.* (3) used DISMOD II to calculate the epidemiological parameters of multiple sclerosis in South Korea based on its prevalence, incidence, mortality, and duration of disease. Phanthunane *et al.* (4)

Released online in J-STAGE as advance publication February 1, 2016.

*These authors contributed equally to this works.

**Address correspondence to:

Dr. Jinxiang Han, Shandong Medicinal Biotechnology Center, Key Laboratory for Biotech Drugs of the Ministry of Health, Key Laboratory for Rare Diseases of Shandong Province, Shandong Academy of Medical Sciences, College of Life Science and Medicine, Ji'nan University, Shandong Academy of Medical Sciences, Ji'nan, Shandong 250062, China.
E-mail: samshjx@sina.com

determined the incidence and duration of schizophrenia based on its mortality, remission, and prevalence in Thailand.

Wegener's granulomatosis (WG) is a typical rare and life-threatening disease with chronic systemic vasculitis that mainly affects the lungs and kidneys (5). In patients with WG, the risk of death increases significantly as the disease progresses, making WG a significant public health problem (6). The estimated prevalence of WG in Europe ranges from 2.4/100,000 to 15.7/100,000 (7). In the United States, the prevalence of WG has been estimated to be approximately 2.6/100,000 (8), and in Iran the prevalence of WG is about 0.06/100,000 in children under the age of 15 (9). However, the prevalence of WG in China has not been known until now.

The current study estimated the epidemiological parameters of WG, *i.e.* its incidence, mortality, and rate of remission, based on inpatient data from 100 hospitals throughout China. Although such an approach has limitations, it can provide a general view of the epidemiology of WG in China. The results may help to garner more attention and to develop strategies to prevent and reduce the risk of this ignored rare disease.

2. Data Collection and Methods

2.1. Estimation of the incidence of WG in China

Currently, China has no registry for WG. Data on inpatients with WG in 2011 were used to estimate the incidence of WG in China. Inpatient data were obtained from 100 hospitals in 7 provinces (Shandong, Anhui, Zhejiang, Hebei, He'nan, Jiangxi, and Fujian) in a national pilot project to study rare diseases in China. All data used in this study were accessed in accordance with ethical requirements and did not violate individual rights to privacy. Patients who were diagnosed with WG, *i.e.* code M 31.3 of the International Classification of Diseases, Tenth Revision (ICD-10), were identified. Clinical data were collected for all patients with WG, including age at the onset of disease, gender, and a confirmed diagnosis of WG. Patients with an unconfirmed diagnosis were excluded. The incidence of WG was estimated based on the number of patients with WG divided by the population served by these hospitals.

2.2. Estimation of WG-specific mortality in China and remission data

Since data on mortality from WG is currently unavailable in China and other Asian countries, the following strategy was adopted to determine the mortality from WG in China: first, WG is a systemic connective tissue disorder, and information on the total age-specific and sex-specific mortality from systemic connective tissue disorders is available for both China

and the United States; second, information on the age-specific and sex-specific mortality from WG in the United States is available; third, the least squares method was used to predict the mortality from WG in China. US data on WG was used to refine the model. Systemic connective tissue disorders served as an independent variable. Data on Chinese age-specific and sex-specific mortality from WG served as dependent variables.

$X^k = \{x_1^k, x_2^k, \dots, x_i^k, \dots, x_N^k\}$ expresses the independent variable, where k is sex and i is an age variable up to N (in the current study, N was 18).

$Y^k = \{y_1^k, y_2^k, \dots, y_i^k, \dots, y_N^k\}$ expresses the dependent variable, where k , i , and N represent the same variables as in the formula for the independent variable. The least squares criterion was used to construct a univariate linear regression model where:

$$\min. f(a, b) = \sum_{i=1}^N (y_i^k - \hat{y}_i^k)^2 = \sum_{i=1}^N (y_i^k - (a + b * x_i^k))^2$$

Here, $\hat{y}_i^k = a + b * x_i^k$ indicates the fitting results for the independent variable X^k .

WG is a rare multisystem autoimmune disease of unknown etiology. According to one study (10), patients with WG may enjoy stable periods from a clinical standpoint, but their return to a healthy state is considered impossible. Based on the criteria in a previous study that defined the rate of remission of scleroderma (11), the current study assumed that the rate of remission of WG was zero.

2.3. Other data sources

Population data for 7 provinces by age group and sex was obtained from the Chinese Public Health Data Center. The general age-specific and sex-specific mortality for the entire Chinese population were obtained from the Chinese Center for Disease Control and Prevention.

2.4. Data analysis using DISMOD II software

Age-specific and WG-specific mortality, incidence, and rate of remission were entered into DISMOD II. The general age-specific and sex-specific mortality for the entire Chinese population were entered in the tool along with population data. Equations were solved mathematically using the finite differences method, which is a method of iterative approximation. Estimates were calculated assuming a Poisson distribution.

2.5. Using DISMOD II to estimate the prevalence of hepatolenticular degeneration and hemophilia A in China

To verify whether the DISMOD II model would be suitable for determining the prevalence of rare diseases

Table 1. Estimated prevalence of WG in China by age group and gender, based on the cause-specific mortality from WG determined using formulae

Age group	Input (/100,000)				Output (/100,000)			
	Estimated incidence		Estimated mortality		Prevalence		Incidence	
	Males	Females	Males	Females	Males	Females	Males	Females
0-4	0.00	0.00	0.01	0.00	0.20	0.19	0.08	0.07
5-9	0.05	0.05	0.00	0.00	0.56	0.52	0.07	0.06
10-14	0.05	0.05	0.01	0.01	0.85	0.77	0.06	0.05
15-19	0.05	0.04	0.01	0.01	1.09	0.95	0.06	0.05
20-24	0.05	0.04	0.01	0.02	1.33	1.11	0.07	0.05
25-29	0.09	0.06	0.02	0.02	1.63	1.28	0.08	0.06
30-34	0.09	0.06	0.01	0.02	2.01	1.48	0.10	0.06
35-39	0.08	0.05	0.01	0.03	2.43	1.68	0.10	0.06
40-44	0.08	0.05	0.02	0.02	2.84	1.87	0.10	0.06
45-49	0.12	0.08	0.03	0.04	3.27	2.10	0.12	0.08
50-54	0.12	0.08	0.03	0.03	3.75	2.37	0.13	0.09
55-59	0.11	0.08	0.06	0.04	4.18	2.65	0.13	0.09
60-64	0.11	0.08	0.12	0.06	4.37	2.87	0.12	0.09
65-69	0.08	0.09	0.15	0.08	4.24	3.01	0.10	0.10
70-74	0.08	0.09	0.26	0.16	3.76	2.95	0.08	0.08
75-79	0.6	0.04	0.37	0.22	2.76	2.45	0.07	0.06
80-84	0.06	0.04	0.94	0.47	1.70	1.77	0.07	0.05
85+	0.00	0.00	0.00	0.00	1.50	1.63	0.02	0.02
Total	NA	NA	NA	NA	2.25	1.63	0.09	0.07

in China, the procedures described earlier were used to estimate the prevalence of hemophilia A and hepatolenticular degeneration in China with DISMOD II. Previous studies have examined the prevalence of these two rare diseases in China (12-13). Therefore, predictions were compared to known prevalence rates for the two diseases.

3. Results

The incidence of WG in 2011 was estimated based on inpatient data from 100 hospitals in 7 provinces of China. As shown in Table 1, the incidence of WG increased with age, peaking at 49-74 years for female patients and 25-74 years for male patients. Generally, male patients had an earlier onset and higher incidence of WG than female patients.

Data on mortality from WG is unavailable in China, so the least squares method was used to determine the age- and gender-specific incidence of WG based on data from the United States. Two formulae were derived to predict the mortality from WG in China, and results per 100,000 people in different age groups and with a different gender are shown in Table 1.

(1) For males, the optimal formula was:

$$\hat{y}_i^{male} = 0.0027 + 0.0446 * x_i^{male}$$

(2) For females, the optimal formula was:

$$\hat{y}_i^{female} = 0.0033 + 0.0237 * x_i^{female}$$

In the two formulae, the R2 statistic was 0.9827 and 0.9734, respectively, indicating that estimates were highly reliable.

Based on previous studies (10,11), the rate of

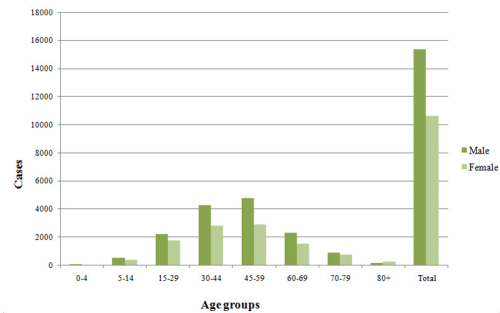


Figure 1. Estimation of the prevalence of WG by age group and gender in China.

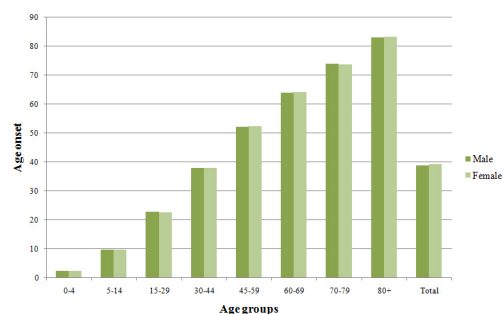


Figure 2. Age of onset of WG by age group and gender in China.

remission of WG can be assumed to be 0. Based on the estimated incidence, mortality, and rate of remission, the prevalence of WG in China was calculated with DISMOD II to be 2.25/100,000 for males versus 1.63/100,000 for females. There were no significant differences between males and females in terms of the prevalence of WG. The prevalence of WG increased with age and peaked at 60-64 years for males and 65-69 years for females (Table 1).

After adjusting for the Chinese population, the incidence, mortality, and rate of remission of WG were entered into DISMOD II. China is estimated to have 26,006 patients with WG consisting of 15,384 male and 10,622 female patients. The ratio of males to females in the patient population was 1.45:1 (Figure 1). As seen in Figure 2, the average duration of WG in China was estimated to be 28 years for both male and female patients. In the Chinese population with WG, male patients had an average age of onset of 38.9 years, which is slightly younger than the average age of onset in female patients (39.3 years).

Using the same procedures as were used to analyze WG, the incidence, mortality, and rate of remission of hepatolenticular degeneration and hemophilia A were entered into DISMOD II. The prevalence of hepatolenticular degeneration was estimated to be 2/100,000, which is slightly lower than its actual prevalence (4.93/100,000). The prevalence of hemophilia A was estimated to be 2.85/100,000, which is relatively close to its actual prevalence (2.2/100,000) (12-13).

4. Discussion

Although rare diseases are a topic of growing interest, the epidemiology of rare diseases is still a new area (14). Conventional studies with random sampling are not suitable for studying rare diseases, so epidemiological data on rare diseases is primarily obtained from disease registries or *via* extrapolation from other data sources. China does not have a specific registry for rare diseases, so important epidemiological data, and especially prevalence, are lacking for most rare diseases (15). A major challenge for China is to develop its medical policies on rare diseases (16-17).

The current study used WG as an example to calculate the prevalence of a rare disease with DISMOD II based on extrapolation. This strategy has been used to study other rare diseases. In the current strategy, three parameters (incidence determined from inpatient data, rate of remission, and estimated mortality) were entered into the DISMOD model. Results indicated that both inputs and outputs had almost the same distribution, so the strategy is highly valid. Moreover, this DISMOD II-based approach was validated with two other rare diseases. The estimated prevalence of these two rare diseases was close to the actual prevalence, suggesting that the current strategy can aptly reflect the actual prevalence of rare diseases. The DISMOD II model could be used to estimate the prevalence and other epidemiological parameters of other rare diseases in China.

Our results indicated that WG has a prevalence of 1.94/100,000 in China, which is close to its prevalence in other countries. This figure is lower than the prevalence of WG in Europe and the United States, where its prevalence ranges from 2.4 to 15.7/100,000, but this

figure is higher than the prevalence of WG in Iran (0.06/100,000). The incidence of WG in the current study reflects the number of inpatients with WG in proportion to the entire population, so some outpatients who were diagnosed with WG might have been left out. Therefore, the parameters for WG obtained here represent the lower limits, and the estimated prevalence of WG can be viewed as the lower limits of its prevalence in China. Figures for the age at onset and the duration of disease were similar to previously reported figures (10).

Despite the lack of a specific treatment to cure WG, some orphan drugs such as rituximab and methylprednisolone sodium succinate have been found to markedly improve survival. However, most of the orphan drugs to treat WG are still unavailable in China. The estimated incidence and prevalence of WG in China should provide a reference to help authorities develop a specific health policy on WG in the future, such as evaluating the cost-effectiveness of having the healthcare system cover orphan drugs to treat WG. The evidence-based estimates of the prevalence and incidence of WG should also help to encourage industry to research and develop innovative orphan drugs to treat this devastating rare disease.

Although the current results are promising, this study has limitations. First, the effects of some factors, such as socioeconomic status and level of medical care, were not precisely quantified. Second, the exact number of cases of WG throughout the country cannot be readily assessed due to the lack of data from registries. When these data become available, the prevalence of WG and other epidemiological parameters can be estimated more precisely.

In summary, the current study used DISMOD II software to estimate that the prevalence of WG in China. The current results indicated that the prevalence of WG is at least 1.94/100,000 and that China has a total of 26,006 patients with WG. These estimates should serve as an important reference when authorities work to increase the availability of orphan drugs to treat WG and when they develop a medical insurance policy for Chinese patients with WG. The model used here can be used to predict the prevalence of other rare diseases in China.

Acknowledgements

This work was supported by a grant for Key Projects of the National Program to Support Science & Technology under the Twelfth Five-year Plan (2013BAI07B02). The authors wish to thank Dr. Chengyu Liu at Shandong University for his kind assistance and suggestions regarding data analysis.

References

1. Barendregt JJ, Van Oortmarssen GJ, Vos T, Murray CJ. A

- generic model for the assessment of disease epidemiology: The computational basis of DISMOD II. *Popul Health Metr.* 2003; 1:4.
2. Yang LP, Liang SY, Wang XJ, Li XJ, Wu YL, Ma W. Burden of disease measured by disability-adjusted life years and a disease forecasting time series model of scrub typhus in Laiwu, China. *PLoS Negl Trop Dis.* 2015; 9:e3420.
 3. Chung SE, Cheong HK, Park JH, Kim HJ. Burden of disease of multiple sclerosis in Korea. *Epidemiol Health.* 2012; 34:e2012008.
 4. Phanthunane P, Vos T, Whiteford H, Bertram M, Udomratn P. Schizophrenia in Thailand: Prevalence and burden of disease. *Popul Health Metr.* 2010; 8:24.
 5. Chen M, Yu F, Zhang Y, Zou WZ, Zhao MH, Wang HY. Characteristics of Chinese patients with Wegener's granulomatosis with anti-myeloperoxidase autoantibodies. *Kidney Int.* 2005; 68:2225-2229.
 6. Luqmani R, Suppiah R, Edwards CJ, Phillip R, Maskell J, Culliford D, Jayne D, Morishita K, Arden N. Mortality in Wegener's granulomatosis: A bimodal pattern. *Rheumatology (Oxford).* 2011; 50:697-702.
 7. Mahr AD, Neogi T, Merkel PA. Epidemiology of Wegener's granulomatosis: Lessons from descriptive studies and analyses of genetic and environmental risk determinants. *Clin Exp Rheumatol.* 2006; 24(2 Suppl 41):S82-91.
 8. Cotch MF, Hoffman GS, Yerg DE, Kaufman GI, Targonski P, Kaslow RA. The epidemiology of Wegener's granulomatosis: Estimates of the five-year period prevalence, annual mortality, and geographic disease distribution from population-based data sources. *Arthritis Rheum.* 1996; 39:87-92.
 9. Tahghighi F, Moradinejad MH, Moradinejad MH, Shiari R, Raeskarami SR, Salehzadeh F, Javadi V, Ziaee V. Evaluation of 10-year experience of Wegener's granulomatosis in Iranian children. *ISRN Rheumatol.* 2013; 2013:694928.
 10. Watts RA, Al-Taiar A, Scott DG, Macgregor AJ. Prevalence and incidence of Wegener's granulomatosis in the UK general practice research database. *Arthritis Rheum.* 2009; 61:1412-1416.
 11. Villaverde-Hueso A, de la Paz MP, Martin-Arribas MC, Sanchez-Valle E, Ramirez-Gonzalez A, Baiardi P. Prevalence of scleroderma in Spain: An approach for estimating rare disease prevalence using a disease model. *Pharmacoepidemiol Drug Saf.* 2008; 17:1100-1107.
 12. Yanji Qu, Xiaolu Nie, Zhirong Yang, Siyan Zhan. Meta-analysis of the prevalence of hemophilia in mainland China. *Chin J Hematol.* 2014; 35:65-68. (in Chinese)
 13. Wenbin Hu, Yonzhu Han, Renmin Yang, Nan Cheng, Benchun Xue, Daoyin Sun, Xuen Yu, Yongsheng Han, Dongqing Ye. Epidemiological investigation of hepatolenticular degeneration in the Han population of Jinzhai and Lixin counties, Anhui Province: Report of a family pedigree. *Anhui Medical Journal.* 2012; 33:734-737. (in Chinese)
 14. de la Paz MP, Villaverde-Hueso A, Alonso V, Janos S, Zurriaga O, Pollan M, Abaitua-Borda I. Rare diseases epidemiology research. *Adv Exp Med Biol.* 2010; 686:17-39.
 15. Cui Y, Han J. A proposed definition of rare diseases for China: From the perspective of return on investment in new orphan drugs. *Orphanet J Rare Dis.* 2015; 10:28.
 16. Cui Y, Zhao H, Liu Z, Liu C, Luan J, Zhou X, Han J. A systematic review of genetic skeletal disorders reported in Chinese biomedical journals between 1978 and 2012. *Orphanet J Rare Dis.* 2012; 7:55.
 17. Song P, Gao J, Inagaki Y, Kokudo N, Tang W. Intractable and rare diseases research in Asia. *Biosci Trends.* 2012; 6:48-51.

(Received April 24, 2015; revised December 24, 2015; Accepted December 29, 2015)

Castleman's disease of a submandibular mass diagnosed on Fine Needle Cytology: Report of a case with histopathological, immunocytochemical and imaging correlations

Maria Gabriella Malzone^{1,*}, Anna Cipolletta Campanile¹, Veronica Sanna¹, Franco Ionna², Francesco Longo², Annarosaria De Chiara¹, Sergio Venanzio Setola³, Gerardo Botti¹, Franco Fulcinì⁴

¹S.S.D. di Citopatologia e S.C. di Anatomia Patologica, Istituto Nazionale Tumori "Fondazione G. Pascale", Napoli, Italy;

²S.C. Maxillo Facciale – Otorinolaringoiatria, Istituto Nazionale Tumori "Fondazione G. Pascale", Napoli, Italy;

³S.C. Radiodiagnostica I, Dipt. Diagnostica per immagini – Terapia Radiante e Metabolica, Istituto Nazionale Tumori "Fondazione G. Pascale", Napoli, Italy;

⁴Servizio di Citopatologia Clinica, Istituto Cantonale di Patologia, Locarno, Switzerland.

Summary Castleman's disease (CD) is an unusual inflammatory lymphoproliferative disorder of uncertain aetiology, mainly involving lymphatic tissue in the mediastinum, but also occurring in the neck, lung, abdomen, pelvis, skeletal muscle and retroperitoneum. Fine Needle Cytology (FNC) is a quick, cost-effective and safe diagnostic modality to investigate on organs involved by CD, also providing a guide to treatment and management of patients with lymphadenopathy. We report a case of a 44-year-old man who underwent FNC of a submandibular mass with subsequent surgical excision. Cytology revealed an atypical lymphoproliferative process, which arose the suspicion of CD. Histopathological study of the excised masses combined with immunohistochemistry and imaging of the submandibular and neck areas, confirmed the suspicion. A final diagnosis of Unicentric Castleman's disease, hyaline-vascular type, was made.

Keywords: Lymphoproliferative disorder, aspiration cytology, hyaline vascular type

1. Introduction

Castleman's disease (CD) was firstly described in 1956 by Castleman and his collaborators in a group of patients with benign localised hyperplastic lymph nodes in the mediastinal area (1).

It is a rare lymphoproliferative condition of unknown cause, with the two main hypotheses being abnormal immune response and viral infection (2,3). The age of affected patients ranges from 8 to 69 (4,5), with no sex predilection (5,6). Although the disease is mostly located in the mediastinum, CD can occur wherever lymphoid tissue is found (7,8).

CD is divided into localized/unicentric (UCD) and

generalized/multicentric (MCD) due to the profound clinical differences between the two variants. Patients with UCD are generally asymptomatic, with a painless solitary mass usually localized to the mediastinum or pulmonary hilum, although other locations like the pelvis, neck, abdomen, axilla and retroperitoneum have also been described (9). A minority of patients may present few symptoms, such as cough, dyspnea, fever, night sweats, peripheral lymphadenopathy, splenomegaly and hepatomegaly, depending on the histopathological subtype (5,10). UCD has a benign prognosis.

In contrast, MCD involves multiple lymph nodes separately or in a confluent pattern and patients present systemic symptoms including autoimmune phenomena and an aggressive course (11). MCD is frequently associated to HHV8 infection, Kaposi sarcoma and HIV infection (12,13).

Microscopically, two distinct histological patterns have been described: the hyaline-vascular type (HV) and the plasma cell type (PC). A third "mixed" type

*Address correspondence to:

Dr. Maria Gabriella Malzone, S.S.D. di Citopatologia e S.C. di Anatomia Patologica, Istituto Nazionale Tumori "Fondazione G. Pascale", via Mariano Semmola, 80131 Napoli, Italy.
E-mail: gabriellamalzone@hotmail.com

presenting histopathological features of both HV and PC types has also been reported (3,14).

Fine Needle cytology (FNC) is a useful, minimally invasive technique to obtain a preoperative diagnosis in many organ sites (15) and to rule out reactive lymphadenopathies and malignant lymphoma or other neoplastic conditions (16-18). Although the cytologic diagnosis of conditions that affect lymph nodes can be very challenging, the overall diagnostic FNC accuracy has been reported to be 90% approximately, with a sensitivity of 85-95% and specificity of 98-100% (19,20).

False-negative cytological diagnoses on lymph nodes are more common than false-positive, due to inadequate sampling, inexperience with their cytology and overlapping of morphological features (20,21). Therefore, ancillary techniques and/or excisional biopsy may be very helpful for a definitive diagnosis.

We report herein the cytomorphological features, based on FNC, of a case of UCD hyaline-vascular type correlated to imaging, immunocytochemistry and histological findings.

2. Case Report

In 2009 a 44-year-old male was admitted to a local hospital for the excision of a left submandibular lymph node. The diagnosis of reactive hyperplasia was made and confirmed by a later counselling at a hospital in Bologna. The patient was suffering from microcytic anemia with thrombocytopenia since childhood and had been splenectomised without success. In 2014 a painless and moderately hard lump appeared under the submandibular scar, measuring 5 cm in diameter, and he was then referred to our Institute.

FNC samples were obtained under palpation or ultrasound guidance by using 23-25G needles, without suction. The smears were air-dried and stained with Diff Quik™ or wet-fixed in 95% ethanol and stained with Papanicolaou (Pap). Immunocytochemistry was also carried out: the smears were stained for CD3, CD20, CD21, CD30 and Ki67.

A few days later the patient returned to our Institute for an ultrasound examination followed by surgical removal of the submandibular lymph node and a salivary gland. Immunohistochemistry was performed, using CD10, CD20, B-cell lymphoma 6 (Bcl6), B-cell lymphoma 2 (Bcl2), Ki67 protein on the lymph node sample and CD20, CD1, CD34, CD3, CD30, CD138, B-cell lymphoma 6 (Bcl6), B-cell lymphoma 2 (Bcl2), Ki67 protein on the salivary gland sample.

Since the operation, the patient showed no progression or recurrence of the disease during the follow-up.

2.1. Cytological findings

The submandibular lymph node smears showed

a polymorphic cytological picture represented by lymphoid cells in different maturation stages, of both B- and T-cell type. The general impression was, nevertheless, that of a relative depletion of follicular centre cells, with numerous atypical lymphoid cells of medium to large-size, later found to be atypical follicular dendritic cells. These cells were characterised by a transparent cytoplasm, with indistinct dendritic processes on both Pap and DQ stained slides; they showed a single large, sometimes nucleolated, vesicular nucleus with homogeneously scattered heterochromatin (Figure 1A and 1B). Occasionally, bi- and plurinucleated atypical cells with similar nucleo-cytoplasmic features were also found (Figure 1C). Sporadic histiocytes were also observed; their cytoplasm engulfed with intact mature lymphocytes (Figure 1D). Thin capillary fragments were scattered among the cells (Figure 1E). Immunocytochemical staining showed a diffuse membrane positivity for CD20 in the lymphoid B-cells and for CD3 in the lymphoid T-cells. The atypical cells did not show any expression of CD30 but diffusely expressed CD21, which also enhanced their cytoplasmic

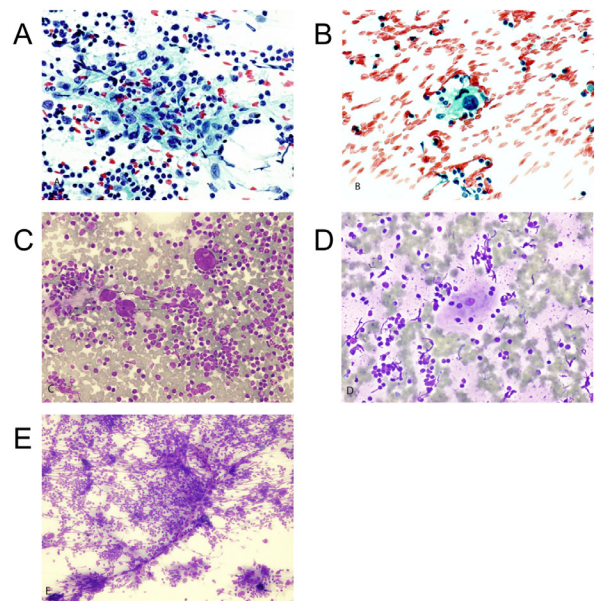


Figure 1. Cytological findings: FNC samples. (A) A sheet of large atypical lymphoid cells can be seen admixed with lymphocytes in various stages of maturation. The cells show oval nuclei with vesicular chromatin appearance. Scattered chromocenters and occasional nucleoli may be seen. (Pap, $\times 400$, original magnification). (B) A single atypical lymphoid cell shows a large vesicular nucleus with rough chromatin pattern and a prominent nucleolus of irregular shape. Also notice the delicate, slightly cyanophylic dendritic cytoplasmic extensions surrounding its nucleus (Pap, $\times 630$, original magnification). (C) Atypical follicular dendritic cells showing both a single large, nucleolated, vesicular nucleus with homogeneously scattered heterochromatin and bi/ plurinucleation (DQ, $\times 400$, original magnification). (D) Histiocytes with cytoplasm engulfed with intact mature lymphocytes (DQ, $\times 400$, original magnification). (E) Capillary fragments scattered among the cells (DQ, $\times 200$, original magnification).

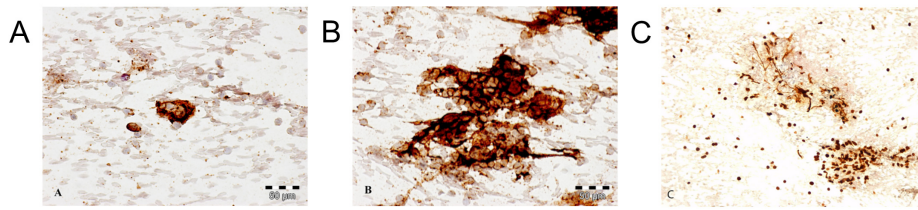


Figure 2. Immunocytochemical findings. (A) An atypical cell diffusely expressing CD21, which also enhanced its cytoplasmic dendritic processes (Immunoperoxidase, $\times 600$, original magnification). (B) CD21 showed a diffuse positivity in the atypical cells as well as among the mature lymphoid cells (Immunoperoxidase, $\times 600$, original magnification). (C) Ki67 staining ratio (Immunoperoxidase, $\times 200$, original magnification).

dendritic processes (Figure 2A). CD21 also showed a diffuse interstitial positivity among the mature lymphoid cells (Figure 2B). Ki67 staining ratio was extremely high (almost 100%) (Figure 2C).

A cytological diagnosis of atypical lymphoproliferative disease was made. The possibility of Castleman's disease was also hypothesized and therefore surgical resection of the mass and its histopathologic examination were suggested.

2.2. Imaging features

Ultrasound examination of the left submandibular area showed a major hypoechoic mass of 5×2.5 cm of diameter approximately, with regular margins and light internal lobulations (Figure S1A), and a few other adjacent masses less than 1cm of diameter. Color-Doppler examination showed both intralesional and peripheral vascularisation. Three other normal appearing lymph nodes between Level III (10 mm) (Figure S1B) and IV (10 and 12 mm) (Figure S1C) of the neck were also detected.

No signs of further submandibular, laterocervical or supraclavicular lymphadenomegaly were found. Computed tomography of the thorax and abdomen revealed no suspicious masses.

2.3. Histological findings

Lymph node of the II left submandibular Level. Histopathology revealed a well-preserved lymph nodal structure formed by germinal centres surrounded by thick mantle zones (Figure S2). Germinal centres were immunochemically positive for CD10, CD20, Bcl6 (but no positivity was detected in the interfollicular areas) and negative for Bcl2. The Ki67 proliferative index was very high (90%). These findings were compatible with a reactive lymphadenopathy.

Left submandibular scialectomy. The scialectomy sample consisted of a mass of $7 \times 4 \times 3$ cm with an annex fibro-fatty fragment containing the submandibular salivary gland of $5 \times 3 \times 2.5$ cm. The mass was capsulated, with a gray-whitish cut surface and surrounded by an irregular paler area of 1 cm in diameter. A lymph node measuring of 2×1 cm was also present in the periphery of the

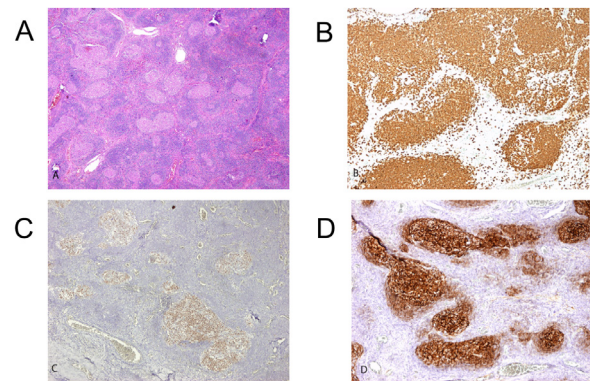


Figure 3. Microscopic and immunohistochemical examination of the left submandibular scialectomy. (A) Microscopic appearance of the lymph node (HE, $\times 40$, original magnification). (B) The lymph node was characterised by enlarged follicular structures immunochemically positive for CD20 ($\times 100$, original magnification). (C) The lymph node was formed by germinal centres immunochemically positive for Bcl6 ($\times 100$, original magnification). (D) The germinal centres contained small atrophic follicular dendritic cells immunochemically positive for CD21 ($\times 100$, original magnification).

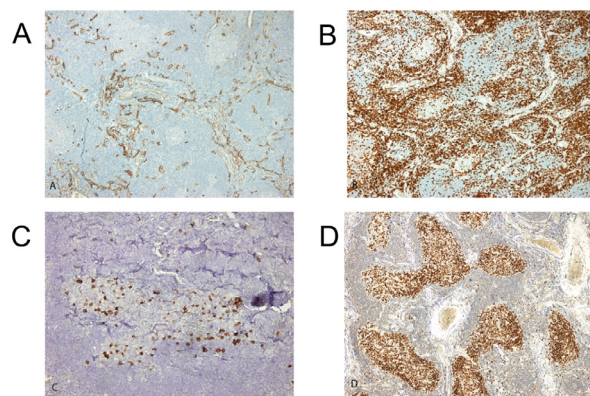


Figure 4. Further histological findings and their immunohistochemistry examination. (A) Blood vessels between the follicles immunochemically positive for CD34 ($\times 100$, original magnification). (B) Small lymphocytes immunochemically positive for CD3 ($\times 100$, original magnification). (C) plasma cells immunochemically positive for CD138 ($\times 200$, original magnification). (D) Ki67 staining ratio ($\times 100$, original magnification).

mass. Microscopic examination showed an organized lymphoid tissue consistent with a lymph node (Figure 3A), characterised by enlarged follicular structures

(CD20+; CD1-) (Figure 3B) formed by germinal centres (Bcl6+; Bcl2-) (Figure 3C) containing small atrophic follicular dendritic cells (CD21+) (Figure 3D), which were sometimes of large size and bizarre shape, and surrounded by a normal mantle zone.

Hyalinized small blood vessels penetrated the follicular germinal centres perpendicularly. Between the follicles there were numerous vascular structures (CD34+) (Figure 4A), small T-lymphocytes (CD3+) (Figure 4B) and few plasma cells (CD138+) (Figure 4C). No immunoreactive cells for HHV8 or CD30 were detected. The Ki67 proliferative index was very high (90%) (Figure 4D). The histopathological findings were consistent with Unicentric Castleman's disease, hyaline vascular type, with the presence of giant follicular dendritic cells.

3. Discussion

Castleman's disease (CD) is a rare benign lymphoepithelial disorder that usually occurs in the mediastinum as a nodal mass (22) but there have been reports describing extramediastinal lymph node enlargements (3). CD may be asymptomatic, as it often occurs in case of the hyaline vascular variant, or symptomatic, with diffuse lymphadenopathy and severe systemic symptoms, such in the plasma cell variant (23). The aetiology of CD is not completely clear yet: clinical evidences include chronic antigenic stimulation by a virus (human herpes virus 8 or Kaposi sarcoma-associated herpes virus) (13,14), chronic inflammation (1), immunodeficient state (24) and autoimmunity (25,26).

Furthermore, excess production of interleukin-6 (IL-6) plays an important role in the pathogenesis of the CD (27). Giant lymph node hyperplasia is generally treated with surgery (28).

According to the latest investigations, complete resections provide the same surgical results in deep and superficial CD (29). No recurrences have been reported in the literature after complete resection of the hyaline vascular type. Cytoreduction with radiotherapy and a combination of chemotherapies have been recommended in cases where complete resection is not achievable (30,31), such as the multicentric forms. The prognosis and outcome of the multicentric type are usually poorer due to many factors, like progression rate, infections and comorbidities (32-34).

Fine Needle Cytology (FNC) is a quick, cost-effective and safe diagnostic tool, which can be particularly advantageous in non-surgical diseases and has proved very useful for the discrimination between reactive lymphadenopathies and other malignant conditions. The use of FNA has led to a wide knowledge of the cytology of reactive lymph nodes, including the rarest conditions (16-18). However, FNA remains rather underutilized for the evaluation of lymphadenopathy, partially due to the lack of available

expertise for the performance and interpretation of such samples (21). Several authors have emphasised the diagnostic importance of FNC in CD (35,36). Although only case reports are available in the literature, attempts have been made to describe the cytomorphological findings in CD (37-42) which can be indicative enough for it to be considered preoperatively, among other entities.

In our report the cytological picture was represented by lymphoid cells in different maturation stages, of both B- and T-cell type, and numerous atypical lymphoid cells varying from medium to large-size, similar to those reported by Hidvegi (37) and Cangiarella (38).

Mallik (43) suggested that the main and most consistent clue to the cytological diagnosis of CD is "the presence of large atypical cells with "crumpled tissue paper" like chromatin, occasional multinucleation, nuclear indentations and nuclear grooves". In our case the only characteristic that could be appreciated was the occasional multinucleation, whereas the atypical cells had scant cytoplasm, a single large, sometimes nucleolated vesicular nucleus with homogeneously scattered heterochromatin. Only few atypical cells with prominent nucleolus mimicking Hodgkin's cells, as commented by Mallik (43), were present in our samples, which did not show any expression of CD30. Hidvegi and his collaborators in the first FNA case report of CD (37) described the presence of capillary vessels in their aspirate. We also found capillary fragments in our case, which posed CD among the possible diseases. When the cytological features suggest this entity, imaging data and immunochemistry may play an important role in the final diagnosis. A hypoechogenic and hypervascular mass showing well-defined margins on imaging, with or without systemic symptoms, should include CD in the differential diagnosis. A polymorphic B-cell population (CD20+) with normal T cells (CD3+) and CD30 negative large atypical mononuclear, binucleated or multinucleated cells excludes the diagnosis of Hodgkin's lymphoma and thymoma. The observation, in such clinical setting, of large mono- bi- or multinucleated atypical cells with vesicular, nucleolated nuclei which do not display any reactivity for CD30, should raise the possibility of CD. In our case, the histological examination combined with immunohistochemistry gave the final confirmation of CD.

In conclusion, although it is probably not possible to give a definitive diagnosis of CD on FNC samples, the presence of branching hyaline capillaries penetrating reactive follicular germinal centres should at least raise this diagnostic possibility. After exclusion of other lymphoproliferative disorders, a careful review of the cytomorphology and clinical features should be carried out. Given the cytomorphological overlap and atypia in some cases, ancillary studies and/or excisional biopsy should be recommended and Castleman's disease can be suggested to the surgeon as a diagnostic possibility.

Acknowledgements

The authors gratefully acknowledge the technical assistance of Mrs. Angela Manna, Dr. Antonella Gioioso and Dr. Fernando Caccavello.

References

- Castleman B, Iverson L, Menendez VP. Localized mediastinal lymph node hyperplasia resembling thymoma. *Cancer*. 1956; 9:822-830.
- Ghosh A, Pradhan SV, Talwar OP. Castleman's disease - hyaline vascular type - clinical, cytological and histological features with review of literature. *Indian J Pathol Microbiol*. 2010; 53:244-247.
- Keller AR, Hochholzer L, Castleman B. Hyaline-vascular and plasma-cell types of giant lymph node hyperplasia of the mediastinum and other locations. *Cancer*. 1972; 29:670-683.
- Herrada J, Cabanillas FF. Multicentric Castleman's disease. *Am J Clin Oncol*. 1995; 18:180-183.
- Talat N, Schulte KM. Castleman's disease: Systematic analysis of 416 patients from the literature. *Oncologist*. 2011; 16:1316-1324.
- Maslovsky I, Urieu L, Lugassy G. The heterogeneity of Castleman disease: Report of five cases and review of the literature. *Am J Med Sci*. 2000; 320:292-295.
- Takayama F, Takashima S, Wang J, Ishiyama T, Kadoya M. Castleman disease of the parotid gland: MR imaging findings with pathologic correlation. *European Journal of Radiology Extra*. 2003; 45:118-121.
- Park JH, Lee SW, Koh YW. Castleman disease of the parotid gland in childhood: An unusual entity. *Auris Nasus Larynx*. 2008; 35:451-454.
- O'Malley DO, George TI, Orazi A, Abbondanzo SL. Specific clinical entities. In: *Benign and reactive conditions of the lymph node and spleen. Atlas of nontumor pathology. First series. American Registry of Pathology, Washington DC, 2009*; pp. 155-164.
- Jongsma TE, Verburg RJ, Geelhoed-Duijvestijn PH. Castleman's disease: A rare lymphoproliferative disorder. *Eur J Intern Med*. 2007; 18:87-89.
- Menezes BF, Morgan R, Azad M. Multicentric Castleman's disease: A case report. *J Med Case Rep*. 2007; 1:78.
- Du MQ, Bacon CM, Isaacson PG. Kaposi sarcoma-associated herpes virus/human herpesvirus 8 and lymphoproliferative disorders. *J Clin Pathol*. 2007; 60:1350-1357.
- Seliem RM, Griffith RC, Harris NL, Beheshti J, Schiffman FJ, Longtine J, Kutok J, Ferry JA. HHV-8+, EBV+ multicentric plasmablastic microlymphoma in an HIV+ man: The spectrum of HHV-8+ lymphoproliferative disorders expands. *Am J Surg Pathol*. 2007; 31:1439-1445.
- Frizzera G. Castleman's disease and related disorders. *Semin Diagn Pathol*. 1988; 5:346-364.
- Rimm DL, Stastny JF, Rimm EB, Ayer S, Frable WJ. Comparison of the costs of fine-needle aspiration and open surgical biopsy as methods for obtaining a pathologic diagnosis. *Cancer*. 1997; 81:51-56.
- Monaco SE, Khalbuss WE, Pantanowitz L. Benign non-infectious causes of lymphadenopathy: A review of cytomorphology and differential diagnosis. *Diagn Cytopathol*. 2012; 40:925-938.
- Saboorian MH, Ashfaq R. The use of fine needle aspiration biopsy in the evaluation of lymphadenopathy. *Semin Diagn Pathol*. 2001; 18:110-123.
- Miliauskas J. Lymph nodes. In: *Fine needle aspiration cytology* (Orell S, Sterrett G, Whitaker D, eds). Churchill-Livingstone, London, 2005; pp. 83-124.
- Lioe TF, Elliott H, Allen DC, Spence RA. The role of fine needle aspiration cytology (FNAC) in the investigation of superficial lymphadenopathy; uses and limitations of the technique. *Cytopathology* 1999; 10:291-297.
- Thomas JO, Adeyi D, Amunguno H. Fine-needle aspiration in the management of peripheral lymphadenopathy in a developing country. *Diagn Cytopathol*. 1999; 21:159-162.
- Steel BL, Schwartz MR, Ramzy I. Fine needle aspiration biopsy in the diagnosis of lymphadenopathy in 1,103 patients. Role, limitations, and analysis of diagnostic pitfalls. *Acta Cytol*. 1995; 39:76-81.
- Rosai J. Lymph nodes. In: *Rosai and Ackerman's Surgical Pathology* (Rosai J, ed). 9th Ed. St Louis: Mosby, 2003; pp. 1877-2017.
- Cronin DM, Warnke RA. Castleman disease: An update on classification and the spectrum of associated lesions. *Adv Anat Pathol*. 2009; 16:236-246.
- Oksenhendler E, Duarte M, Soulier J, Cacoub P, Welker Y, Cadranet J, Cazals-Hatem D, Autran B, Clauvel JP, Raphael M. Multicentric Castleman's disease in HIV infection: A clinical and pathological study of 20 patients. *AIDS*. 1996; 10:61-67.
- Frizzera G. Castleman's disease: More questions than answers. *Hum Pathol*. 1985; 16:202-205.
- Hsu SM, Waldron JA, Xie SS, Barlogie B. Expression of interleukin-6 in Castleman's disease. *Hum Pathol*. 1993; 24:833-839.
- Yuzuriha A, Saitoh T, Koiso H, Mitsui T, Uchiumi H, Yokohama A, Handa H, Kojima M, Tsukamoto N, Karaswa M, Murakami H, Nojima Y. Successful treatment of autoimmune hemolytic anemia associated with multicentric Castleman disease by anti-interleukin-6 receptor antibody (tocilizumab) therapy. *Acta Haematol*. 2011; 126:147-150.
- Talat N, Belgumkar AP, Schulte K-M. Surgery in Castleman's disease: A systematic review of 404 published cases. *Ann Surg*. 2012; 255:677-684.
- Chen CH, Liu HC, Tung KY, Lee JJ, Liu CL, Liu TP. Surgical outcome of superficial and deep Castleman disease. *ANZ J Surg*. 2007; 77:339-343.
- Roca B. Castleman's disease. A review. *AIDS Rev*. 2009; 11:3-7.
- Chronowski GM, Ha CS, Wilder RB, Cabanillas F, Manning J, Cox JD. Treatment of unicentric and multicentric Castleman disease and the role of radiotherapy. *Cancer*. 2001; 92:670-676.
- Casper C. The aetiology and management of Castleman disease at 50 years: Translating pathophysiology to patient care. *Br J Haematol*. 2005; 129:3-17.
- de Vries IA, van Acht MM, Demeyere T, Lybeert ML, de Zoete JP, Nieuwenhuijzen GA. Neoadjuvant radiotherapy of primary irresectable unicentric Castleman's disease: A case report and review of the literature. *Radiat Oncol*. 2010; 5:7.
- Karami H, Sahebpour AA, Ghasemi M, Karami H, Dabirian M, Vahidshahi K, Masiha F, Shahmohammadi S. Hyaline vascular-type Castleman's disease in the hilum of liver: A case report. *Cases J*. 2010; 3:74.

35. Deschenes M, Michel RP, Tabah R, Auger M. Fine-needle aspiration cytology of Castleman's disease: Case report with review of the literature. *Diagn Cytopathol.* 2008; 36:904-908.
36. Gordillo Vélez CH, Becerra IB, García CB, Rodríguez FA, Heffernan JAJ. Fine needle aspiration cytology of Castleman disease, plasma celltype. A report of three cases. *Rev Esp Patol.* 2014; 47:110-113.
37. Hidvegi DF, Sorensen K, Lawrence JB, Nieman HL, Isoe C. Castleman's disease. Cytomorphologic and cytochemical features of a case. *Acta Cytol.* 1982; 26:243-246.
38. Cangiarella J, Gallo L, Winkler B. Potential pitfalls in the diagnoses of Castleman's disease of the mediastinum on fine needle aspiration biopsy. *Acta Cytol.* 1997; 41:951-952.
39. Taylor GB, Smeeton IW. Cytologic demonstration of "dysplastic" follicular dendritic cells in a case of hyaline-vascular Castleman's disease. *Diagn Cytopathol.* 2000; 22:230-234.
40. Panayiotides J, Tsilabis T, Bollas N, Krameris A. Parotid Castleman's disease. *Cytopathology.* 1998; 9:50-54.
41. Chan MK, McGuire LJ. Cytodiagnosis of lesions presenting as salivary gland: A report of seven cases. *Diagn Cytopathol.* 1992; 8:439-443.
42. Meyer L, Gibbons D, Ashfaq R, Vuitch F, Saboorian MH. Fine-needle aspiration findings in Castleman's Disease. *Diagn Cytopathol.* 1999; 21:57-60.
43. Mallik MK, Kapila K, Das DK, Haji BE, Anim JT. Cytomorphology of hyaline-vascular Castleman's disease: A diagnostic challenge. *Cytopathology.* 2007; 18:168-174.

(Received January 25, 2016; Accepted February 2, 2016)

Supplemental Figures

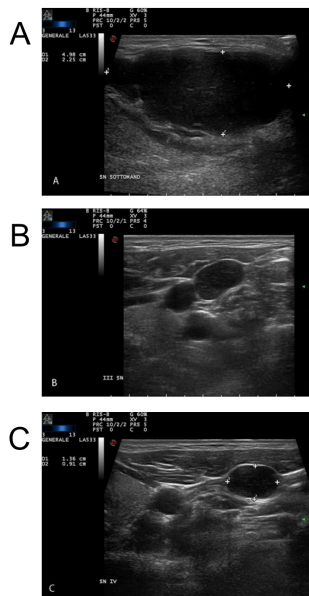


Figure S1. Ultrasound images of the nodules. (A) Ultrasound examination of the left submandibular area showing a major hypoechoic mass with regular margins and light internal lobulations. (B) Normal appearing lymph nodes between Level III and (C) Level IV of the neck.

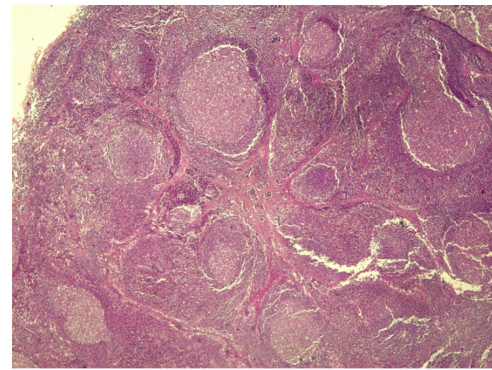


Figure S2. Histological findings. Structure of the lymph node of the II left submandibular Level formed by germinal centres surrounded by thick mantle zones (HE, $\times 40$, original magnification).

Peutz-Jeghers syndrome: Four cases in one family

Ran Wang^{1,2}, Xingshun Qi^{1,*}, Xu Liu¹, Xiaozhong Guo^{1,2,*}

¹Department of Gastroenterology, General Hospital of the Shenyang Military Area, Shenyang, China;

²Postgraduate College, Liaoning University of Traditional Chinese Medicine, Shenyang, China.

Summary Peutz-Jeghers syndrome (PJS) is a rare, but life-threatening, familial inherited disease, characterized by mucocutaneous pigmentation and hamartomatous polyps. The estimated incidence of PJS ranges from 1/50,000 to 1/200,000. PJS can significantly increase the risk of malignancies, and especially gastrointestinal malignancies. Reported here are 4 cases of PJS in one family.

Keywords: Peutz-Jeghers syndrome, hamartomatous polyp, malignancy

1. Introduction

In 1921, Peutz first reported a case of a Dutch family with multiple polyps throughout the gastrointestinal tract and mucocutaneous pigmentation. In 1949, Jeghers *et al.* reported 10 cases involving similar complaints and they noted a connection between multiple polyps and pigmentation. Peutz-Jeghers syndrome (PJS) is a rare, but life-threatening, familial inherited disease (1,2). The estimated incidence of PJS ranges from 1/50,000 to 1/200,000. PJS can significantly increase the risk of malignancies, and especially gastrointestinal malignancies (3). Reported here are 4 cases of PJS in one family.

2. Case report

On April 2015, a 22-year-old male was admitted to this department for intermittent abdominal discomfort and diarrhea. The young man had scattered black spots on his lips and fingers. Eight years ago, he was diagnosed with intestinal obstruction due to multiple polyps in his small intestine and he underwent intestinal resection at a local hospital. PJS was diagnosed. Computed tomography scans of the abdomen (Figure 1) and

colonic endoscopy and upper gastrointestinal endoscopy (Figure 2) at admission to this Department revealed a number of large polyps. The maximum length of polyps in the transverse colon was 12 cm. Subsequently, the patient underwent endoscopic polypectomy. Histology confirmed the presence of inflammatory polyps (Figure 3). The patient was discharged without problem.

On June 2015, his cousin, a 19-year-old girl, was also admitted to this Department for colonic endoscopy. The girl had slight mucocutaneous pigmentation on her lips and fingers. She was diagnosed with PJS by a local hospital and intussusception was noted, so she underwent intestinal resection in 2012. Histology confirmed the presence of hamartomatous polyps. Upon admission, the polyps were treated *via* a double-balloon endoscopic polypectomy. The patient refused to undergo subsequent histological examinations, and she was discharged without problem.

After a detailed survey of 14 members of the original patient's family, his father and uncle were also diagnosed with PJS. His father died of a post-operative infection at the age of 30. His uncle died of lung adenocarcinoma at the age of 44. His cousin was alive and age 19. Other family members had no symptoms or signs of PJS (Figure 4). The original patient and his cousin are being followed with regular endoscopic examinations.

3. Discussion

PJS is an autosomal dominant disease with no significant difference in the gender or race of individuals it affects. Patients with PJS have different complications such as obstruction, intussusception, and anemia (4). The treatment of PJS often depends on

Released online in J-STAGE as advance publication November 20, 2015.

*Address correspondence to:

Dr. Xiaozhong Guo and Dr. Xingshun Qi, Department of Gastroenterology, General Hospital of the Shenyang Military Area, No. 83 Wenhua Road, Shenyang 110840, China.

E-mail: guo_xiao_zhong@126.com (Guo XZ); xingshunqi@126.com (Qi XS)

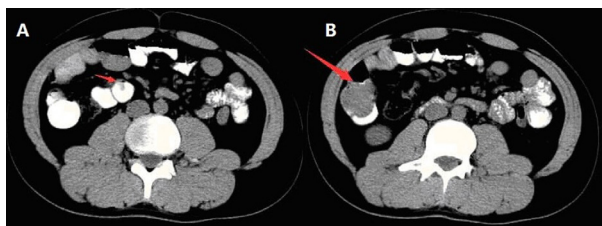


Figure 1. Computed tomography scans of the abdomen. Red arrows point to polyps.

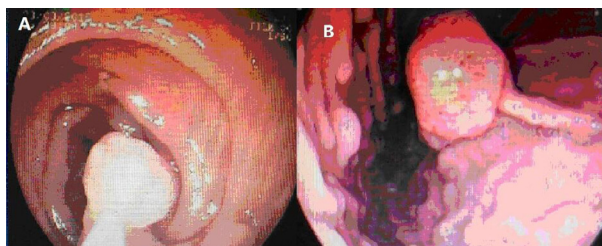


Figure 2. Endoscopic examination. (A), Colonic polyp; (B), Gastric polyp.

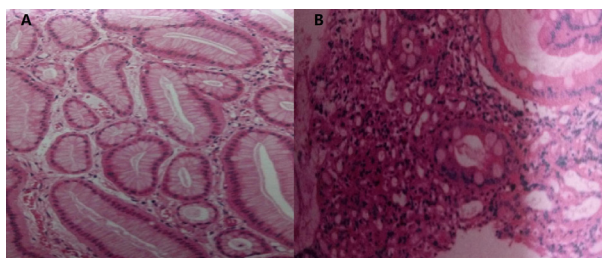


Figure 3. Histological examination. (A), Gastric histology confirmed the presence of inflammatory polyps; (B), Colonic histology confirmed the presence of inflammatory polyps.

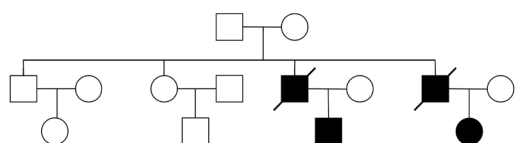


Figure 4. Family tree. A square refers to a male and a circle refers to a female. A slash indicates a person who has died.

those complications. Laser therapy can be used to treat pigmentation if the patient so desires. Double-balloon endoscopy allows both examination and treatment of polyps. A timely polypectomy with double-balloon endoscopy can reduce the need for abdominal surgery and consequent problems in patients with PJS (5).

The WHO diagnostic criteria for PJS include: *i*) ≥ 3 hamartomatous polyps; *ii*) hamartomatous polyps and a family history of PJS; *iii*) mucocutaneous pigmentation and a family history of PJS; or *iv*) mucocutaneous pigmentation and hamartomatous polyps (6). Hamartomatous polyps were considered to be benign lesions, but there is uncertainty as to whether or not PJS-associated hamartomas were pre-malignant in PJS.

Some researchers believe that PJS is an epiphenomenon preceding a cancer-prone state (7,8). In contrast, some researchers hypothesize that PJS polyps follow the hamartoma-carcinoma sequence, leading to a high risk of malignancy (3,7). Three of the family members studied here had hamartoma polyps that were confirmed histologically, but one only had inflammatory polyps. One family member had hamartomatous polyps that were confirmed histologically and eventually died of lung adenocarcinoma. Inflammatory polyps, hamartomatous polyps, and lung adenocarcinoma were found in one family. Thus, PJS polyps may follow the hamartoma-carcinoma sequence. A further follow-up study of this family is needed to prove this hypothesis.

Further screening for the *STK11/LKB1* gene mutation should help to evaluate the risk of malignant transformation in two young survivors (9). However, both patients refused genetic testing. Clearly, a close follow-up with physical examinations and endoscopy is recommended.

References

1. Beggs AD, Latchford AR, Vasen HF, *et al.* Peutz-Jeghers syndrome: A systematic review and recommendations for management. *Gut.* 2010; 59:975-986.
2. Giardiello FM, Trimbath JD. Peutz-Jeghers syndrome and management recommendations. *Clin Gastroenterol Hepatol.* 2006; 4:408-415.
3. van Lier MG, Wagner A, Mathus-Vliegen EM, Kuipers EJ, Steyerberg EW, van Leerdam ME. High cancer risk in Peutz-Jeghers syndrome: A systematic review and surveillance recommendations. *Am J Gastroenterol.* 2010; 105:1258-1264.
4. Kopacova M, Tacheci I, Rejchrt S, Bures J. Peutz-Jeghers syndrome: Diagnostic and therapeutic approach. *World J Gastroenterol.* 2009; 15:5397-5408.
5. Oncel M, Remzi FH, Church JM, Connor JT, Fazio VW. Benefits of 'clean sweep' in Peutz-Jeghers patients. *Colorectal Dis.* 2004; 6:332-335.
6. Higham P, Alawi F, Stoopler ET. Medical management update: Peutz Jeghers syndrome. *Oral Surg Oral Med Oral Pathol Oral Radiol Endod.* 2010; 109:5-11.
7. Retrosi G, Nanni L, Vecchio FM, Manzoni C, Canali R, Busato G, Pintus C. Solitary Peutz-Jeghers polyp in a paediatric patient. *Case Rep Gastroenterol.* 2010; 4:452-456.
8. Jansen M, de Leng WW, Baas AF, Myoshi H, Mathus-Vliegen L, Taketo MM, Clevers H, Giardiello FM, Offerhaus GJ. Mucosal prolapse in the pathogenesis of Peutz-Jeghers polyposis. *Gut.* 2006; 55:1-5.
9. Syngal S, Brand RE, Church JM, Giardiello FM, Hampel HL, Burt RW. ACG clinical guideline: Genetic testing and management of hereditary gastrointestinal cancer syndromes. *Am J Gastroenterol.* 2015; 110:223-262; quiz 263.

(Received September 12, 2015; Revised October 28, 2015; Accepted November 9, 2015)

A rare case of giant vaginal fibromyoma

Mona Asnani^{1,*}, Kumkum Srivastava¹, Hem Prabha Gupta¹, Shipra Kunwar¹, A N Srivastava²

¹Department of Obstetrics & Gynaecology, Era's Lucknow Medical College, Lucknow, U.P., India;

²Department of Pathology, Era's Lucknow Medical College, Lucknow, U.P., India.

Summary Vaginal fibroids rarely exist as a primary vaginal tumor. Approximately 300 cases have been reported in the literature. Here we are reporting a rare case of giant vaginal fibromyoma. It was diagnosed as cervical fibroid polyp preoperatively but found to be vaginal fibromyoma peroperatively.

Keywords: Vaginal fibromyoma, hysterectomy

1. Introduction

Leiomyomas are the most common benign tumors of the uterus. However vaginal myomas are very rare and may be confused with a variety of vaginal tumors. Approximately 300 cases have been reported in the literature (1). Vaginal fibromyomas are usually asymptomatic but variable symptoms can be present depending on site including lower abdominal pain, low back pain, vaginal bleeding, dyspareunia, urinary symptoms like frequency, dysuria or other features of urinary obstruction (2). Here we are reporting a case of giant vaginal fibromyoma which was diagnosed preoperatively as cervical leiomyoma.

2. Case report

A 30-year-old nulliparous female admitted to our hospital on 19th March 2015 with complaints of oligomenorrhea for the last year and purulent discharge per vaginum for the past six months. Her cycles were of 55-60 days with a two day duration with reduced flow. On examination a lump was present in infraumbilical region. Size of lump was almost equal to 18 weeks of gestational uterus.

Slight foul smelling discharge was detected on local examination. Speculum examination showed free flowing excessive purulent discharge. A huge mass was found high up in the vagina which almost occupied

the whole upper vagina. On bimanual examination a huge mass was felt high up in vagina which was firm in consistency. Uterus could not be felt separately from the mass. Ultrasonography showed bulky cervix. A heterogeneously hypoechoic space occupying lesion was found in endocervical canal with minimal increased vascularity suggestive of cervical fibroid polyp (7.2 × 4.4 cm).

Diagnosis of cervical fibroid polyp was made. Patient was prepared for polypectomy by vaginal route under antibiotic coverage. Her operation was performed on 4th April 2015. Procedure could not be done vaginally as pedicle of fibroid polyp could not be accessed vaginally. On laparotomy, uterus and adnexa were visualized and found to be normal. Vagina was found to be ballooned up. Uterovesical fold of peritoneum was incised, bladder was pushed down and anterior vaginal wall at cervicovaginal junction was opened. A sessile fibroid polyp was present in the vagina. A fibroid polyp base of around 4-5 cm was attached to anterior vaginal wall. Due to excessive bleeding peroperatively a decision of hysterectomy was taken with consent of the attendant. After achieving hemostasis, base of vaginal fibromyoma was serially clamped and was removed subsequently.

Gross pathological examination reported a single globular soft tissue piece measuring 12.5 × 10.8 cm with outer surface appearing grey white and one end showing grey white growth measuring 5.5 × 5.5 cm (Figure 1). The cut surface showed a whorled appearance. Microscopic examination reported fascicles and interlacing bundles of smooth muscle cells showing elongated to oval nuclei with eosinophilic cytoplasm, the section also showed hypercellular and myxoid areas. Intervening stroma showed mild to moderate

Released online in J-STAGE as advance publication November 20, 2015.

*Address correspondence to:

Dr. Mona Asnani, Department of Obstetrics & Gynaecology, Era's Lucknow Medical College, Lucknow, U.P., India.

E-mail: drdkbajaj@rocketmail.com

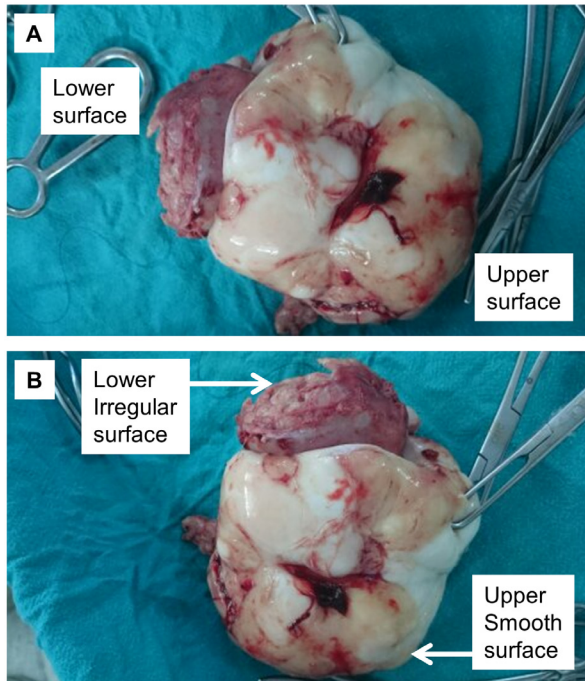


Figure 1. Gross appearance of vaginal fibromyoma. (A), showing upper surface which was attached to vaginal wall; **(B),** lower surface of vaginal fibromyoma with irregular margins.

inflammatory infiltrates comprised of lymphocytes, and polymorphs with few plasma cells (Figure 2). Immunohistochemical analysis for CD34, CD117 and DOG1 was found to be negative.

3. Discussion

Leiomyomas are mainly tumors of myometrium although they can occur in round ligament, broad ligament, urinary bladder, renal pelvis, spermatic cord, glans penis, urethra and even in peritoneum (3). Most common site of vaginal leiomyomas is anterior vaginal wall (4) followed by lateral wall (5). They may also arise from posterior wall (6). It can also cause obstruction to birth passage if present along with pregnancy (7).

Twenty-six patients of vaginal leiomyoma were analyzed by Zhao Y *et al.* retrospectively. S-P immunohistochemistry was used to detect smooth muscle actin (SMA), S-100 protein (calcium binding protein), CD34 (cluster of differentiation 34), ER (Estrogen receptor) and EGFR (Epidermal growth factor receptor). Immunohistochemical staining demonstrated them to be strongly positive for SMA, and negative for S-100 protein and CD 34 in all cases, positive expression of ER and EGFR was 38.5 (10/26) and 34.6 (9/26) respectively. There was significant correlation between expression of ER and EGFR. They concluded that estrogen hormone and EGF (epidermal growth factor) might play an important role in development and growth of leiomyoma of vagina (8).

Preoperative diagnosis can be made by

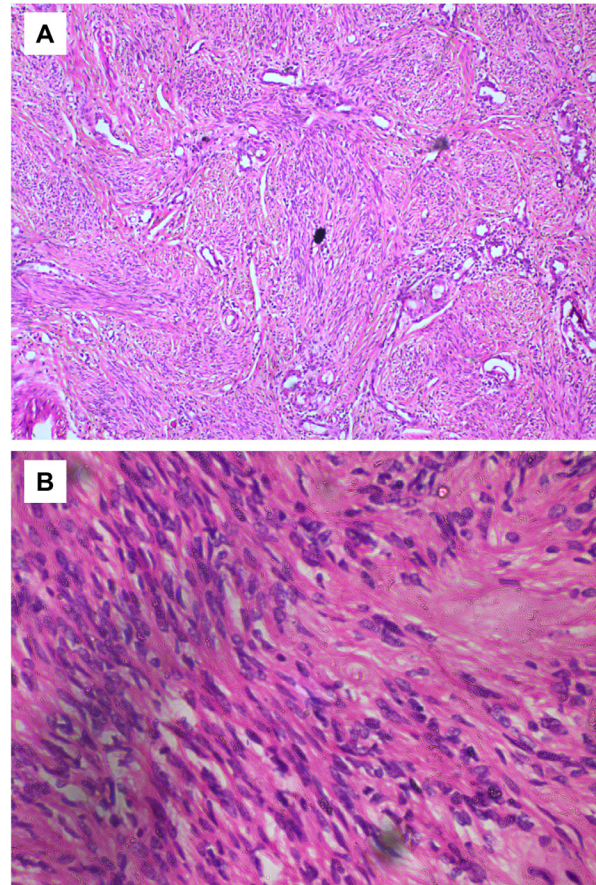


Figure 2. Microscopic appearance of vaginal fibromyoma showing fascicles and interlacing bundles of smooth muscle cells. (A), fibroid 10 × 0001; **(B),** fibroid 40 × 0002 hyaline.

ultrasonography but is better delineated with magnetic resonance imaging. In MRI (magnetic resonance imaging) they appear as homogenous lesions with signal similar to myometrium (9). In this case ultrasonography showed cervical leiomyoma.

MRI usually clinches the diagnosis of vaginal fibromyoma. In MRI they appear as well demarcated solid masses of low signal intensity in T1 and T2 weighted images with homogenous contrast enhancement while leiomyosarcoma and other vaginal malignancies show characteristic high T2 signal intensity with irregular and heterogenous areas of necrosis or hemorrhage (9,10) MRI could not be done, because the patient could not afford the investigation.

Surgical removal is the treatment of choice. Vaginal approach is usually feasible but at times abdominoperineal approach may be required to complete the excision in large tumors (11). If diagnosis could be made preoperatively, gonadotrophin releasing hormone (GnRH) analogue can be tried to reduce their size (3,12) or preoperative embolization can be performed before excision to reduce intraoperative blood loss (13).

Sim CH *et al.* (14) reported a case of necrotising ruptured vaginal leiomyoma which was preoperatively diagnosed as vaginal malignancy. MRI revealed a

mass of 7×5 cm at distal end on left anterior aspect of vagina with its low signal intensity of T1 weighted image, high signal intensity on T2 weighted image. Antibiotics were given for 10 days, and subsequently the patient underwent excision of mass through vaginal approach.

Liu (15) analyzed 11 vaginal leiomyomas and their average time to become symptomatic was 8.4 years with an incidence of 9.1% for malignant change.

4. Conclusion

We should learn from this case that we should always make a sure diagnosis by MRI whenever there is such a huge mass in the vagina. GnRH analogues can also be given to reduce the size of fibromyoma preoperatively. In this case we could not give GnRH analogues as the mass was so infected that we could not postpone the procedure.

Acknowledgements

The authors want to thank the patient for her cooperation.

References

1. Young SB, Rose PG, Reuter KL. Vaginal fibromyomata: Two cases with preoperative assessment, resection and reconstruction. *Obstet Gynecol.* 1991; 78:972-974.
2. Cobanoğlu O, Gürkan Zorlu C, Ergun Y, Kutluay L. Leiomyosarcoma of the vagina. *Eur J Obstet Gynecol Reprod Biol.* 1996; 70:205-207.
3. Theodoridis TD, Zepiridis L, Chatzigeorgiou KN, Papanicolaou A, Bontis JN. Vaginal wall fibroid. *Arch Gynecol Obstet.* 2008; 278:281-282.
4. Elsayes KM, Narra VR, Dillman JR, Velcheti V, Hameed O, Tongdee R, Menias CO. Vaginal masses: Magnetic resonance imaging features with pathologic correlation. *Acta Radiol.* 2007; 48:921-933.
5. Yogesh K, Amita M, Rajendra K, Raju A, Rekha W, Hemant T. Vaginal leiomyoma developing after hysterectomy - case report and literature review. *Aust N Z J Obstet Gynaecol.* 2005; 45:96-97.
6. Gupta V, Arya P, Gupta V, Rawat DS. A Rare case of vaginal fibroid presenting as ovarian tumor. *J Obstet Gynecol India.* 2006; 56:537-538.
7. Lucas J, Dreyfus M, Bekkari Y. Surgical management during labor of giant vaginal fibromyoma. *J Gynecol Surg.* 2004; 20:17-19.
8. Zhao Y, Li Y, Xu Y. Clinico-pathological analysis of 26 cases of leiomyoma of the vagina. *Beijing Da Xue Xue Bao.* 2003; 35:37-40. (in Chinese)
9. Shadbolt CL, Coakley FV, Qayyum A, Donat SM. MRI of vaginal leiomyomas. *J Comput Assist Tomogr.* 2001; 25:355-357.
10. Bae JH, Choi SK, Kim JW. Vaginal leiomyoma: A case report and review of literature. *J Women's Med.* 2008; 1:92-94.
11. Gowri R, Soundararaghavan S, Oumachigui A, Sistla SC, Iyengar KR. Leiomyoma of the vagina: An unusual presentation. *J Obstet Gynecol Res.* 2003; 29:395-398.
12. Park SJ, Choi SJ, Han KH, Park KH, Chung H, Song JM. Leiomyoma of the vagina that caused cyclic urinary retention. *Acta Obstet Gynecol Scand.* 2007; 86:102-104.
13. Bapuraj JR, Ojili V, Singh SK, Prasad GR, Khandelwal N, Suri S. Preoperative embolization of a large vaginal leiomyoma: Report of a case and review of the literature. *Australas Radiol.* 2006; 50:179-182.
14. Sim CH, Lee JH, Kwak JS, Song SH. Necrotising ruptured vaginal leiomyoma mimicking a malignant neoplasm. *Obstet Gynecol Sci.* 2014; 57:560-563.
15. Liu MM. Fibromyoma of the vagina. *Eur J Obstet Gynecol Reprod Biol.* 1988; 2:321-328.

(Received September 15, 2015; Revised October 28, 2015; Accepted November 9, 2015)

Spontaneous rectus sheath hematoma in a patient treated with apixaban

Halil Aktas, Sinan Inci*, Pinar Dogan, Ibrahim Izgu

Department of Cardiology, Aksaray State Hospital, Aksaray, Turkey.

Summary Apixaban, a non-vitamin K antagonist oral anticoagulants, is a Factor Xa inhibitor that is prescribed for the treatment of non valvular atrial fibrillation. Rectus sheath hematoma is a rare but significant complication of oral anticoagulant treatment. The important causes of rectus sheath hematoma include treatment with anticoagulants, hematologic diseases, trauma, intense physical activity, coughing, sneezing and pregnancy. In this report, we describe case of a 71-year-old woman undergoing apixaban treatment for non valvular atrial fibrillation who presented with spontaneous rectus sheath hematoma.

Keywords: Apixaban, oral anticoagulant, rectus sheath hematoma

1. Introduction

In recent years, new oral anticoagulants are used as the alternatives of warfarin in non-valvular atrial fibrillation (1). Apixaban is a directly absorbed, competitive Factor Xa inhibitor with an extremely fast-onset action profile. An additional advantage to the use of apixaban is that it is not reported to adversely interact with any known drug. When compared to warfarin, therapeutic intervention with apixaban (2 × 5 mg dose) has been found to be significantly more efficacious in the treatment of non valvular atrial fibrillation; use of apixaban is strongly associated with a marked decrease in the incidence of stroke, formation of systemic emboli, major bleeding, intracranial bleeding, death and common end (2). Unfortunately, unlike warfarin, apixaban has no known antidote available for therapeutic use hence bleeding, following apixaban treatment, is considered as a major complication and is often difficult to manage. Formation of rectus sheath hematoma is one such severe complication that requires a close follow up as it is associated with a high risk of mortality.

In this communication, we have presented a unique case regarding spontaneous development of rectus

sheath hematoma following apixaban treatment. To our knowledge such an occurrence has not been previously reported in literature.

2. Case report

A 71-year-old female patient with a history of atrial fibrillation and coronary artery disease was referred to the cardiology clinic following complaints of abdominal pain and dyspnea for the last 24 hours. It was also noted that she had been suffering from a cough for the past one week as a result of an upper respiratory tract infection. The patient's blood pressure was recorded as 100/60 mmHg, heart rate was arrhythmic at 94 beats/min. The patient's body weight is 70 kg. On physical examination, it was noticed that she had a tender, hard, colorless soft tissue swelling located on the left side of the umbilicus. Laboratory evaluation revealed mild anemia (Hb: 11.5 mg/dL) as well as renal function impairment [blood urea: 79.6 mg/dL, creatinine: 1.83 mg/dL, predicted Glomerular Filtration Rate (GFR): 33 mL/min]. Results of other laboratory tests were within normal acceptable limits. As a result of the patient's impaired renal function, computed tomography with contrast was ruled out as a diagnostic option and it was decided to employ emergent abdominal ultrasonography (USG) instead. USG revealed the presence of a left sided rectus sheath hematoma measuring 11 × 7.5 × 3 cm in size (Figure 1).

As part of a treatment module for her non valvular atrial fibrillation, the patient had been using apixaban at a dose of 10 mg/day (2 × 5 mg) for the past three

Released online in J-STAGE as advance publication December 14, 2015.

*Address correspondence to:

Dr. Sinan Inci, Aksaray State Hospital, zafer mah. Nevşehir cad. No:117, Aksaray, Turkey.

E-mail: doktorsinaninci@gmail.com

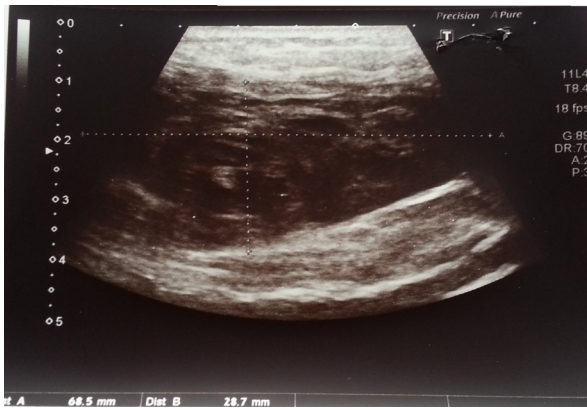


Figure 1. Left sided rectus sheath hematoma on abdominal USG.

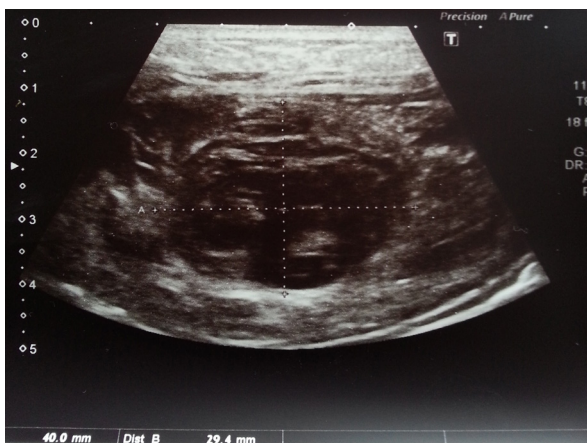

Figure 2. Regression of size of the hematoma on abdominal USG in the follow-up.

months. She had no history of trauma, had not undergone any surgical procedure and had not been prescribed any other drug that could account for the bleeding and hematoma formation. For relieving symptoms of upper respiratory tract infection the patient was taking suitable antibiotics and drugs. Her daily drug schedule was as follows: diltiazem 120 mg *b.i.d.*, digoxin 0.125 mg/day and furosemide 40 mg/day. Her CHADS-VASc score was 3 (Age one point, Coronary artery disease one point and Female one point) with a HASBLED score of 2.

The patient was moved to intensive care unit (ICU) and apixaban treatment was instantly stopped. Intravenous fluid resuscitation was commenced and vital signs such as blood pressure, heart rate, respiratory rate and pulse oxygen saturation were constantly monitored. Hemoglobin values were regularly controlled and showed no significant decrease during the course of follow up analysis. Two days following intervention, the abdominal USG revealed regression of the rectus sheath hematoma (size: 4 × 3 cm) (Figure 2). Apixaban treatment was reinstated 5 days later with a reduced dose of 5 mg/day (2 × 2.5 mg). The patient was discharged from the hospital and asked to revisit for follow-up after

a period of one week. A week later she underwent routine examination at the clinic but no medical complaint, symptom of hematoma or any other complication was detected.

3. Discussion

Unlike warfarin, treatment with apixaban does not necessitate an INR follow up. This is one of the primary reasons for the increased use of apixaban and other novel oral anticoagulants in the treatment of non valvular atrial fibrillation. A severe drawback associated with this issue is the increased incidence of bleeding related complications. The situation is further complicated by the absence of specific antidotes to these oral anticoagulants; this makes management of above mentioned bleeding complications extremely difficult because only follow up supportive treatment can be offered to the patient (3). The half life of apixaban is 12 hours and about 25% of the drug is renally excreted (4). For this reason supportive treatment and follow up of apixaban treated patients is very crucial. In our case, the patient had been receiving apixaban (daily dose: 2 × 5 mg) for treatment of non valvular AF for a period of 3 months.

Rectus sheath hematoma is a rare but significant complication of oral anticoagulant treatment. The important etiological causes of rectus sheath hematoma include anticoagulant treatment, hematologic diseases, trauma, intense physical activity, coughing, sneezing and pregnancy (5). Older patients, because of their deteriorating physical status, are especially vulnerable to rectus sheath weakness. Under such conditions, it is imperative to diagnose early, immediately evaluate and begin treatment so as to prevent the occurrence of severe complications including hemodynamic instability, abdominal compartment syndrome, multi-organ dysfunction and even death. The main strategy for treatment is discontinuation of the responsible drug, regular hemoglobin follow up, fluid replacement and blood transfusion as and when required. Our patient was predisposed to the formation of rectus sheath hematoma as a result of her advanced age and her week-long cough attack. Upon diagnosis we immediately terminated apixaban treatment and commenced fluid replacement. In the ICU, hemoglobin controls were obtained and vital signs were rigorously monitored. In our case no blood transfusion was required as the hemoglobin values were stable. Control USG revealed that the hematoma was decreasing in size as a result of the steps outlined above.

Factors that increase the tendency to bleed while undergoing apixaban treatment are well documented in literature. Some of the most important risk factors include advanced age, a history of bleeding, stroke or transient ischemic attack, diabetes, decreased creatinine clearance and drug use (6). Although it has

been previously reported that with conventional oral anticoagulant use, there is a decreased incidence of bleeding among patients with mild renal impairment (50-80 mL/min), this is not applicable for patients suffering from moderate and severe renal impairment (GFR < 50 mL/min) (7). In our case the patient suffered from renal function impairment (GFR: 33 mL/min) and this, in our opinion, might have increased the risk of bleeding. Reduced apixaban doses (2 × 2.5 mg/day) are suggested in patients with two or more of the following criteria: The age being ≥ 80 years, the body weight being ≤ 60 kg, or the serum creatinine level being ≥ 1.5 mg/dL (2). In our case the patient had one criteria (the serum creatinine level was ≥ 1.5 mg/dL). However, it is well known that the risk of hemorrhage increases in patients with renal dysfunction (6,7). In addition, the concomitant use of apixaban and strong dual inhibitors of P-gp and CYP3A4 are not recommended, or the dose must be reduced (8). Diltiazem is a moderate inhibitor of dual P-gp and CYP3A4, and increases plasma concentration of apixaban (9). In our case the patient had renal dysfunction, major/mortal bleeding like rectus sheath hematoma, and was receiving concomitant diltiazem therapy, therefore we reduced the apixaban dosage (2 × 2.5 mg/day).

Drug interaction with apixaban treatment is a rare phenomenon but a recent study has reported that ketoconazole and diltiazem are observed to increase plasma concentration of apixaban (9). In direct relation to the aforementioned findings, our patient was undergoing diltiazem therapy along with apixaban and this drug interaction might have impacted the tendency to bleed.

In literature there are documented cases that report the formation of muscle hematomas following anticoagulant or anti-platelet therapy (10). To our knowledge, only two reports that associated the formation of rectus sheath hematoma with use of the new oral anticoagulant rivaroxaban are known (3,11). Our case report is the first of its kind to highlight the association between apixaban treatment and formation of rectus sheath hematoma.

In conclusion, patients on apixaban therapy who complain of abdominal pain must always be evaluated for formation of rectus sheath hematoma. Upon diagnosis appropriate treatment modalities must be immediately planned and executed.

References

1. Heidbuchel H, Verhamme P, Alings M, Antz M, Hacke W, Oldgren J, Sinnaeve P, Camm AJ, Kirchhof P; European Heart Rhythm Association. European Heart Rhythm Association Practical Guide on the use of new oral anticoagulants in patients with non-valvular atrial fibrillation. *Europace*. 2013; 15:625-651.
2. Granger CB, Alexander JH, McMurray JJ, *et al*. Apixaban versus warfarin in patients with atrial fibrillation. *N Engl J Med*. 2011; 365:981-992.
3. Kocayigit I, Can Y, Sahinkus S, Aydin E, Vatan MB, Kilic H, Gunduz H. Spontaneous rectus sheath hematoma during rivaroxaban therapy. *Indian J Pharmacol*. 2014; 46:339-340.
4. Raghavan N, Frost CE, Yu Z, He K, Zhang H, Humphreys WG, Pinto D, Chen S, Bonacorsi S, Wong PC, Zhang D. Apixaban metabolism and pharmacokinetics after oral administration to humans. *Drug Metab Dispos*. 2009; 37:74-81.
5. Cherry WB, Mueller PS. Rectus sheath hematoma: Review of 126 cases at a single institution. *Medicine (Baltimore)*. 2006; 85:105-110.
6. Hylek EM, Held C, Alexander JH, Lopes RD, De Caterina R, Wojdyla DM, Huber K, Jansky P, Steg PG, Hanna M, Thomas L, Wallentin L, Granger CB. Major bleeding in patients with atrial fibrillation receiving apixaban or warfarin: The ARISTOTLE Trial (Apixaban for Reduction in Stroke and Other Thromboembolic Events in Atrial Fibrillation): Predictors, Characteristics, and Clinical Outcomes. *J Am Coll Cardiol*. 2014; 63:2141-2147.
7. Pathak R, Pandit A, Karmacharya P, Aryal MR, Ghimire S, Poudel DR, Shamoun FE. Meta-analysis on risk of bleeding with apixaban in patients with renal impairment. *Am J Cardiol*. 2015; 115:323-327.
8. Hellwig T, Gulseth M. Pharmacokinetic and pharmacodynamic drug interactions with new oral anticoagulants: What do they mean for patients with atrial fibrillation? *Ann Pharmacother*. 2013; 47:1478-1487.
9. Frost CE, Byon W, Song Y, Wang J, Schuster AE, Boyd RA, Zhang D, Yu Z, Dias C, Shenker A, LaCreta F. Effect of ketoconazole and diltiazem on the pharmacokinetics of apixaban, an oral direct factor Xa inhibitor. *Br J Clin Pharmacol*. 2015; 79:838-846.
10. Cakar MA, Kocayigit I, Aydin E, Demirci H, Gunduz H. Clopidogrel-induced spontaneous pectoral hematoma. *Indian J Pharmacol*. 2012; 44:526-527.
11. Tas Tuna A, Palabiyik O, Beyaz SG. Retracted: Spontaneous rectus sheath haematoma associated with rivaroxaban treatment. *J Clin Pharm Ther*. 2015; 40:486-488.

(Received October 6, 2015; Revised November 10, 2015; Accepted November 30, 2015)

Coexistence of tinnitus and hyperacusis in individuals with auditory dys-synchrony: A single case study

K. N. Megha, Sugathan Adithya, K. P. Keerthana, Sreeraj Konadath*

All India Institute of Speech and Hearing, Manasagangothri, Mysuru, India

Summary

Certain clinical pathologies affecting the ear and hearing mechanism may co-exist. It is necessary to probe in detail into such conditions so that the pathophysiology is well understood. This research paper through a single case study tries to explain the probable pathophysiology behind coexistence of three different clinical conditions namely auditory dys-synchrony, hyperacusis and tinnitus. These conditions are common in the clinics, but the coexistence of all the three is rare and demands explanation beyond what is available in the literature. The assumed model highlights involvement of the outer hair cell's motor function in the cochlea along with the auditory central gain mechanism to explain possible pathophysiology behind coexistence of the three conditions. This model will provide insight into the probable link between the contribution of peripheral and central structures of hearing in generating tinnitus and hyperacusis in individuals having auditory dys-synchrony.

Keywords: Auditory dys-synchrony, tinnitus, hyperacusis

1. Introduction

Communication and exchange of information is an important part of our everyday lives. Having a hearing loss can significantly impact a person's ability to communicate with others, leading to a reduced quality of life. People with hearing loss face difficulties in their emotional, social and physical well-being (1). There are different types of hearing loss namely conductive, sensorineural and mixed hearing loss, each of which has different effects on living. Sensorineural hearing loss happens due to mutilation in the cochlea, that is the inner ear, or to the nerve pathways from the inner ear to the brain (2). Auditory dys-synchrony/neuropathy (AN/AD) is a hearing impairment where outer hair cell amplification is normal, but auditory pathway's afferent neural conduction is disordered (3). The diagnosis is based on the integrity revealed by the presence of oto-acoustic emission by the outer hair cell, absence or severe abnormality of the auditory brainstem responses, impaired speech perception and acoustic middle ear

reflexes showing absence of responses or marked elevation (4). 1 in 200 hearing impaired children had an audiological indication of dys-synchrony (5). In individuals with sensorineural hearing loss in Mysore, the prevalence was around 1 in 183 (6). Most of the individuals with auditory dys-synchrony reported difficulty in understanding speech, and tinnitus was found to be one of the complaints (6,7). It was reported that 50% of individuals with auditory dys-synchrony had bilateral tinnitus (6).

Tinnitus is described as a conscious expression of a sound which instigates in an involuntary manner in the head of its owner, or might appear to him to do so (8). It is due to over activity of the cochlear hair cells that leads to growth in the (spontaneous) firing rate of primary auditory nerve fibers. The generators of tinnitus are ideally located in the auditory pathway, and are explained using various theories like edge theory and discordant damage theory. Those present in the central auditory system are explained in terms of other studies like, the auditory pathway theory, the crosstalk theory, the limbic and autonomic nervous system, and the somatosensory system (9). Prevalence of tinnitus ranged between 4.4 and 15.1% in adults (10). Tinnitus can have a significant impact on our life, although most have learned to live with it. It can disturb concentration and cause sleeping problems, depression and stress. The incidence of hyperacusis is very high among individuals

Released online in J-STAGE as advance publication January 27, 2016.

*Address correspondence to:

Mr. Sreeraj Konadath, All India Institute of Speech and Hearing, Manasagangothri, Mysuru 570 006, India.
E-mail: sreerajkonadath@aiishmysore.in

with tinnitus; 40 and 86% of those who have tinnitus also have hyperacusis (11).

Hyperacusis is defined as an abnormal lowered tolerance to sound (12). Hyperacusis is an abnormally strong reaction occurring within the auditory pathways resulting from exposure to moderate sound; as a consequence, patients express reduced tolerance to supra-threshold sounds (13). As a result of compensatory increase in neural amplification in the auditory system which tries to compensate for a loss of sensory input from the cochlea tinnitus and hyperacusis might result (14). Lesions causing tinnitus could have some direct effect on the loudness perception that leads to a reduced uncomfortable loudness level (15).

The co-existence of auditory dys-synchrony, tinnitus and hyperacusis is very rare. This article provides information on the co-existence of all three conditions with the help of a case study outcome of an adult who was diagnosed as auditory dys-synchrony with tinnitus and hyperacusis. Also, it explains a hypothetical model to describe their co-existence.

2. Case report

2.1. Assessment

Evidence from the literature for the co-existence of all three conditions has not been reported. Because all three conditions are reported to All India Institute of Speech and Hearing (AIISH), it was necessary to find the reason for the occurrence of these conditions in the same person. The patient is a 24 year-old male who was previously diagnosed as having mild to moderately severe sensorineural hearing loss in both ears. The patient underwent different medications for the problems listed, even though no other non-medical treatments were taken.

The patient complained of reduced hearing sensitivity in both ears, difficulty understanding speech, severe tinnitus (continuous ringing type) and intolerance to sounds. However, the patient did not mention intolerance to specific sounds. The patient also had severe psychological issues due to continuous ringing tinnitus and also had sleep disturbances due to the same problem. He exhibited all these signs since 5 years old and had consulted many centers but failed to get a solution. Computed Tomography (CT) scan of the brain done at Bengaluru, India indicated calcified granuloma in left parietal lobe (5.6 × 4.1 cm) with no peri-lesional edema. The EEG results indicated no electrographic evidence of focal structural abnormality. Diagnosis from audiological evaluations done at different centers is given in Table 1.

Late Latency Potential (LLR) was done to find whether the patient is a candidate for cochlear implant or not because he was not benefiting from a hearing aid (combination device). The patient had undergone

Table 1. Summary of results of audiological evaluations done at different centers

Date (Center)	Provisional diagnosis
12/04/2011 (Centre 1)	Right ear: Mild SNHL Left ear: Moderate SNHL (raising pattern)
02/06/2011 (Centre 2)	Right ear: Moderate SNHL Left ear: Moderately severe SNHL
26/02/2012 (Centre 3)	Right ear: Moderate SNHL Left ear: Moderately severe SNHL Bilateral retro-cochlear pathology
27/08/2014 (Centre 4)	Right ear: Moderate SNHL Left ear: Moderate- Moderately severe SNHL

a hearing aid trial on January 9, 2015. Different combination devices were tested which included two programs. First program wherein only amplification was provided and the second program where only noise was given without amplification.

2.2. Diagnostic tests and interpretations

The diagnostic tests used in the present patient included pure-tone audiometry, auditory brainstem responses, otoacoustic emissions and middle ear reflexes. The patient underwent pure-tone audiometry on January 8, 2015 at AIISH. The diagnosis made was mild hearing loss in right ear and moderate sensorineural hearing loss in left ear (rising pattern audiogram) with auditory dys-synchrony and hyperacusis. Speech identification scores were poor and worsened in a speech in noise test (SPIN). The middle ear reflexes were absent with the presence of robust otoacoustic emissions. Auditory brainstem response (ABR) - site of lesion was performed and the results were absence of ABR for click stimulus at both 11.1 and 90.1 repetition rate. The results obtained in the evaluations done at AIISH are provided in Table 2.

There was absence of middle ear reflexes, otoacoustic emissions and ABR in this patient. This might be because of very few inner and outer hair cells remaining. If only outer hair cells remain, emissions are seen but without synchronous firing of the neural elements stemming from inner hair cells, which is the hallmark of AN/AD (16). As the patient complained of tinnitus, tinnitus evaluation was done and there was absence of residual inhibition in both ears. Tinnitus evaluation was done and frequency and pitch matching was done at 2,000 Hz at 80 dBHL and 750 Hz at 70 dBHL in right and left ear respectively. Uncomfortable level of loudness for speech stimulus was found to be > 90. However, the patient had a tolerance problem at higher frequencies when administered with Johnson's Hyperacusis test. The loudness discomfort levels were obtained and the Johnson's Hyperacusis Quotient (JHQ) was 50-74 which indicated moderate hyperacusis in both ears. The patient obtained a score of 84 when

Table 2. Summary of results of audiological evaluations done at AIISH

Date	Audiological evaluations	Results
08/01/2015	Pure-tone audiometry	Right ear: Mild hearing loss Left ear: Moderate sensorineural hearing loss
	Speech audiometry	Poor speech identification scores
	Immittance	Absence of reflexes in both ears
	Otoacoustic emissions	Presence of robust OAE's in both ears
	Auditory Brainstem Response (SOL)	Absence of ABR in both ears
	Tinnitus evaluation (Residual inhibition)	Absence of residual inhibition
09/01/2015	Tinnitus Handicap Inventory	Score:- 84 Impression: Catastrophic tinnitus
	Johnson's Hyperacusis Test	JHQ:- 50-74
11/03/2015	Pure-tone audiometry	Moderate sensorineural hearing loss in both ears
	Speech audiometry	Poor SIS scores
	Immittance	Absence of reflexes in both ears
	Otoacoustic emissions	Presence of robust OAE's
	LLR	Presence of LLR in both ears

administered the Tinnitus Handicap Inventory (17) and the impression made was catastrophic tinnitus.

The management option initially tried was a combination device. A combination device is a hearing aid with a built-in sound/noise generator for treating tinnitus. However, the performance using this device was not satisfactory as the patient also had auditory dys-synchrony. The patient was re-evaluated after 3 months and the pure-tone thresholds were slightly elevated. Both right and left ear had moderate sensorineural hearing loss. As the patient was not benefited by the hearing aids, LLR was done to check whether patient is a good candidate for cochlear implantation. The LLR was present in both ears for tone burst and also for speech stimulus.

3. Discussion

The results of the present study show that the patient had all the aforementioned clinical conditions co-existing. The possible reason for the co-existence is explained based on the pathophysiology of these conditions through a hypothetical model generated for the same (Figure 1). Starr *et al.*(4) in 1996 defined "auditory dys-synchrony as a condition to describe hearing loss characterized by normal or near normal hair cell function and absent or abnormal auditory function". The etiology can be at the junction between the cochlear branch of VIII nerve and the inner hair cell that is the synapse, the inner hair cell or at the VIII nerve itself (4,18) ((A) in Figure 1).

Auditory dys-synchrony is characterized by absent or abnormal ABR, presence of cochlear microphonics

(CM), and otoacoustic emissions (OAEs) (4,19-21). A normal middle ear function is reflected by normal outer hair cell function in the cochlea inferred through oto-acoustic emissions. But, in some patients who have normal otoacoustic emissions, there will be either absence of inner hair cells or compromised neural synchrony (4,18). In the organ of corti the outer hair cell's motile function is involved in both increasing the activity on the basilar membrane accompanying low intensity sound and with the fine tuning of the activity (22). The efferent fibers innervate the OHC from the central auditory system in large part, which will analyze the sound environment and will influence the cochlear function accordingly. The stereocilia and cuticular plate region has an active bidirectional transduction mechanism with the OHC. First, the mechanical energy applied to the hair bundle is transduced into electrochemical energy of receptor potential/current of the OHC to drive the hair bundle mechanically. The active mechanical force at the OHC hair bundle would push against the tectorial membrane and drive the organ of corti, conceivably reducing the mechanical damping associated with vibration of the organ of corti. This property of OHC gives rise to active/non-linear biomechanical behavior of the cochlea, and is highly vulnerable physiologically (23).

The mechanical response of the cochlea to the receptoneural signals by the IHC subsystem is to transmit the auditory information with high spatial and temporal resolution *via* the bulk of the afferent cochlear nerve channel to the higher centers of the brain. It has been determined that stereocilia of the outer hair cell are firmly rooted in the overlying tectorial membrane

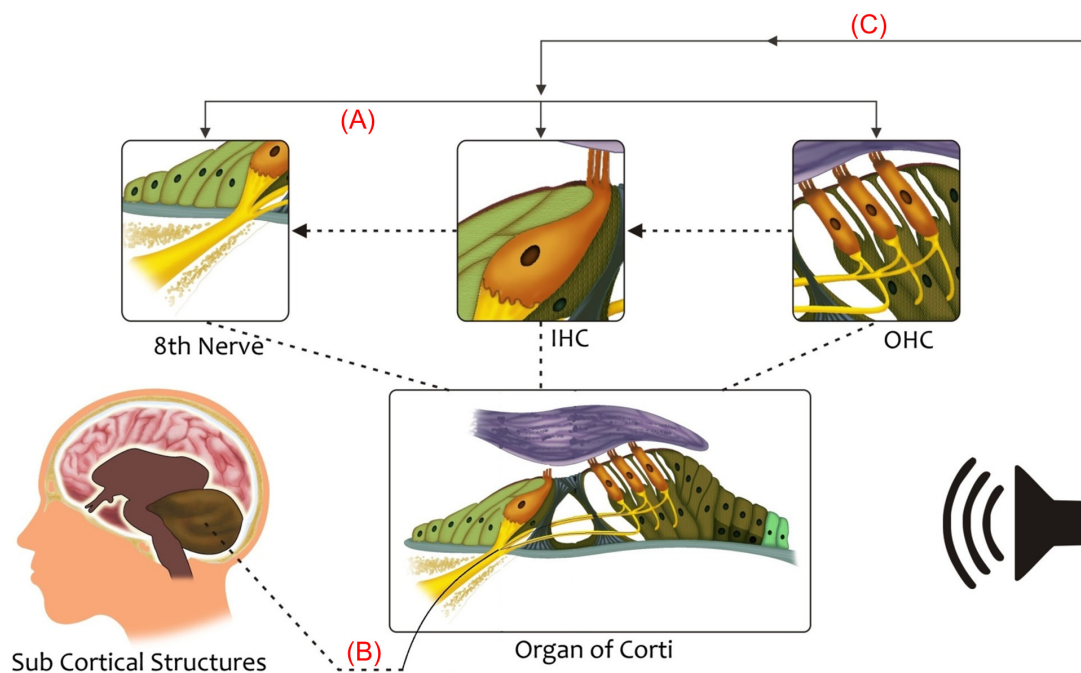


Figure 1. Hypothetical model to explain the co-existence of auditory dys-synchrony, hyperacusis and tinnitus based on their pathophysiology. Link 1 depicts the etiology leading to auditory dys-synchrony (which can be at the junction between the cochlear branch of VIII nerve and the inner hair cell that is the synapse, the inner hair cell or at the VIII nerve itself); link 2 represents hyperacusis (which arises due to compensation by central nervous system for a decrease in sensory input, by increasing the sensitivity of other centers involved in perception) and, link 3 represents tinnitus (due to both auditory dys-synchrony and hyperacusis, there is reduction in the central efferent suppression which leads to an increase in the gain of cochlear amplifier and results in tinnitus).

while the stereocilia of the inner hair cell make only a feeble connection. The basilar membrane is held below the inner hair cells while the outer hair cells are located near the center of the basilar membrane where vibrations will be greatest. This suggests that the resulting modulation of the ionic currents resulting from the movement of stereocilia is likely to be greater for outer hair cells than inner hair cells (23).

In the patient, there is co-existence of all the three conditions of auditory dys-synchrony, tinnitus and hyperacusis. Tinnitus, the perception of phantom sounds, and hyperacusis, the reduced tolerance for sounds, are often comorbid (12). Both hyperacusis and tinnitus arise from either sound-evoked or spontaneous hyperactivity in the auditory neural pathways. This reduction in peripheral neural activity occurs due to damage to sensory cells that reduces synaptic transmission to cochlear nerve terminals (24,25). It is suggested that tinnitus and hyperacusis, result from a maladaptation of the central auditory system to peripheral dysfunction, while triggered by cochlear damage (26). Both tinnitus and hyperacusis could be explained in terms of a central gain model.

4. Central gain mechanism

The neural activity transmitted from the cochlea to the central auditory system is reduced in sensorineural

hearing loss. Despite reduced output from the cochlea, there will be enhancement in neural activity in central auditory structures at suprathreshold levels (27). Tinnitus and hyperacusis, while triggered by cochlear damage, result from a maladaptation of the central auditory system to this peripheral dysfunction (26). As the feedback reaching from the central structures to the cochlea is not adequate, suppression will not take place and hence leads to over firing of the fibers. This is indicated through the outcomes from Oto-acoustic emissions which was robust for this patient.

Thus, central gain modulation is linked to loudness perception, which suggests that central gain enhancement may manifest as hypersensitivity to loudness, *i.e.*, hyperacusis. To support this, the uncomfortable level of loudness for speech stimulus was found to be > 90 and also moderate Hyperacusis in both ears as indicated in JHQ.

There was absence of middle ear reflexes and ABR in this patient which could be due to damage in the inner and outer hair cells. If only outer hair cells remain, emissions are seen, but without synchronous firing of the neural elements stemming from inner hair cells, which is seen in auditory dys-synchrony.

The compensatory increase in response to the loss of sensory input in the central auditory activity is referred to as central gain enhancement. According to the central gain mechanism, there will be recalibration of

mean firing rate activity of the central auditory system to a new "set-point" due to lack of sensory input, thus generating an amplification of neural noise, which will be perceived as tinnitus. Notably, this neuronal recalibration can result in an enhancement of incoming sensory signals, which may increase the loudness intolerance and hyperacusis which often accompanies hearing loss (27). Hence, the Central Gain Model accounts for both tinnitus and hyperacusis.

Thus, the possible reason for the coexistence of these three conditions is explained as follows. As there is auditory dys-synchrony, the feedback to the OHC from the central gain mechanism will be affected and there will be a greater firing rate and hence over excitation of OHC even for less intense sounds. There will be compensation by the central nervous system for a decrease in sensory input, by increasing the sensitivity of other centers involved in perception (28). This may lead to intolerance to sound termed as hyperacusis ((B) in Figure 1).

Due to both auditory dys-synchrony and hyperacusis, there is reduction in central efferent suppression. This leads to an increase in the gain of cochlear amplifier and results in over activity related symptoms like tinnitus ((C) in Figure 1). A study demonstrates that tinnitus is accompanied by a change of the tonotopic map in the auditory cortex. A marked shift of the tinnitus frequency to the adjacent area was observed in the tonotopic location. There is also a positive association between subjective strength and the amount of shift of the tinnitus frequency in the auditory cortex. The reorganizational changes occur in the auditory cortex with both increase and decrease in input (26).

One of the rehabilitation options available for this condition is combination devices. Combination devices are one of the best treatments for tinnitus and hearing impairment as these devices mask the tinnitus and also amplify the sound to overcome the loss of hearing sensitivity. As this was not beneficial for the patient a cochlear implant was recommended. There are many studies which suggest the use of cochlear implants for people with auditory neuropathy spectrum disorder as these devices improved synchronous activity in the auditory nerve and help improve speech perception (29-31).

Link 1 represents the pathophysiology of auditory dys-synchrony which can be at the level of inner hair cell, junction of the inner hair cell and the cochlear branch of VIII nerve or at the VIII nerve itself. Link 2 represents the dys-function in the central gain mechanism which is responsible for hyperacusis. Link 3 explains the reduction in central gain mechanism due to both auditory dys-synchrony and hyperacusis which further leads to tinnitus. As there is auditory dys-synchrony, the feedback to the OHC from the central gain mechanism will be affected and there will be a greater firing rate and hence over excitation of OHC

even for less intense sounds. The central nervous system will compensate for a decrease in sensory input, by increasing the sensitivity of other centers involved in perception. This may lead to intolerance to sound termed as hyperacusis. Due to both auditory dys-synchrony and hyperacusis, there is reduction in central efferent suppression, which leads to an increase in the gain of cochlear amplifier and results in over activity related symptoms like tinnitus.

In conclusion, the test results reported here of a single case study, imply that all three conditions can co-exist as the way it is explained in the hypothetical model based on their pathophysiology. Tinnitus and hyperacusis result from a compensatory increase in gain in the central auditory system to compensate for a loss of cochlear sensory input.

References

1. National Council on the Aging (NCOA): The Impact of Untreated Hearing Loss in Older Americans. Conducted by the Seniors Research Group. Supported through a grant from the Hearing Industries Association. Preliminary report. 1998.
2. American Speech-Language-Hearing Association. Type, Degree, and Configuration of Hearing Loss. Audiology Information series. ASHA. 2011; 7976-16.
3. Rance G. Auditory neuropathy/dys-synchrony and its Perceptual Consequences. Trends in Amplif. 2005; 9:1-43.
4. Starr A, Picton TW, Sininger Y, Hood LJ, Berlin CI. Auditory neuropathy. Brain. 1996; 119:741-753.
5. Davis H, Hirsh S K. The audiometric utility of brain stem responses to low-frequency sounds. Audiology. 1976; 15:181-195.
6. Kumar UA, Jayaram MM. Prevalence and audiological characteristics in individuals with auditory neuropathy/auditory dys-synchrony. Int J Audiol. 2006; 45:360-366.
7. Prabhu P, Avilala VKY, Manjula PP. Predisposing factors in individuals with late-onset auditory dys-synchrony. Asia Pac J Speech, Lang, Hear. 2012; 15:41-50.
8. McFadden D. Tinnitus: Facts, Theories and Treatments. Psychological Medicine. 1982; 13:699-699.
9. Han BI, Lee HW, Kim TY, Lim JS, Shin KS. Tinnitus: Characteristics, causes, mechanisms, and treatments. J Clin Neurol. 2009; 5:11-19.
10. Hoffman HJ, Reed GW. Epidemiology of tinnitus. In: Snow JB Jr, ed: Tinnitus: Theory and Management. Hamilton, Ontario: B.C. Decker, Inc. 2004; pp.16-41.
11. Møller AR. Tinnitus: presence and future. Prog Brain Res. 2007; 166:3-16.
12. Baguley DM. Hyperacusis, J R Soc Med. 2003; 96, 582-585.
13. Jastreboff MM, Jastreboff PJ. Hyperacusis, Audiology Online. <http://www.audiologyonline.com/articles/hyperacusis-1223> (accessed November 5, 2015)
14. Auo HJ, Park KH, Yeo SW, Chang KH, Choi HG, Choi BJ, Han MA, Park SN. Treatment response of modified tinnitus retraining therapy with medical therapy in the patients with tinnitus. Korean J Otorhinolaryngology-Head and Neck Surg. 2009; 52:648-654.
15. Tyler RS, Conrad-Arnes D. The determination of tinnitus loudness considering the effects of recruitment. J Speech

- Hear Res. 1983; 26:59-72.
16. Berlin CI, Morlet T, Hood LJ. Auditory neuropathy/dys-synchrony: The diagnosis and management. *Pediatr Clin North Am.* 2003; 50:331-340.
 17. Newman CW, Jacobson GP, Spitzer JB. Development of the tinnitus handicap inventory. *Arch Otolaryngol Head Neck Surg.* 1996; 122:143-148.
 18. Amatu MG, Northrop C, Liberman MC, Thornton A, Halpin C, Herrmann B, Pinto LE, Saenz A, Carranza A, Eavey RD. Selective inner hair cell loss in premature infants and cochlea pathological patterns from neonatal intensive care unit autopsies. *Arch Otolaryngol Head Neck Surg.* 2001; 127:629-636.
 19. Berlin CI, Hood LJ, Cecola RP, Jackson DF, Szabo P. Does type I afferent neuron dysfunction reveal itself through lack of efferent suppression? *Hear Res.* 1993; 65:40-50.
 20. Deltenre P, Mansbach AL, Bozet C, Christiaens F, Barthelemy P, Paulissen D, Renglet T. Auditory neuropathy with preserved cochlear micro-phonics and secondary loss of otoacoustic emissions. *Audiology.* 1999; 38:187-195.
 21. Rance G, Beer DE, Cone-Wesson B, Shepherd RK, Dowell RC, King AM, Rickards FW, Clark GM. Clinical findings for a group of infants and young children with auditory neuropathy. *Ear Hear.* 1999; 20:238-252.
 22. Wersinger E, Fuchs PA. Modulation of hair cell efferents. *Hear Res.* 2011; 279:1-12.
 23. Ruggero MA, Rich NC. Systemic injection of furosemide alters the mechanical response to sound of the basilar membrane. In: *The Mechanics and Biophysics of Hearing*, Eds: P. Dallos *et al*, Springer, Berlin. 1990; 87:314-321.
 24. Liberman MC, Dodds LW. Single-neuron labeling and chronic cochlear pathology. III. Stereocilia damage and alterations of threshold tuning curves. *Hear Res.* 1984; 16:55-74.
 25. Liberman MC, Kiang NY. Acoustic trauma in cats: Cochlear pathology and auditory-nerve activity. *Acta Otolaryngol Suppl.* 1978; 358:1-63.
 26. Mühlnickel W, Elbert T, Taub E, Flor H. Reorganization of auditory cortex in tinnitus. *Proc Natl Acad Sci U S A.* 1998; 95:10340-10343.
 27. Auerbach BD, Rodrigues PV, Salvi RJ. Central gain control in tinnitus and hyperacusis. *Front Neurol.* 2014; 5:206.
 28. Jastreboff PJ. Phantom auditory perception (tinnitus): mechanisms of generation and perception. *Neurosci Res.* 1990; 8:221-54.
 29. Fabry LB. Identification and management of auditory neuropathy: case study. In: Seewald RC, editor. *A sound foundation through early amplification: proceedings of an international conference.* Chicago: Phonak; 2000. pp. 237-245.
 30. Trautwein PG, Sininger YS, Nelson R. Cochlear implantation of auditory neuropathy. *J Am Acad Audiol.* 2000; 11:309-315.
 31. Shallop JK, Peterson A, Facer GW, Fabry LB, Driscoll CL. Cochlear implants in five cases of auditory neuropathy: Postoperative findings and progress. *Laryngoscope.* 2001; 111:555-562.

(Received November 6, 2015; Revised January 6, 2016; Accepted January 10, 2016)

Contact dermatitis after implantable cardiac defibrillator implantation for ventricular tachycardia

Pinar Dogan¹, Sinan Inci^{1,*}, Mevlut Serdar Kuyumcu², Ozgur Kus²

¹Department of Cardiology, Aksaray State Hospital, Aksaray, Turkey;

²Department of Cardiology, Yuksek Ihtisas Education and Research Hospital, Ankara, Turkey.

Summary

Pacemaker contact sensitivity is a rare condition. Less than 30 reports of pacemaker skin reactions have been described. We report a 57-year-old woman who underwent an implantable cardiac defibrillator (ICD) implantation for ventricular tachycardia. A skin patch test was positive on almost all components of the pacemaker system. She was treated with topical corticosteroids and skin lesions resolved within 2 weeks. Because of widespread use of various devices, we will see this more often and therefore it is important to recognize this problem and its effective management.

Keywords: Dermatitis, implantable cardiac defibrillator (ICD), skin patch test

1. Introduction

Contact dermatitis is an inflammatory response that appears from the contact of irritant or allergic substances to the skin. Contact dermatitis due to pacemaker devices is a rare clinical situation. There are possibilities of being not detected and being misdiagnosed because of negative skin tests. The most important step of the diagnosis is the skin patch test. The treatment management may also be problematic once the contact dermatitis is diagnosed (1). We have presented a case who had localized erythema development after an implantable cardiac defibrillator (ICD) implantation nearly 8 months ago, the ICD was removed from the patient and re-implanted, and the patient had contact dermatitis 24 hours after the re-implantation.

2. Case report

A 57-year-old woman was admitted to our hospital for replacement of an ICD for hypertrophic cardiomyopathy who had suffered ventricular tachycardia. Her medical history included an ICD implantation 8 months ago which had been removed for suspected pacemaker infection with localized erythema at the side of the

generator pocket one week after implantation. No bacterial infection had been found in microbiological screening tests. The patient underwent reimplantation successfully but within 24 hours of reimplantation localized erythema was limited within the border of the generator and pruritis occurred at the side of the generator pocket (Figure 1) as in the past described by the patient. This time the reaction occurred earlier than formerly and allergic contact dermatitis was suspected. She underwent patch testing that showed reaction to the various components of the pacemaker such as nickel, chromium, and titanium. Skin lesions resolved within 2 weeks with topical corticosteroids. After an 18-month follow-up, the patient is still asymptomatic.

3. Discussion

The first contact dermatitis case due to a permanent pacemaker device was reported by Rague and Golschmidt (2). There were several case presentations after this. Implantable loop recorder induced allergy has also been reported (3). Many allergens have been suspected to influence contact dermatitis due to permanent pacemakers, and it has been determined that the most frequent allergens are titanium and nickel. The duration of the appearance of symptoms has been reported to vary between 2 days and 2 years. However, the reaction generally appears within a few weeks after the implantation. According to the data obtained from the biopsy material, the pathophysiology includes a delayed hypersensitivity reaction (Type 3 - Type 4) (4-7).

*Address correspondence to:

Dr. Sinan Inci, Aksaray State Hospital, zafer mah.Nevşehir cad. No 117, Aksaray, Turkey.

E-mail: doktorsinaninci@gmail.com

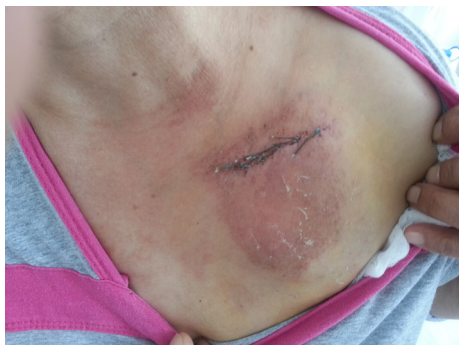

Figure 1. This photograph shows the skin reaction over the pacemaker after the second pacemaker implantation.

Clinical suspicion is the most important step in diagnosis of the cases. Complete blood count (hemogram) of the patient is generally normal; however, sometimes eosinophilia may be observed (8). The diagnosis is made with the skin patch test. It must be kept in mind that negative results will not exclude pacemaker contact dermatitis. A skin patch test following a pacemaker implantation may give negative results due to the antibiotics that are being used. The use of corticosteroids may also lead to wrong negative skin test results. This situation makes it difficult for diagnosis. The skin test results of 6 out of 17 patients were negative. They had reactions after pacemaker implantation and were treated successfully (4-6,9). The test that is used for titanium, which is the most-frequent allergic material, is not very reliable. Titanium tetrachloride, which is highly diluted and hydrolyzed in water, is used for this test (5). Some other methods such as electron probe microanalysis (EDAX) and a lymphocyte stimulation test have also been used for difficult diagnoses (6,9). In our case, although the reaction developed 24 hours after implantation, the skin test result was positive, and therefore the diagnosis was made easily.

The real treatment of contact dermatitis is removing the agent that causes the allergy. Although there are cases that react to topical steroids (6), treatment management is difficult in many cases. Long-term use of systemic steroids may be influential in difficult cases, but they are not recommended due to their side effects. Antihistaminic drugs may also be used to decrease symptoms. A device that does not contain allergic components and that is confirmed with a negative skin test may be used in cases that do not react to treatment. Another choice is the possible use of generators with non-allergic coatings. The recommended materials may be silicone (10), parylene, and gold (11). There have been some allergies reported for these materials in some cases as well (7). Kang *J et al.* reported three cases of a cardiac rhythm device induced contact dermatitis which

was treated by device extraction and reimplantation with another device without offending agent or coating with a non-allergenic substance (12). In our patient this is the second implantation of a device so we first tried to treat with topical corticosteroids and antihistaminics. Topical corticosteroids were applied twice daily at the side of the generator pocket. After treatment pruritus decreased first and localized erythema dissolved slowly within two weeks.

In conclusion, pacemaker contact dermatitis is a rare clinical condition. In some cases, diagnosis and treatment are difficult. Cardiologists should always keep pacemaker allergy in mind when a patient appears with wound complications.

References

1. Schnuch A, Uter W, Geier J, Gefeller O; IVDK study group. Epidemiology of contact allergy: An estimation of morbidity employing the clinical epidemiology and drug-utilization research (CE-DUR) approach. *Contact Dermatitis*. 2002; 47:32-39.
2. Raque C, Goldschmidt H. Dermatitis associated with an implanted cardiac pacemaker. *Arch Dermatol*. 1970; 102:646-649.
3. Hayes DL, Loesl K. Pacemaker component allergy: Case report and review of the literature. *J Interv Elect*. 2002; 6:277-278.
4. Brun R, Hunziker N. Pacemaker dermatitis. *Contact Dermatitis*. 1980; 6:212-213.
5. Verbov J. Pacemaker contact sensitivity. *Contact Dermatitis*. 1985; 12:173.
6. Viraben R, Boulinguez S, Alba C. Granulomatous dermatitis after implantation of a titanium-containing pacemaker. *Contact Dermatitis*. 1995; 33:437.
7. Iguchi N, Kasanuki H, Matsuda N, Shoda M, Ohnishi S, Hosoda S. Contact sensitivity to polychloroparaxylene-coated cardiac pacemaker. *Pacing Clin Electrophysiol*. 1997; 20:372-373.
8. Buchet S, Blanc D, Humbert P, Girardin P, Vigan M, Anguenot T, Agache P. Pacemaker dermatitis. *Contact Dermatitis*. 1992; 26:46-47.
9. Yamauchi R, Morita A, Tsuji T. Pacemaker dermatitis from titanium. *Contact Dermatitis*. 2000; 42:52-53.
10. Abdallah HI, Balsara RK, O'Riordan AC. Pacemaker contact sensitivity: Clinical recognition and management. *Ann Thorac Surg*. 1994; 57:1017-1018.
11. Déry JP, Gilbert M, O'Hara G, Champagne J, Desaulniers D, Cartier P, Philippon F. Pacemaker contact sensitivity: Case report and review of the literature. *Pacing Clin Electrophysiol*. 2002; 25:863-865.
12. Kang J, Simpson CS, Campbell D, Borici-Mazi R, Redfearn DP, Michael KA, Abdollah H, Baranchuk A. Cardiac rhythm device contact dermatitis. *Ann Noninvasive Electrocardiol*. 2013; 18:79-83.

(Received November 6, 2015; revised January 24, 2016; Accepted January 25, 2016)

A large spontaneous intrahepatic portosystemic shunt in a cirrhotic patient

Xingshun Qi^{1,*}, Chun Ye², Yue Hou¹, Xiaozhong Guo^{1,*}

¹Liver Cirrhosis Study Group, Department of Gastroenterology, General Hospital of Shenyang Military Area, Shenyang, China;

²Department of General Surgery, General Hospital of Shenyang Military Area, Shenyang, China.

Summary A spontaneous portosystemic shunt is a rare malformation of the vessels supplying the liver. This condition often leads to the development of hepatic encephalopathy due to excessive shunting of blood from the portal vein to the inferior vena cava. Some studies have suggested that the presence of spontaneous portosystemic shunts is inversely associated with the appearance of large esophageal varices. Spontaneous intrahepatic portosystemic shunts (SIPSS) are far less frequently observed than extrahepatic portosystemic shunts, which include spleno-gastric-renal shunts, mesenteric-caval shunts, and a large patent umbilical vein. Reported here is a case of decompensated liver cirrhosis with a large SIPSS without any incidence of overt hepatic encephalopathy.

Keywords: Spontaneous intrahepatic portosystemic shunt; liver cirrhosis; hepatic encephalopathy; embolization

1. Introduction

A spontaneous portosystemic shunt is a rare malformation of the vessels supplying the liver that can lead to the development of hepatic encephalopathy (HE) due to excessive shunting of blood from the portal vein to the inferior vena cava (1-2). That said, a study has indicated that patients with spontaneous portosystemic shunts had significantly fewer large esophageal varices than those without such shunts (3). Color Doppler ultrasound and computed tomography are the first-line imaging modalities that are used to diagnose a spontaneous portosystemic shunt. Angiography should be the gold standard for diagnosis of those shunts. Depending on the location of the shunt, spontaneous portosystemic shunts primarily include extrahepatic and intrahepatic shunts. Spontaneous intrahepatic portosystemic shunts (SIPSS) are far less frequently observed than extrahepatic portosystemic shunts, which include spleno-gastric-renal shunts, mesenteric-caval shunts, and a large patent umbilical vein. Reported here

is a case of decompensated liver cirrhosis with a large SIPSS without any incidence of overt HE.

2. Case Report

On October 10, a 58-year-old male was admitted to this Department for intermittent pain in the left upper abdomen that had persisted for about 10 years. The man was diagnosed with hepatitis B virus (HBV) infection-related liver cirrhosis 10 years prior. The man also had a 20-year history of alcohol abuse (100 g daily) but had abstained from alcohol consumption for 10 years. The man denied any previous history of trauma.

On physical examination, there was mild tenderness in the left upper abdomen with no rebound, shifting dullness, and edema in both lower extremities. Laboratory results revealed a white blood cell count of $3.9 \times 10^9/L$ (reference range: $3.5-9.5 \times 10^9/L$), a red blood cell count of $4.30 \times 10^{12}/L$ (reference range: $4.3-5.8 \times 10^{12}/L$), a hemoglobin level of 136 g/L (reference range: 130-175 g/L), and a platelet count of $45 \times 10^9/L$ (reference range: $125-350 \times 10^9/L$). Blood was positive for HbsAg and HBcAb-IgG, HBV DNA was 9.2×10^5 copies/mL (reference range: $< 1.0 \times 10^3$ copies/mL), total bilirubin was 48.9 $\mu\text{mol}/L$ (reference range: 5.1-22.2 $\mu\text{mol}/L$), alanine aminotransferase was 66.04 U/L (reference range: 9-50 U/L), aspartate aminotransferase was 93.11 U/L (reference range: 15-40 U/L), albumin

*Address correspondence to:

Drs. Xiaozhong Guo and Xingshun Qi, Department of Gastroenterology, General Hospital of Shenyang Military Area, No. 83 Wenhua Road, Shenyang 110840, China.

E-mail: guo_xiao_zhong@126.com (XG), xingshunqi@126.com (XQ)

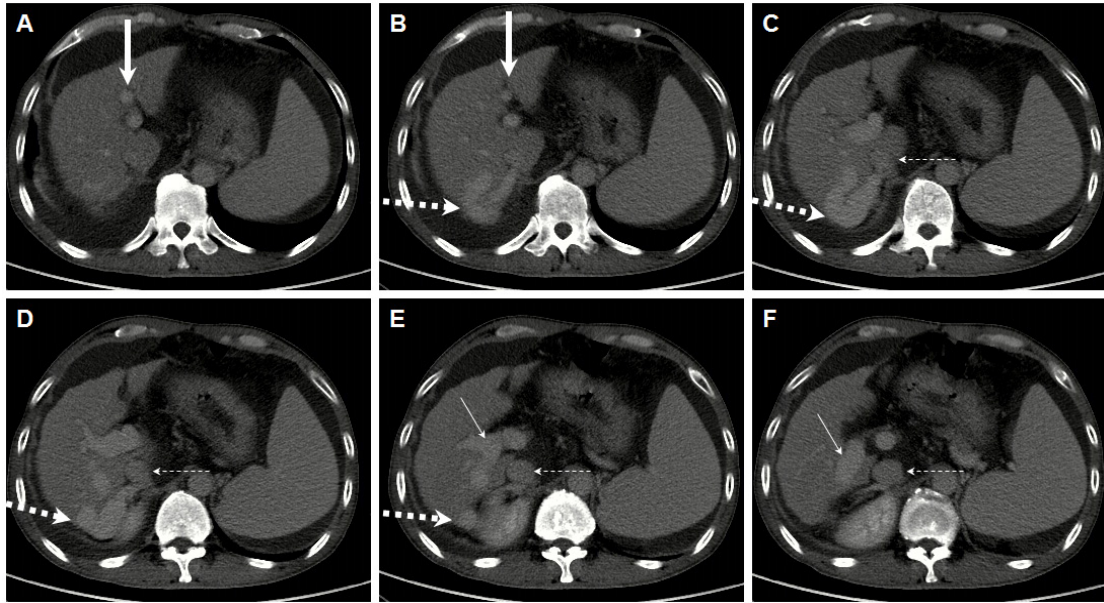


Figure 1. Abdominal axial contrast-enhanced computed tomography scans in the venous phase showing a spontaneous intrahepatic portosystemic shunt. Panels A-F are CT scans from top to bottom. The right portal branch (*fine solid arrow*) communicates with the inferior vena cava (*fine dashed arrow*) through a large portosystemic collateral vessel (*thick dashed arrow*). Notes: A thick solid arrow represents the left portal vein branch, a fine solid arrow represents the right portal vein branch, a thick dashed arrow represents the collateral vessel between the right portal vein branch and inferior vena cava, and a fine dashed arrow represents the inferior vena cava.

was 31.0 g/L (reference range: 40-55 g/L), prothrombin time was 19.3 seconds (reference range: 11.5-14.5 seconds), the international normalized ratio was 1.69, blood ammonia was 35 $\mu\text{mol/L}$ (reference range: 9-54 $\mu\text{mol/L}$), and alpha fetoprotein was 3.3 ng/mL (reference range: 0-6.7 ng/mL).

Contrast-enhanced computed tomography scans of the abdomen in the venous phase showed moderate ascites, splenomegaly, and right pleural effusion. Notably, there was a large collateral vessel between the right portal vein branch and the inferior vena cava (Figure 1). Thus, the patient was diagnosed with SIPSS, but no overt HE was observed. The presence of esophageal varices was confirmed by upper gastrointestinal endoscopy. Symptomatic treatment was given, including diuretics and hepatoprotective drugs. Abdominal pain gradually disappeared. On October 19, laboratory tests were performed again. Total bilirubin was 27.0 $\mu\text{mol/L}$, alanine aminotransferase was 44.97 U/L, aspartate aminotransferase was 68.02 U/L, albumin was 23.6 g/L, serum sodium was 137.2 mmol/L, and blood ammonia was 69 $\mu\text{mol/L}$. The patient was discharged and followed-up on an outpatient basis.

3. Discussion

Portal hypertension may be a major predisposing factor for SIPSS. Theoretically, the shunting of blood from the portal vein to the inferior vena cava may help to decrease portal pressure (2). In an experimental study, Geraghty *et al.* found that portal pressure and extent of portosystemic shunting were correlated a day after the

portal vein was partially ligated (4), but the correlation was absent in cirrhotic portal hypertension. However, SIPSS reduces the liver's ability to detoxify blood, thereby increasing the entry of toxic substances into the brain (2). In an early experimental study, Vogels *et al.* found that only rats with a portacaval shunt, rather than rats with a sham portacaval shunt, developed encephalopathy after hyperammonemia was induced with infusion of ammonium acetate (5). In contrast, Hsin *et al.* suggested that significant liver damage, rather than portosystemic shunts, would be required to induce the development of HE in cirrhotic rats (6). Despite the controversial findings from experimental studies, the clinical evidence appears to be unequivocal. A case-control study indicated that the prevalence of a large portosystemic shunt was significantly higher in cirrhotic patients with recurrent or persistent HE than in those without previous or present signs of overt HE (1). Notably, patients and the control group in that study were well matched in terms of age and the severity of liver dysfunction.

To the extent known, few studies have reported the presence of SIPSS in cirrhotic patients. More importantly, the patient in the current case was asymptomatic and did not receive embolization. Similarly, Tsauo *et al.* reported the presence of SIPSS in a patient with autoimmune hepatitis-related liver cirrhosis (7). Ding *et al.* also reported the presence of SIPSS in a patient with Budd-Chiari syndrome (8). In the two previous cases, no SIPSS-induced HE was observed. Thus, surgical or interventional vascular treatment of SIPSS was unnecessary.

Patients with symptomatic SIPSS should benefit from treatment. Recently, An *et al.* have shown that angiographic embolization of a spontaneous portosystemic shunt can improve the survival and liver function of cirrhotic patients with recurrent HE (9). Endovascular embolization of large spontaneous portosystemic shunts should be considered first (10-11). Several studies have recently described the Amplatzer device for embolization of large shunts. Kessler *et al.* used the Amplatzer Vascular Plug to embolize a large retroperitoneal shunt during a transjugular intrahepatic portosystemic shunt procedure (12). Ramirez-Polo *et al.* reported the use of the Amplatzer device to occlude an extrahepatic portosystemic shunt (*i.e.*, a porto-femoral "umbilical" shunt) in a patient with persistent HE (13). Wu *et al.* also reported the use of the Amplatzer device for embolization of a spontaneous splenorenal shunt in a cirrhotic patient presenting with HE after placement of a transjugular intrahepatic portosystemic shunt (14). Since an endovascular procedure is technically difficult, laparoscopic closure of SIPSS could be a treatment alternative (15).

Based on this unique case report, hepatologists should be mindful of the possibility of SIPSS in patients with liver cirrhosis. The decision to embolize SIPSS may depend primarily upon the presence of HE.

References

1. Riggio O, Efrati C, Catalano C, Pediconi F, Mecarelli O, Accornero N, Nicolao F, Angeloni S, Masini A, Ridola L, Attili AF, Merli M. High prevalence of spontaneous portal-systemic shunts in persistent hepatic encephalopathy: A case-control study. *Hepatology*. 2005; 42:1158-1165.
2. Chan CC. Portal-systemic collaterals and hepatic encephalopathy. *J Chin Med Assoc*. 2012; 75:1-2.
3. Tarantino G, Citro V, Conca P, Riccio A, Tarantino M, Capone D, Cirillo M, Lobello R, Iaccarino V. What are the implications of the spontaneous spleno-renal shunts in liver cirrhosis? *BMC Gastroenterol*. 2009; 9:89.
4. Geraghty JG, Angerson WJ, Carter DC. Portal venous pressure and portosystemic shunting in experimental portal hypertension. *Am J Physiol*. 1989; 257:G52-57.
5. Vogels BA, van Steynen B, Maas MA, Jorning GG, Chamuleau RA. The effects of ammonia and portal-systemic shunting on brain metabolism, neurotransmission and intracranial hypertension in hyperammonaemia-induced encephalopathy. *J Hepatol*. 1997; 26:387-395.
6. Hsin IF, Wang SS, Huang HC, Lee FY, Chan CY, Chang CC, Hsu CY, Lin HC, Lee SD. Portosystemic collaterals are not prerequisites for the development of hepatic encephalopathy in cirrhotic rats. *J Chin Med Assoc*. 2012; 75:3-9.
7. Tsauo J, Liu L, Tang C, Li X. Education and Imaging. Hepatobiliary and pancreatic: Spontaneous intrahepatic portosystemic shunt associated with cirrhosis. *J Gastroenterol Hepatol*. 2013; 28:904.
8. Ding PX, Li Z, Han XW, Zhang WG, Zhou PL, Wang ZG. Spontaneous intrahepatic portosystemic shunt in Budd-Chiari syndrome. *Ann Vasc Surg*. 2014; 28:742 e1-4.
9. An J, Kim KW, Han S, Lee J, Lim YS. Improvement in survival associated with embolisation of spontaneous portosystemic shunt in patients with recurrent hepatic encephalopathy. *Aliment Pharmacol Ther*. 2014; 39:1418-1426.
10. Laleman W, Simon-Talero M, Maleux G, *et al.* Embolization of large spontaneous portosystemic shunts for refractory hepatic encephalopathy: A multicenter survey on safety and efficacy. *Hepatology*. 2013; 57:2448-57.
11. Gopalakrishna R, Hurkadli PS, Puthukudy NK, Nair HR. Embolization of portosystemic shunt for treatment of recurrent hepatic encephalopathy. *J Clin Exp Hepatol*. 2014; 4:60-62.
12. Kessler J, Trerotola SO. Use of the Amplatzer Vascular Plug for embolization of a large retroperitoneal shunt during transjugular intrahepatic portosystemic shunt creation for gastric variceal bleeding. *J Vasc Interv Radiol*. 2006; 17:135-140.
13. Ramirez-Polo A, Márquez-Guillén E, González-Aguirre AJ, Casanova-Sánchez IE, Chávez-Ruiz R, Carrillo-Maravilla E, López-Méndez E. Persistent hepatic encephalopathy secondary to portosystemic shunt occluded with Amplatzer device. *Ann Hepatol*. 2014; 13:456-460.
14. Wu W, He C, Han G. Embolization of spontaneous splenorenal shunt for after-TIPS hepatic encephalopathy in a patient with cirrhosis and variceal bleeding. *Hepatology*. 2015; 61:1761-1762.
15. Kwon JN, Jeon YS, Cho SG, Lee KY, Hong KC. Spontaneous intrahepatic portosystemic shunt managed by laparoscopic hepatic vein closure. *J Minim Access Surg*. 2014; 10:207-209.

(Received January 6, 2016; Revised January 25, 2016; Accepted January 29, 2016)

Guide for Authors

1. Scope of Articles

Intractable & Rare Diseases Research is an international peer-reviewed journal. Intractable & Rare Diseases Research devotes to publishing the latest and most significant research in intractable and rare diseases. Articles cover all aspects of intractable and rare diseases research such as molecular biology, genetics, clinical diagnosis, prevention and treatment, epidemiology, health economics, health management, medical care system, and social science in order to encourage cooperation and exchange among scientists and clinical researchers.

2. Submission Types

Original Articles should be well-documented, novel, and significant to the field as a whole. An Original Article should be arranged into the following sections: Title page, Abstract, Introduction, Materials and Methods, Results, Discussion, Acknowledgments, and References. Original articles should not exceed 5,000 words in length (excluding references) and should be limited to a maximum of 50 references. Articles may contain a maximum of 10 figures and/or tables.

Brief Reports definitively documenting either experimental results or informative clinical observations will be considered for publication in this category. Brief Reports are not intended for publication of incomplete or preliminary findings. Brief Reports should not exceed 3,000 words in length (excluding references) and should be limited to a maximum of 4 figures and/or tables and 30 references. A Brief Report contains the same sections as an Original Article, but the Results and Discussion sections should be combined.

Reviews should present a full and up-to-date account of recent developments within an area of research. Normally, reviews should not exceed 8,000 words in length (excluding references) and should be limited to a maximum of 100 references. Mini reviews are also accepted.

Policy Forum articles discuss research and policy issues in areas related to life science such as public health, the medical care system, and social science and may address governmental issues at district, national, and international levels of discourse. Policy Forum articles should not exceed 2,000 words in length (excluding references).

Case Reports should be detailed reports of the symptoms, signs, diagnosis, treatment, and follow-up of an individual patient. Case reports may contain a demographic profile of the patient but usually describe an unusual

or novel occurrence. Unreported or unusual side effects or adverse interactions involving medications will also be considered. Case Reports should not exceed 3,000 words in length (excluding references).

News articles should report the latest events in health sciences and medical research from around the world. News should not exceed 500 words in length.

Letters should present considered opinions in response to articles published in Intractable & Rare Diseases Research in the last 6 months or issues of general interest. Letters should not exceed 800 words in length and may contain a maximum of 10 references.

3. Editorial Policies

Ethics: Intractable & Rare Diseases Research requires that authors of reports of investigations in humans or animals indicate that those studies were formally approved by a relevant ethics committee or review board.

Conflict of Interest: All authors are required to disclose any actual or potential conflict of interest including financial interests or relationships with other people or organizations that might raise questions of bias in the work reported. If no conflict of interest exists for each author, please state "There is no conflict of interest to disclose".

Submission Declaration: When a manuscript is considered for submission to Intractable & Rare Diseases Research, the authors should confirm that 1) no part of this manuscript is currently under consideration for publication elsewhere; 2) this manuscript does not contain the same information in whole or in part as manuscripts that have been published, accepted, or are under review elsewhere, except in the form of an abstract, a letter to the editor, or part of a published lecture or academic thesis; 3) authorization for publication has been obtained from the authors' employer or institution; and 4) all contributing authors have agreed to submit this manuscript.

Cover Letter: The manuscript must be accompanied by a cover letter signed by the corresponding author on behalf of all authors. The letter should indicate the basic findings of the work and their significance. The letter should also include a statement affirming that all authors concur with the submission and that the material submitted for publication has not been published previously or is not under consideration for publication elsewhere. The cover letter should be submitted in PDF format. For example of Cover Letter, please visit <http://www.irdrjournal.com/downcentre.php> (Download Centre).

Copyright: A signed JOURNAL PUBLISHING AGREEMENT (JPA) form must be provided by post, fax, or as a scanned file before acceptance of the article. Only forms with a hand-written signature are accepted. This copyright will ensure the widest possible dissemination of information.

A form facilitating transfer of copyright can be downloaded by clicking the appropriate link and can be returned to the e-mail address or fax number noted on the form (Please visit [Download Centre](#)). Please note that your manuscript will not proceed to the next step in publication until the JPA Form is received. In addition, if excerpts from other copyrighted works are included, the author(s) must obtain written permission from the copyright owners and credit the source(s) in the article.

Suggested Reviewers: A list of up to 3 reviewers who are qualified to assess the scientific merit of the study is welcomed. Reviewer information including names, affiliations, addresses, and e-mail should be provided at the same time the manuscript is submitted online. Please do not suggest reviewers with known conflicts of interest, including participants or anyone with a stake in the proposed research; anyone from the same institution; former students, advisors, or research collaborators (within the last three years); or close personal contacts. Please note that the Editor-in-Chief may accept one or more of the proposed reviewers or may request a review by other qualified persons.

Language Editing: Manuscripts prepared by authors whose native language is not English should have their work proofread by a native English speaker before submission. If not, this might delay the publication of your manuscript in Intractable & Rare Diseases Research.

The Editing Support Organization can provide English proofreading, Japanese-English translation, and Chinese-English translation services to authors who want to publish in Intractable & Rare Diseases Research and need assistance before submitting a manuscript. Authors can visit this organization directly at <http://www.iacmhr.com/iac-eso/support.php?lang=en>. IAC-ESO was established to facilitate manuscript preparation by researchers whose native language is not English and to help edit works intended for international academic journals.

4. Manuscript Preparation

Manuscripts should be written in clear, grammatically correct English and submitted as a Microsoft Word file in a single-column format. Manuscripts must be paginated and typed in 12-point Times New Roman font with 24-point line spacing. Please do not embed figures in the text. Abbreviations should be used as little as possible and should be explained at first mention unless the term is a well-known abbreviation (e.g. DNA). Single words should not be abbreviated.

Title page: The title page must include 1) the title of the paper (Please note the title should be short, informative, and contain the major key words); 2) full name(s) and affiliation(s) of the author(s), 3) abbreviated names of the author(s), 4) full name, mailing address, telephone/fax numbers, and e-mail address of the corresponding author; and 5) conflicts of interest (if you have an actual or potential conflict of interest to disclose, it must be included as a footnote on the title page of the

manuscript; if no conflict of interest exists for each author, please state "There is no conflict of interest to disclose"). Please visit [Download Centre](#) and refer to the title page of the manuscript sample.

Abstract: The abstract should briefly state the purpose of the study, methods, main findings, and conclusions. For article types including Original Article, Brief Report, Review, Policy Forum, and Case Report, a one-paragraph abstract consisting of no more than 250 words must be included in the manuscript. For News and Letters, a brief summary of main content in 150 words or fewer should be included in the manuscript. Abbreviations must be kept to a minimum and non-standard abbreviations explained in brackets at first mention. References should be avoided in the abstract. Key words or phrases that do not occur in the title should be included in the Abstract page.

Introduction: The introduction should be a concise statement of the basis for the study and its scientific context.

Materials and Methods: The description should be brief but with sufficient detail to enable others to reproduce the experiments. Procedures that have been published previously should not be described in detail but appropriate references should simply be cited. Only new and significant modifications of previously published procedures require complete description. Names of products and manufacturers with their locations (city and state/country) should be given and sources of animals and cell lines should always be indicated. All clinical investigations must have been conducted in accordance with Declaration of Helsinki principles. All human and animal studies must have been approved by the appropriate institutional review board(s) and a specific declaration of approval must be made within this section.

Results: The description of the experimental results should be succinct but in sufficient detail to allow the experiments to be analyzed and interpreted by an independent reader. If necessary, subheadings may be used for an orderly presentation. All figures and tables must be referred to in the text.

Discussion: The data should be interpreted concisely without repeating material already presented in the Results section. Speculation is permissible, but it must be well-founded, and discussion of the wider implications of the findings is encouraged. Conclusions derived from the study should be included in this section.

Acknowledgments: All funding sources should be credited in the Acknowledgments section. In addition, people who contributed to the work but who do not meet the criteria for authors should be listed along with their contributions.

References: References should be numbered in the order in which they appear in the text. Citing of unpublished results, personal

communications, conference abstracts, and theses in the reference list is not recommended but these sources may be mentioned in the text. In the reference list, cite the names of all authors when there are fifteen or fewer authors; if there are sixteen or more authors, list the first three followed by *et al.* Names of journals should be abbreviated in the style used in PubMed. Authors are responsible for the accuracy of the references. Examples are given below:

Example 1 (Sample journal reference):
Inagaki Y, Tang W, Zhang L, Du GH, Xu WF, Kokudo N. Novel aminopeptidase N (APN/CD13) inhibitor 24F can suppress invasion of hepatocellular carcinoma cells as well as angiogenesis. *Biosci Trends*. 2010; 4:56-60.

Example 2 (Sample journal reference with more than 15 authors):
Darby S, Hill D, Auvinen A, *et al.* Radon in homes and risk of lung cancer: Collaborative analysis of individual data from 13 European case-control studies. *BMJ*. 2005; 330:223.

Example 3 (Sample book reference):
Shalev AY. Post-traumatic stress disorder: Diagnosis, history and life course. In: *Post-traumatic Stress Disorder, Diagnosis, Management and Treatment* (Nutt DJ, Davidson JR, Zohar J, eds.). Martin Dunitz, London, UK, 2000; pp. 1-15.

Example 4 (Sample web page reference):
World Health Organization. The World Health Report 2008 – primary health care: Now more than ever. http://www.who.int/whr/2008/whr08_en.pdf (accessed September 23, 2010).

Tables: All tables should be prepared in Microsoft Word or Excel and should be arranged at the end of the manuscript after the References section. Please note that tables should not in image format. All tables should have a concise title and should be numbered consecutively with Arabic numerals. If necessary, additional information should be given below the table.

Figure Legend: The figure legend should be typed on a separate page of the main manuscript and should include a short title and explanation. The legend should be concise but comprehensive and should be understood without referring to the text. Symbols used in figures must be explained.

Figure Preparation: All figures should be clear and cited in numerical order in the text. Figures must fit a one- or two-column format on the journal page: 8.3 cm (3.3 in.) wide for a single column, 17.3 cm (6.8 in.) wide for a double column; maximum height: 24.0 cm (9.5 in.). Please make sure that artwork files are in an acceptable format (TIFF or JPEG) at minimum resolution (600 dpi for illustrations, graphs, and annotated artwork, and 300 dpi for micrographs and photographs). Please provide all figures as separate files. Please note that low-resolution images are one of the leading causes of article resubmission and schedule delays. All color figures will be reproduced in full color in the online edition of the journal at no cost to authors.

Units and Symbols: Units and symbols conforming to the International System of Units (SI) should be used for physicochemical quantities. Solidus notation (*e.g.* mg/kg, mg/mL, mol/mm²/min) should be used. Please refer to the SI Guide www.bipm.org/en/si/ for standard units.

Supplemental data: Supplemental data might be useful for supporting and enhancing your scientific research and Intractable & Rare Diseases Research accepts the submission of these materials which will be only published online alongside the electronic version of your article. Supplemental files (figures, tables, and other text materials) should be prepared according to the above guidelines, numbered in Arabic numerals (*e.g.*, Figure S1, Figure S2, and Table S1, Table S2) and referred to in the text. All figures and tables should have titles and legends. All figure legends, tables and supplemental text materials should be placed at the end of the paper. Please note all of these supplemental data should be provided at the time of initial submission and note that the editors reserve the right to limit the size and length of Supplemental Data.

5. Submission Checklist

The Submission Checklist will be useful during the final checking of a manuscript prior to sending it to Intractable & Rare Diseases Research for review. Please visit [Download Centre](#) and download the Submission Checklist file.

6. Online submission

Manuscripts should be submitted to Intractable & Rare Diseases Research online at <http://www.irdjournal.com>. The manuscript file should be smaller than 5 MB in size. If for any reason you are unable to submit a file online, please contact the Editorial Office by e-mail at office@irdjournal.com

7. Accepted manuscripts

Proofs: Galley proofs in PDF format will be sent to the corresponding author *via* e-mail. Corrections must be returned to the editor (office@irdjournal.com) within 3 working days.

Offprints: Authors will be provided with electronic offprints of their article. Paper offprints can be ordered at prices quoted on the order form that accompanies the proofs.

Page Charge: No page charges will be levied to author for the publication of their article except for reprints.

(As of February 2013)

Editorial and Head Office:

Pearl City Koishikawa 603
2-4-5 Kasuga, Bunkyo-ku
Tokyo 112-0003, Japan
Tel: +81-3-5840-9968
Fax: +81-3-5840-9969
E-mail: office@irdjournal.com

JOURNAL PUBLISHING AGREEMENT (JPA)

Manuscript No.:

Title:

Corresponding Author:

The International Advancement Center for Medicine & Health Research Co., Ltd. (IACMHR Co., Ltd.) is pleased to accept the above article for publication in Intractable & Rare Diseases Research. The International Research and Cooperation Association for Bio & Socio-Sciences Advancement (IRCA-BSSA) reserves all rights to the published article. Your written acceptance of this JOURNAL PUBLISHING AGREEMENT is required before the article can be published. Please read this form carefully and sign it if you agree to its terms. The signed JOURNAL PUBLISHING AGREEMENT should be sent to the Intractable & Rare Diseases Research office (Pearl City Koishikawa 603, 2-4-5 Kasuga, Bunkyo-ku, Tokyo 112-0003, Japan; E-mail: office@irdrjournal.com; Tel: +81-3-5840-9968; Fax: +81-3-5840-9969).

1. Authorship Criteria

As the corresponding author, I certify on behalf of all of the authors that:

- 1) The article is an original work and does not involve fraud, fabrication, or plagiarism.
- 2) The article has not been published previously and is not currently under consideration for publication elsewhere. If accepted by Intractable & Rare Diseases Research, the article will not be submitted for publication to any other journal.
- 3) The article contains no libelous or other unlawful statements and does not contain any materials that infringes upon individual privacy or proprietary rights or any statutory copyright.
- 4) I have obtained written permission from copyright owners for any excerpts from copyrighted works that are included and have credited the sources in my article.
- 5) All authors have made significant contributions to the study including the conception and design of this work, the analysis of the data, and the writing of the manuscript.
- 6) All authors have reviewed this manuscript and take responsibility for its content and approve its publication.
- 7) I have informed all of the authors of the terms of this publishing agreement and I am signing on their behalf as their agent.

2. Copyright Transfer Agreement

I hereby assign and transfer to IACMHR Co., Ltd. all exclusive rights of copyright ownership to the above work in the journal Intractable & Rare Diseases Research, including but not limited to the right 1) to publish, republish, derivate, distribute, transmit, sell, and otherwise use the work and other related material worldwide, in whole or in part, in all languages, in electronic, printed, or any other forms of media now known or hereafter developed and the right 2) to authorize or license third parties to do any of the above.

I understand that these exclusive rights will become the property of IACMHR Co., Ltd., from the date the article is accepted for publication in the journal Intractable & Rare Diseases Research. I also understand that IACMHR Co., Ltd. as a copyright owner has sole authority to license and permit reproductions of the article.

I understand that except for copyright, other proprietary rights related to the Work (e.g. patent or other rights to any process or procedure) shall be retained by the authors. To reproduce any text, figures, tables, or illustrations from this Work in future works of their own, the authors must obtain written permission from IACMHR Co., Ltd.; such permission cannot be unreasonably withheld by IACMHR Co., Ltd.

3. Conflict of Interest Disclosure

I confirm that all funding sources supporting the work and all institutions or people who contributed to the work but who do not meet the criteria for authors are acknowledged. I also confirm that all commercial affiliations, stock ownership, equity interests, or patent-licensing arrangements that could be considered to pose a financial conflict of interest in connection with the article have been disclosed.

Corresponding Author's Name (Signature):

Date:

