

ISSN 2186-3644 Online ISSN 2186-361X

IRDR

Intractable & Rare Diseases Research

Volume 7, Number 3
August, 2018



www.irdrjournal.com

IRDR

Intractable & Rare Diseases Research



ISSN: 2186-3644
Online ISSN: 2186-361X
CODEN: IRDRA3
Issues/Year: 4
Language: English
Publisher: IACMHR Co., Ltd.

Intractable & Rare Diseases Research is one of a series of peer-reviewed journals of the International Research and Cooperation Association for Bio & Socio-Sciences Advancement (IRCA-BSSA) Group and is published quarterly by the International Advancement Center for Medicine & Health Research Co., Ltd. (IACMHR Co., Ltd.) and supported by the IRCA-BSSA, Shandong Academy of Medical Sciences, and Shandong Rare Disease Association.


Intractable & Rare Diseases Research devotes to publishing the latest and most significant research in intractable and rare diseases. Articles cover all aspects of intractable and rare diseases research such as molecular biology, genetics, clinical diagnosis, prevention and treatment, epidemiology, health economics, health management, medical care system, and social science in order to encourage cooperation and exchange among scientists and clinical researchers.

Intractable & Rare Diseases Research publishes Original Articles, Brief Reports, Reviews, Policy Forum articles, Case Reports, News, and Letters on all aspects of the field of intractable and rare diseases research. All contributions should seek to promote international collaboration.


IRCA-BSSA Group Journals



ISSN: 1881-7815
Online ISSN: 1881-7823
CODEN: BTIRCZ
Issues/Year: 6
Language: English
Publisher: IACMHR Co., Ltd.
www.biosciencetrends.com



ISSN: 1881-7831
Online ISSN: 1881-784X
CODEN: DDTRBX
Issues/Year: 6
Language: English
Publisher: IACMHR Co., Ltd.
www.ddtjournal.com



ISSN: 2186-3644
Online ISSN: 2186-361X
CODEN: IRDRA3
Issues/Year: 4
Language: English
Publisher: IACMHR Co., Ltd.
www.irdrjournal.com

Intractable & Rare Diseases Research

Editorial and Head Office

Pearl City Koishikawa 603, 2-4-5 Kasuga, Bunkyo-ku,
Tokyo 112-0003, Japan

Tel: +81-3-5840-9968, Fax: +81-3-5840-9969

E-mail: office@irdrjournal.com

URL: www.irdrjournal.com

Editorial Board

Editor-in-Chief:

Masatoshi MAKUUCHI
Japanese Red Cross Medical Center, Tokyo, Japan

Chief Director & Executive Editor:

Wei TANG
The University of Tokyo, Tokyo, Japan

Co-Editors-in-Chief:

Jinxiang HAN
Shandong Academy of Medical Sciences, Jinan, China

Jose-Alain SAHEL
Pierre and Marie Curie University, Paris, France

Editorial Board Members

Tetsuya ASAKAWA <i>(Hamamatsu, Japan)</i>	Si JIN <i>(Wuhan, China)</i>	Shinichi SATO <i>(Tokyo, Japan)</i>	Yuesi ZHONG <i>(Guangzhou, China)</i>
Karen BRØNDUM-NIELSEN <i>(Glostrup, Denmark)</i>	Yasuhiro KANATANI <i>(Saitama, Japan)</i>	Yasuyuki SETO <i>(Tokyo, Japan)</i>	Jiayi ZHOU <i>(Boston, MA, USA)</i>
Yazhou CUI <i>(Jinan, China)</i>	Mureo KASAHARA <i>(Tokyo, Japan)</i>	Jian SUN <i>(Guangzhou, China)</i>	Wenxia ZHOU <i>(Beijing, China)</i>
John DART <i>(Crowthorne, UK)</i>	Jun-ichi KIRA <i>(Fukuoka, Japan)</i>	Qingfang SUN <i>(Shanghai, China)</i>	Web Editor:
Masahito EBINA <i>(Sendai, Japan)</i>	Toshiro KONISHI <i>(Tokyo, Japan)</i>	ZhiPeng SUN <i>(Beijing, China)</i>	Yu CHEN <i>(Tokyo, Japan)</i>
Clodoveo FERRI <i>(Modena, Italy)</i>	Masato KUSUNOKI <i>(Mie, Japan)</i>	Samia TEMTAMY <i>(Cairo, Egypt)</i>	Proofreaders:
Toshiyuki FUKAO <i>(Gifu, Japan)</i>	Shixiu LIAO <i>(Zhengzhou, China)</i>	Yisha TONG <i>(Heidelberg, Australia)</i>	Curtis BENTLEY <i>(Roswell, GA, USA)</i>
Ruoyan GAI <i>(Jinan, China)</i>	Zhibin LIN <i>(Beijing, China)</i>	Hisanori UMEHARA <i>(Ishikawa, Japan)</i>	Thomas R. LEBON <i>(Los Angeles, CA, USA)</i>
Shiwei GONG <i>(Wuhan, China)</i>	Reymundo LOZANO <i>(New York, NY, USA)</i>	Chenglin WANG <i>(Shenzhen, China)</i>	Office Staff:
Jeff GUO <i>(Cincinnati, OH, USA)</i>	Kuansheng MA <i>(Chongqing, China)</i>	Haibo WANG <i>(Hong Kong, China)</i>	Apolline SONG <i>(Tokyo, Japan)</i>
Toshiro HARA <i>(Fukuoka, Japan)</i>	Katia MARAZOVA <i>(Paris, France)</i>	Huijun WANG <i>(Shanghai, China)</i>	Editorial and Head Office:
Lihui HUANG <i>(Beijing, China)</i>	Chikao MORIMOTO <i>(Tokyo, Japan)</i>	Qinghe XING <i>(Shanghai, China)</i>	Pearl City Koishikawa 603
Reiko HORIKAWA <i>(Tokyo, Japan)</i>	Noboru MOTOMURA <i>(Tokyo, Japan)</i>	Zhenggang XIONG <i>(New Orleans, LA, USA)</i>	2-4-5 Kasuga, Bunkyo-ku
Takahiko HORIUCHI <i>(Fukuoka, Japan)</i>	Masanori NAKAGAWA <i>(Kyoto, Japan)</i>	Toshiyuki YAMAMOTO <i>(Tokyo, Japan)</i>	Tokyo 112-0003, Japan
Yoshinori INAGAKI <i>(Tokyo, Japan)</i>	Jun NAKAJIMA <i>(Tokyo, Japan)</i>	Huijun YUAN <i>(Beijing, China)</i>	Tel: +81-3-5840-9968
Masaru IWASAKI <i>(Yamanashi, Japan)</i>	Takashi NAKAJIMA <i>(Kashiwazaki, Japan)</i>	Wenhong ZHANG <i>(Shanghai, China)</i>	Fax: +81-3-5840-9969
Baoan JI <i>(Houston, TX, USA)</i>	Ming QIU <i>(Shanghai, China)</i>	Xianqin ZHANG <i>(Wuhan, China)</i>	E-mail: office@irdrjournal.com
Xunming JI <i>(Beijing, China)</i>	Phillips ROBBINS <i>(Boston, MA, USA)</i>	Yanjun ZHANG <i>(Cincinnati, OH, USA)</i>	<i>(As of February 2018)</i>
Guosheng JIANG <i>(Jinan, China)</i>	Hironobu SASANO <i>(Sendai, Japan)</i>	Yumin ZHANG <i>(Bethesda, MD, USA)</i>	

Review

- 148 - 155 **The impact of the intestinal microbiome on bone health.**
Jian Zhang, Yanqin Lu, Yanzhou Wang, Xiuzhi Ren, Jinxiang Han
- 156 - 163 **National information system for rare diseases with an approach to data architecture: A systematic review.**
Simin Derayeh, Alireza Kazemi, Reza Rabiei, Azamossadat Hosseini, Hamid Moghaddasi

Original Article

- 164 - 171 **Assessment of the impact of an exercise program on the physical and functional capacity in patients with autosomal recessive spastic ataxia of Charlevoix-Saguenay: An exploratory study.**
Olivier Audet, Hung Tien Bui, Maxime Allisse, Alain-Steve Comtois, Mario Leone

Brief Report

- 172 - 176 **Multidrug resistant Elizabethkingia meningoseptica bacteremia – Experience from a level 1 trauma centre in India.**
Aishwarya Govindaswamy, Vijeta Bajpai, Vivek Trikha, Samarth Mittal, Rajesh Malhotra, Purva Mathur
- 177- 181 **Underlying etiology determines the outcome in atraumatic chyloous ascites.**
Harshal S Mandavdhare, Vishal Sharma, Harjeet Singh, Usha Dutta

Case Report

- 182- 184 **Is it always cancer? A curious case of benign intracranial hypertension in chronic myeloid leukemia.**
Purva V. Sharma, Omar Ilyas, Yash Jobanputra, Teresita Casanova, Venkat Kalidindi, Napoleon Santos
- 185- 190 **Traumatic neuroma as a rare cause of intractable neuropathic breast pain following cancer surgery: Management and review of the literature.**
Nikolaos S. Salemis
- 191- 195 **Co-occurrence of Gomez-Lopez-Hernandez syndrome and Autism Spectrum Disorder: Case report with review of literature.**
Bakur Kotetishvili, Malkhaz Makashvili, Michael Okujava, Alexandre Kotetishvili, Tamar Kopadze

- 196- 199** **Esophageal arteriovenous malformation, a rare cause of significant upper gastrointestinal bleeding: Case report and review of literature.**
Pradeep Reddy Kathi, Maher Tama, Shankerdas Kundumadam, Dhiraj Gulati, Murray N Ehrinpreis
- 200 - 203** **Recurrent chylous effusions and venous thrombosis: Uncommon presentation of a common condition.**
Manasvini Bhatt, Netto George, Manish Soneja, Prabhat Kumar, Surabhi Vyas, Ashutosh Biswas
- 204 - 208** **Successful treatment of acute-on-chronic liver failure and hemolytic anemia with hepato-protective drugs in combination with intravenous ozone without steroids: A case report.**
Zhaohui Bai, Hongyu Li, Xiaozhong Guo, Yanqin Liu, Jiao Deng, Chunhui Wang, Yingying Li, Xingshun Qi
- 209 - 212** **A catastrophic nightmare of the interventional cardiologist: Iatrogenic left main artery dissection and longitudinal stent deformation.**
Oguz Yildirim, Murat Gul, Sinan Inci, Halil Aktaş, Pınar Dogan, Abdulkadir Bozkır, İbrahim İzgü , Recep Karataş

Guide for Authors

Copyright

The impact of the intestinal microbiome on bone health

Jian Zhang^{1,2,§}, Yanqin Lu^{1,2,§,*}, Yanzhou Wang³, Xiuzhi Ren⁴, Jinxiang Han^{1,2,*}

¹Key Laboratory for Biotech-Drugs Ministry of Health, Key Laboratory for Rare & Uncommon Diseases of Shandong Province, Shandong Medicinal Biotechnology Centre, Shandong Academy of Medical Sciences, Ji'nan, China;

²School of Medicine and Life Sciences, University of Ji'nan-Shandong Academy of Medical Sciences, Ji'nan, China;

³Department of Paediatric Surgery, Shandong Provincial Hospital, Ji'nan, China;

⁴Department of Orthopaedic Surgery, The People's Hospital of Wuqing District, Tianjin, China.

Summary

Intestinal microbial flora, known as the second gene pool of the human body, play an important role in immune function, nutrient uptake, and various activities of host cells, as well as in human disease. Intestinal microorganisms are involved in a variety of mechanisms that affect bone health. Gut microbes are closely related to genetic variation, and gene regulation plays an important part in the development of bone-related diseases such as osteoporosis. Intestinal microorganisms can disrupt the balance between bone formation and resorption by indirectly stimulating or inhibiting osteoblasts and osteoclasts. In addition, intestinal microorganisms affect bone metabolism by regulating growth factors or altering bone immune status and can also alter the metabolism of serotonin, cortisol, and sex hormones, thereby affecting bone mass in mice. Moreover, probiotics, antibiotics, and diet can change the composition of the intestinal microbial flora, thus affecting bone health and also potentially helping to treat bone disease. Studying the relationship between intestinal flora and osteoblasts, osteoclasts, and bone marrow mesenchymal stem cells may provide a basis for preventing and treating bone diseases. This paper reviews recent advances in the study of the relationship between intestinal microflora and bone disease.

Keywords: Intestinal microbial flora, hereditary bone disease, bone health, bone-related cells

1. Introduction

Microbial groups, which are symbiotic in the human body or on the surface of the human body and cause various diseases under certain conditions, are collectively known as the human microbiome. This concept was first proposed by Lederberg *et al.* (1). There are many types of bacteria that populate the intestines of humans and animals. For example, the number of microorganisms in the body and the proportion of cells can reach a ratio of 10:1, and there are more than 10 trillion bacteria (2) that encode 100-fold more genes than those in the human genome (2). Thus, the intestinal microbial flora are known as the "second gene pool" of the human body (2).

Like human organs, human intestinal microflora have significant effects on immune function, nutrient uptake, and various life activities of host cells (3) as well as on various diseases and conditions in the human body. The microbial flora of the gut affect an organism by changing the balance of bacteria and metabolites (4), which can lead to changes in metabolic processes and induce the development of various diseases such as ulcerative colitis in inflammatory bowel disease (5) and Crohn's disease (6). Microbial flora can also cause many other common diseases including obesity (7), diabetes (8), and other endocrine system diseases, as well as cardiovascular diseases (9). Intestinal flora also affect diseases such as immune system-induced rheumatoid arthritis (10) and systemic lupus erythematosus (10). A study on cancer found that *Bifidobacterium* can improve anti-tumor immunity in mice (11). Conversely, *Fusobacterium nucleatum* can promote colorectal cancer resistance chemotherapy in cancer treatment (12). In addition, changes in intestinal microbial flora can induce inflammatory reactions in the host and change neurotransmitter metabolism, resulting

Released online in J-STAGE as advance publication August 28, 2018.

[§]These authors contributed equally to this work.

*Address correspondence to:

Dr. Jinxiang Han and Dr. Yanqin Lu, Shandong Medicinal Biotechnology Centre, Shandong Academy of Medical Sciences, 18877 Jingshi Road, Ji'nan 250062, China.

E-mail: samshjx@sina.com (JH); yanqinlu@yahoo.com (YL)

in neurological dysfunction (13), depression, mental decline, and other problems (14,15). An imbalance in intestinal flora affects many diseases, whereas intestinal flora in homeostasis can prevent diseases. For example, intestinal microbial flora attach to the intestinal mucosa to form a protective barrier to defend against invasion by exotic pathogenic microorganisms (10). Intestinal flora can also stimulate an organism to produce an immune response to microbial antigens and to produce more lymphocytes (16). The resulting immunoglobulin G (IgG) antibodies can induce the organism to eliminate pathogenic microorganisms by identifying Gram-negative bacteria and neutralizing toxins and viruses (17), thereby promoting maturation of the immune system. This protects against inflammation and infection and improves immune function in the host (6,17). The current review provides updated information on the intestinal microbial flora and their affect on bone health.

2. Intestinal microbial flora and bone disease

2.1. Intestinal microbial flora and genetic factors

The relationship between human intestinal microbes and host genetic variation (18-22) is one in which the latter affects the composition of human intestinal microbes (19,20). A single-nucleotide polymorphism (SNP) (C/T-13910) of the European lactase (*LCT*) gene and SNPs (G/C-14010, T/G-13915, and C/G-13907) in the African *LCT* gene are associated with the abundance of *Bifidobacterium* in the gastrointestinal tract. These SNPs were found to significantly enhance transcription of the *LCT* gene promoter *in vitro* and to facilitate the hydrolysis of lactose in the gastrointestinal tract by lactase, thus directly affecting the persistence of *LCT* (23). *Bifidobacterium* in the gastrointestinal tract can also metabolize host lactose (24). *LCT* gene mutations may indirectly regulate the abundance of *Bifidobacterium* in the gastrointestinal tract by altering its lactose levels. Ruminococcaceae and Lachnospiraceae are the two main families of human intestinal microorganisms and are more similar in identical twins than in fraternal twins (25). The host genotype can regulate the abundance of many microbial flora.

Microbial diversity is controlled by both environmental and host genetic factors and is related to multiple diseases. Toll-like receptor (TLR) 5 gene-deficient mice have signs of metabolic syndrome including hyperlipidemia, hypertension, and obesity. After intestinal microflora were transferred from TLR5 gene-deficient mice to wild-type aseptic mice, the aseptic mice also exhibited the characteristics of metabolic syndrome, which were related to changes in microbial flora in the gut (26). Next-generation sequencing of genes in the gastrointestinal tract and

quantitative trait loci (QTL) mapping have revealed that some host genes can change gut immunological profiles and modulate the balance between gut microbial communities. For example, the interferon gene-rich QTL region located on chromatin 4 modulates *Firmicutes* and *Bacteroidetes*, which are dominant BXD strains among gut microbes. Interleukin-1 receptor-associated kinase (IRAK) 4 modulates Rikenellaceae while TGF- β 3 modulates Prevotellaceae (27).

Genetic variations in the genome may occur during the process of adapting to the environment, causes specific changes in microbial groups. Some loci can control a single microbial species, the associated taxa of certain microorganisms, and some of the associated microbial populations that are presumed to be more efficient and widely distributed (27). In addition, the gut flora have certain effects on host gene mutations. Some strains of *Escherichia coli* have a polyketide synthase (*PKS*) gene island that induces DNA mismatch repair in host intestinal epithelial cells by encoding gene toxins that cause tumors (28). Moreover, the superoxide anion produced by *Enterococcus* also causes host DNA damage and genomic instability, resulting in intestinal epithelial cell mutations that trigger colorectal cancer (29).

2.2. Intestinal microbial flora and osteoporosis

Osteoporosis is a metabolic bone disease that results in decreased bone mass and bone mineral density and that induces changes in bone microstructure (30). This disease is mainly influenced by heredity and environmental factors, and many studies have confirmed that there is a certain relationship between intestinal microbial flora and osteoporosis (30). An estrogen deficiency leads to bone loss-induced osteoporosis, and the use of surgical ovarian resection (OVX) or sexual hormone inhibition causes a lack of estrogen in mice (31). When OVX mice were treated with *Lactobacillus acidophilus*, the level of bone resorption markers decreased and osteoclast formation was inhibited (31). In addition, the number of T lymphocytes in OVX mice decreased and osteoclast formation was inhibited by *Lactobacillus reuteri* (32). Type I diabetes can also induce osteoporosis. A study reported that *L. reuteri* can inhibit the expression of tumor necrosis factor (TNF) and Wnt10b, preventing bone loss and bone marrow adiposity in a mouse model of type I diabetes (33).

Recent studies have found that intestinal microflora can regulate growth factor insulin-like growth factor (IGF)-1 levels, and thus regulate bone formation and absorption in young and middle-aged mice. The levels of IGF-1 decreased when antibiotics were used to destroy intestinal microflora in young mice (34). In addition, intestinal microbes were able to mediate the regulation of bone metabolism by altering bone

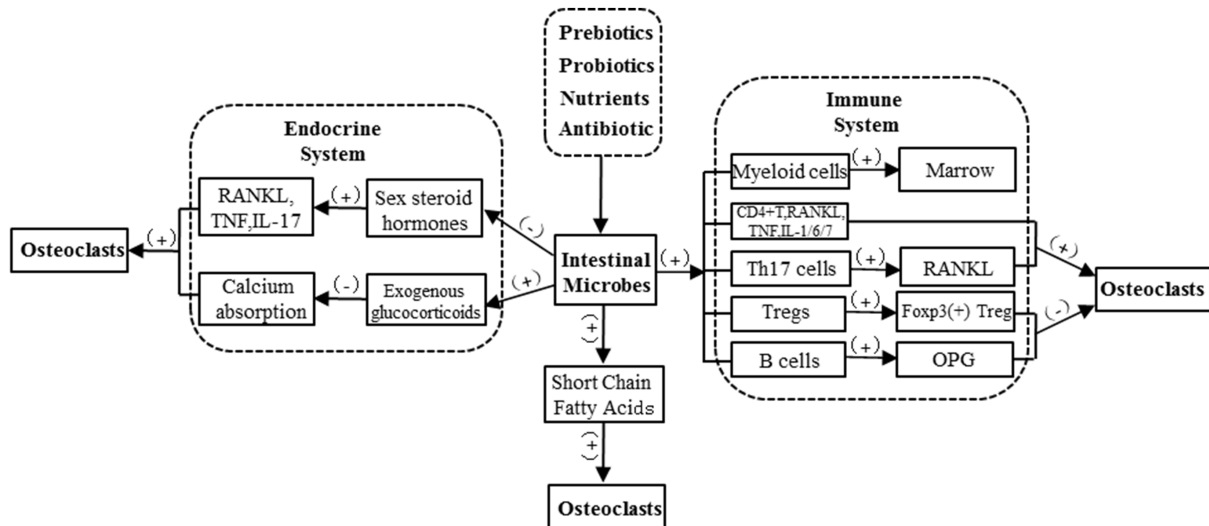


Figure 1. Mechanisms by which intestinal microbes affect bone health.

immune status (35). Sterile mice had a significant increase in bone mass and a significant decrease in the number of osteoclasts, the number of CD4⁺ T cells derived from the bone marrow, and the number of osteoclast precursor cells compared to normal mice. While the number of osteoclasts, CD4⁺ T cells, and osteoclast precursor cells returned to normal in 3-week-old sterile mice treated with intestinal microbial flora and the quality of bone trabecular and cortical bone decreased, the expression of inflammatory cytokines in bone decreased significantly (35).

Intestinal disorders can cause inflammatory bowel disease (36), which can increase the risk of osteoporosis and related brittle fractures (37). The reduction in bone associated with inflammatory bowel disease is mainly due to insufficient calcium absorption and a decrease in the cycling levels of vitamins D and K (38). In addition, the inflammatory reaction caused by the lack of sex steroids can promote bone resorption, resulting in the loss of trabecular bone. The probiotic *Lactobacillus rhamnosus GG* (LGG) can reduce inflammation in the intestine and bone, improve intestinal permeability, and prevent bone loss (39,40).

When an imbalance of intestinal flora homeostasis occurs during intestinal inflammation, the intestinal absorption of vitamin D can help to treat enteritis, thereby reducing intestinal permeability and avoiding the impact of that imbalance on bone health (41). Vitamin D has beneficial effects in bones (42). When calcium supply is sufficient, the absorption of vitamin D and its metabolites in the gut can maintain the homeostasis of intestinal flora, thus improving the calcium balance and promoting mineral deposition in the bone matrix. In the absence of calcium, vitamin D can enhance bone resorption while inhibiting bone mineralization, thus maintaining blood calcium homeostasis at the expense of bone mass. Therefore,

adding a proper amount of calcium to the diet can help treat inflammation and maintain the homeostasis of intestinal microbes to prevent osteoporosis mediated by vitamin D (42,43).

3. The mechanism(s) by which intestinal microbes affect bone health

3.1. Immune-mediated mechanisms

Intestinal microflora affect bone remodeling, bone mass accumulation (44), and bone health in a variety of ways (Figure 1). They can impact bone health *via* the immune system (35), which regulates the development of bone marrow cells and inflammatory cytokines. In germ-free (GF) mice, the number of myeloid cell progenitors decreased and the response to *Listeria monocytogenes* was impaired. These defects were remedied by transplantation of complex microbiota. Therefore, gut bacteria mediate innate immune cell development by increasing hematopoiesis (45). GF mice have fewer granulocyte-monocyte progenitors (GMPs). GF mice also have fewer CD11b⁺ Ly6C⁺ mononuclear cells and CD11b⁺ Ly6G⁺ granulocytes in the bone marrow than do specific pathogen-free (SPF) mice, but the formation of bone marrow was improved by the administration of serum isolated from SPF mice (46).

In addition, many studies have recently revealed the close relationship between intestinal microflora and regulatory T cells (Tregs) and helper T cells (Th cells) (31,47-49). *Clostridium* colonization in gnotobiotic mice resulted in preferential accumulation of Tregs in colonic lamina propria (50). The presence of intestinal bacteria might affect both the number and function of Tregs. Transforming growth factor beta (TGF- β), a key regulator of Treg development, is abundant in the colon in its active form. Similar findings were obtained with

regard to other Treg-inducing molecules within the colon (50). Moreover, the induction of interleukin (IL)10-expressing Foxp3⁺ Tregs was specifically restricted in *Clostridium* but not in other bacteria. In addition, CD4⁺, CD25⁺, and Foxp3⁺Treg cells suppress macrophage colony-stimulating factor and osteoclast formation. This action is mainly through cytotoxic T-lymphocyte associated protein 4, an anti-osteoclastogenic molecule that binds osteoclast precursor cells and that inhibits its differentiation (51-53).

The bacterial segment in the gut is the driving force for Th17-assisted cell differentiation, which plays an important role in bone loss induced by rheumatoid arthritis (54,55). Intestinal flora disorders disrupt the balance of the pro-osteoclastogenic pathway and induce osteoclast-mediated bone loss in multiple ways, including the differentiation and inhibition of anti-osteoclastogenic Th1, Th2, and Treg subsets. This induces the differentiation of Th17 cells, which produce and increase RANKL expression on stromal cells, much like inflammatory cytokines (52,56-58). In addition, the number of osteoclast precursor cells also increases, thus promoting osteoclast differentiation (47). Microbial populations affect B cell development as well as bone resorption by osteoprotegerin, an inhibitor of osteoclasts produced by B cells (59).

3.2. Endocrine-mediated mechanisms

Intestinal microflora as a virtual "endocrine organ" (60) have certain effects on bone health. Sex hormones are vital in maintaining bone homeostasis, and a lack of these hormones can result in a decrease of microbial flora in the gut, thus increasing bone loss and affecting bone formation (40). In addition, a lack of sexual hormones increases the activity of osteoclasts and osteoblasts, although osteoclasts are more affected and bone loss is significant (61).

Sex steroid deficiency increases intestinal permeability and levels of the osteoclastogenic cytokines TNF, RANKL, and IL-17 in a murine model while GF mice were protected from bone loss (39). Supplementing the indigenous microbiota with the probiotic *LGG* prevents sex steroid-induced bone loss by inhibiting intestinal permeability. However, ingestion of nonprobiotic or mutant *LGG* eliminates this protective action. These findings indicate that gut microbiota serve as a dual role in sex steroid deficiency-induced bone loss (39). Moreover, excess glucocorticoid reduces the number of both osteoblasts and osteoclasts, it prolongs the lifespan of osteoclasts, and promotes apoptosis of osteoblasts and osteocytes (62,63).

3.3. Changes in intestinal flora affect bone health

Changes in intestinal microbial flora and their metabolites affect bone health directly or indirectly

(47). The effects of microbial flora (64), probiotics (65), antibiotics (66), and dietary nutrition (67) also affect bone health. Probiotic dietary supplements containing *Bacillus licheniformis* and *B. subtilis* increased the diversity of intestinal flora, causing the tibial density in chickens to significantly increase compared to chickens fed a normal diet (68). Antibiotics can affect intestinal flora, and these effects are related to age, sex, and duration of treatment. The bone density of 3-week-old weaning mice dramatically increased when they were exposed to low doses of penicillin, chlortetracycline, or vancomycin compared to 7-week-old weaning mice (69). As a result of continuous treatment with low-dose penicillin (LDP), bone mass decreased in all male mice, regardless of whether or not they were exposed to LDP post-weaning or if the pregnant mother was exposed. These controversial results were replicated in several types of female mice administered LDP. LDP treatment in early life transiently disturbed the microbiota and altered the composition of the microbial community (66,69).

In addition, intestinal flora and different levels of nutrition affect bone health. Several studies transplanted the intestinal microflora of healthy and malnourished infants into sterile mice and found that malnourished infants with transplanted intestinal microorganisms had delayed development and abnormal skeletal muscle development (70). The effect of intestinal flora on bone health can be mediated by metabolites. The intestinal flora can digest soluble grain fiber in the diet into short-chain fatty acids (SCFAs), which lower the pH of the gut, contribute to calcium uptake, and inhibit the formation of osteoclasts (71). The G-protein-coupled receptors GPR40 and GPR120 superficially bind medium- and long-chain fatty acids, and a GPR40/120 agonist inhibits fatty acids in osteoclastogenesis. GPR120 acts as a mediator of the anti-osteoclastogenic action of C16 and C18 fatty acids (72).

4. Intestinal microbial groups and osteogenic/osteoclasts and bone marrow mesenchymal cells

Bone marrow mesenchymal stem cells are pluripotent stem cells that can differentiate into various mesodermal lineages (73). Osteoblasts are the main cells that promote bone development and bone remodeling (74). Osteoblasts directly interact with bone cells, osteoclasts, and hematopoietic stem cells (74), thereby maintaining homeostasis between bone formation and bone resorption (74,75).

Studies have described the interaction between intestinal microflora and bone-related cells. Intestinal microflora influence the expression of peripheral and central serotonin (76). Peripheral serotonin is primarily produced in the gut, and intestinal flora such as indigenous spore-forming bacteria may play a catalytic role in the production of serotonin (77). Peripheral

serotonin functions as a hormone to inhibit osteoblast proliferation through 5-hydroxytryptamine receptor 1B (5-HT1BR) and cAMP response element binding protein (CREB) (78), thereby reducing bone density and bone formation. The level of serotonin expression is lower in the intestinal tract of sterile mice and can be increased by transplanting *E. coli* Nissle 1917 into ileal tissue *ex vivo*, where it interacts with compounds secreted by host tissues (79). The use of probiotics can improve intestinal flora, reduce serotonin content, and alleviate bone disease (65,80). Central serotonin acts as a neurotransmitter to increase bone mass by calmodulin kinase (CaMK)-dependent signaling involving CaMKK β and CaMKV, which are mediated by CREB (76).

Osteoclasts are functionally related to osteoblasts and are involved in bone resorption (35). Intestinal bone signaling pathways and microbial populations play an important role in regulating bone health (64). Decreases in estrogen in postmenopausal women result in an increase in inflammatory factors and osteoclast formation (81). In a model of osteoporosis in OVZ rats, expression of the inflammatory cytokines TNF α and IL-1 decreased, osteoprotegerin levels increased, and osteoclast formation was inhibited (35) when *Lactobacillus* strains and other probiotics were given to OVZ rats (35).

A reduction in the diversity of the intestinal microbiota has been noted and specific taxonomic preferences have been identified in Crohn's disease and ulcerative colitis (6). In a mouse model of ulcerative colitis induced with 2, 4, 6-trinitrobenzene sulfonic acid, bone marrow stromal cells (BMSCs) were implanted in intestinal mucosa, where they repaired damaged intestinal tissue. This may be because BMSCs differentiate into colonic stromal cells and express vascular endothelial growth factor and TGF- β 1 in the injured region (82,83). BMSCs also have immune-regulatory effects on antigen-specific T cells in Crohn's disease through direct cell-cell contact (84), inhibiting allogeneic antigen-specific responses and mitogen-induced proliferation (85), preventing the production of cytotoxic T lymphocytes. In general, there is growing evidence that BMSCs could be used to treat inflammatory bowel disease caused by a disorder in intestinal flora, but the precise molecules and mechanisms responsible for immune regulation need to be ascertained (86).

5. Conclusion

Understanding the correlation between intestinal microbial flora and bone health paves the way for further studies on the treatment of bone diseases by intestinal microbes. Intestinal microbial flora influence bone health through the immune system, endocrine system, and various bone-related cells. An increasing number of studies on osteoporosis have suggested the beneficial effects of probiotics in terms of increasing bone mass.

This provides a basis for treating hereditary bone diseases, which involve abnormal bone, cartilage, joint, and other related tissues due to pathogenic mutations in genes. The relationship between pathogenic mutations that cause genetic bone diseases and intestinal microbial flora remains unclear and needs to be studied further.

Acknowledgements

This project was supported by Grants-in-Aid from the Shandong Government (nos. 2016ZDJS07A10 and 2016GSF201222) and the State Major Infectious Disease Research Program (Chinese Central Government, no. 2017ZX10103004-007).

References

- Lederberg J, McCray AT. 'Ome Sweet 'Omics - A genealogical treasury of words. *Scientist*. 2001; 15:8.
- Qin J, Li R, Raes J, *et al*. A human gut microbial gene catalogue established by metagenomic sequencing. *Nature*. 2010; 464:59-65.
- Hooper LV, Gordon JI. Commensal host-bacterial relationships in the gut. *Science*. 2001; 292:1115-1118.
- Serino M, Luche E, Gres S, *et al*. Metabolic adaptation to a high-fat diet is associated with a change in the gut microbiota. *Gut*. 2012; 61:543-553.
- Abraham C, Cho JH. Inflammatory bowel disease. *N Engl J Med*. 2009; 361:2066-2078.
- Wright EK, Kamm MA, Teo SM, Inouye M, Wagner J, Kirkwood CD. Recent advances in characterizing the gastrointestinal microbiome in Crohn's disease: A systematic review. *Inflamm Bowel Dis*. 2015; 21:1219-1228.
- Sze MA, Schloss PD. Looking for a signal in the noise: Revisiting obesity and the microbiome. *MBio*. 2016; 7:pii: e01018-16.
- Ussar S, Fujisaka S, Kahn CR. Interactions between host genetics and gut microbiome in diabetes and metabolic syndrome. *Mol Metab*. 2016; 5:795-803.
- Pevsner-Fischer M, Blacher E, Tatirovsky E, Ben-Dov IZ, Elinav E. The gut microbiome and hypertension. *Curr Opin Nephrol Hypertens*. 2017; 26:1-8.
- Rosser EC, Mauri C. A clinical update on the significance of the gut microbiota in systemic autoimmunity. *J Autoimmun*. 2016; 74:85-93.
- Gill IS, Canes D, Aron M, Haber GP, Goldfarb DA, Flechner S, Desai MR, Kaouk JH, Desai MM. Single port transumbilical (E-NOTES) donor nephrectomy. *J Urol*. 2008; 180:637-641.
- Yu T, Guo F, Yu Y, Sun T, Ma D, Han J, Qian Y, Kryczek I, Sun D, Nagarsheth N, Chen Y, Chen H, Hong J, Zou W, Fang JY. *Fusobacterium nucleatum* promotes chemoresistance to colorectal cancer by modulating autophagy. *Cell*. 2017; 170:548-563.
- Dash S, Clarke G, Berk M, Jacka FN. The gut microbiome and diet in psychiatry: Focus on depression. *Curr Opin Psychiatry*. 2015; 28:1-6.
- Saulnier DM, Ringel Y, Heyman MB, Foster JA, Bercik P, Shulman RJ, Versalovic J, Verdu EF, Dinan TG, Hecht G, Guarner F. The intestinal microbiome, probiotics and prebiotics in neurogastroenterology. *Gut Microbes*. 2013;

- 4:17-27.
15. Petra AI, Panagiotidou S, Hatzigelaki E, Stewart JM, Conti P, Theoharides TC. Gut-microbiota-brain axis and its effect on neuropsychiatric disorders with suspected immune dysregulation. *Clin Ther.* 2015; 37:984-995.
 16. Gomez de Agüero M, Ganal-Vonarburg SC, Fuhrer T, Rupp S, Uchimura Y, Li H, Steinert A, Heikenwalder M, Hapfelmeier S, Sauer U, McCoy KD, Macpherson AJ. The maternal microbiota drives early postnatal innate immune development. *Science.* 2016; 351:1296-1302.
 17. Zeng MY, Cisalpino D, Varadarajan S, Hellman J, Warren HS, Cascalho M, Inohara N, Núñez G. Gut microbiota-induced immunoglobulin G controls systemic infection by symbiotic bacteria and pathogens. *Immunity.* 2016; 44:647-658.
 18. Abdul-Aziz MA, Cooper A, Weyrich LS. Exploring relationships between host genome and microbiome: New insights from genome-wide association studies. *Front Microbiol.* 2016; 7:1611.
 19. Blekhman R, Goodrich JK, Huang K, Sun Q, Bukowski R, Bell JT, Spector TD, Keinan A, Ley RE, Gevers D, Clark AG. Host genetic variation impacts microbiome composition across human body sites. *Genome Biol.* 2015; 16:191.
 20. Dabrowska K, Witkiewicz W. Correlations of host genetics and gut microbiome composition. *Front Microbiol.* 2016; 7:1357.
 21. Davenport ER. Elucidating the role of the host genome in shaping microbiome composition. *Gut Microbes.* 2016; 7:178-184.
 22. Khachatryan ZA, Ktsoyan ZA, Manukyan GP, Kelly D, Ghazaryan KA, Aminov RI. Predominant role of host genetics in controlling the composition of gut microbiota. *PLoS One.* 2008; 3:e3064.
 23. Tishkoff SA, Reed FA, Ranciaro A, *et al.* Convergent adaptation of human lactase persistence in Africa and Europe. *Nat Genet.* 2007; 39:31-40.
 24. Parche S, Beleut M, Rezzonico E, Jacobs D, Arigoni F, Titgemeyer F, Jankovic I. Lactose-over-glucose preference in *Bifidobacterium longum* NCC2705: *glcP*, encoding a glucose transporter, is subject to lactose repression. *J Bacteriol.* 2006; 188:1260-1265.
 25. Goodrich JK, Waters JL, Poole AC, Sutter JL, Koren O, Blekhman R, Beaumont M, Van Treuren W, Knight R, Bell JT, Spector TD, Clark AG, Ley RE. Human genetics shape the gut microbiome. *Cell.* 2014; 159:789-799.
 26. Vijay-Kumar M, Aitken JD, Carvalho FA, Cullender TC, Mwangi S, Srinivasan S, Sitaraman SV, Knight R, Ley RE, Gewirtz AT. Metabolic syndrome and altered gut microbiota in mice lacking Toll-like receptor 5. *Science.* 2010; 328:228-231.
 27. McKnite AM, Perez-Munoz ME, Lu L, Williams EG, Brewer S, Andreux PA, Bastiaansen JW, Wang X, Kachman SD, Auwerx J, Williams RW, Benson AK, Peterson DA, Ciobanu DC. Murine gut microbiota is defined by host genetics and modulates variation of metabolic traits. *PLoS One.* 2012; 7:e39191.
 28. Arthur JC, Perez-Chanona E, Mühlbauer M, *et al.* Intestinal inflammation targets cancer-inducing activity of the microbiota. *Science.* 2012; 338:120-123.
 29. Beukers AG, Zaheer R, Goji N, Amoako KK, Chaves AV, Ward MP, McAllister TA. Comparative genomics of *Enterococcus* spp. isolated from bovine feces. *BMC Microbiol.* 2017; 17:52.
 30. Marini F, Cianferotti L, Brandi ML. Epigenetic mechanisms in bone biology and osteoporosis: Can they drive therapeutic choices? *Int J Mol Sci.* 2016; 17:E1329.
 31. Ohlsson C, Engdahl C, Fåk F, Andersson A, Windahl SH, Farman HH, Movérare-Skrtic S, Islander U, Sjogren K. Probiotics protect mice from ovariectomy-induced cortical bone loss. *PLoS One.* 2014; 9:e92368.
 32. Britton RA, Irwin R, Quach D, Schaefer L, Zhang J, Lee T, Parameswaran N, McCabe LR. Probiotic *L. reuteri* treatment prevents bone loss in a menopausal ovariectomized mouse model. *J Cell Physiol.* 2014; 229:1822-1830.
 33. Zhang J, Motyl KJ, Irwin R, MacDougald OA, Britton RA, McCabe LR. Loss of bone and *Wnt10b* expression in male type 1 diabetic mice is blocked by the probiotic *Lactobacillus reuteri*. *Endocrinology.* 2015; 156:3169-3182.
 34. Yan J, Herzog JW, Tsang K, Brennan CA, Bower MA, Garrett WS, Sartor BR, Aliprantis AO, Charles JF. Gut microbiota induce IGF-1 and promote bone formation and growth. *Proc Natl Acad Sci U S A.* 2016; 113:e7554-e7563.
 35. Sjögren K, Engdahl C, Henning P, Lerner UH, Tremaroli V, Lagerquist MK, Bäckhed F, Ohlsson C. The gut microbiota regulates bone mass in mice. *J Bone Miner Res.* 2012; 27:1357-1367.
 36. Frank DN, St Amand AL, Feldman RA, Boedeker EC, Harpaz N, Pace NR. Molecular-phylogenetic characterization of microbial community imbalances in human inflammatory bowel diseases. *Proc Natl Acad Sci U S A.* 2007; 104:13780-13785.
 37. Ali T, Lam D, Bronze MS, Humphrey MB. Osteoporosis in inflammatory bowel disease. *Am J Med.* 2009; 122:599-604.
 38. Ghishan FK, Kiela PR. Advances in the understanding of mineral and bone metabolism in inflammatory bowel diseases. *Am J Physiol Gastrointest Liver Physiol.* 2011; 300:G191-201.
 39. Li JY, Chassaing B, Tyagi AM, Vaccaro C, Luo T, Adams J, Darby TM, Weitzmann MN, Mülle JG, Gewirtz AT, Jones RM, Pacifici R. Sex steroid deficiency-associated bone loss is microbiota dependent and prevented by probiotics. *J Clin Invest.* 2016; 126:2049-2063.
 40. Carson JA, Manolagas SC. Effects of sex steroids on bones and muscles: Similarities, parallels, and putative interactions in health and disease. *Bone.* 2015; 80:67-78.
 41. Larmonier CB, McFadden RM, Hill FM, Schreiner R, Ramalingam R, Besselsen DG, Ghishan FK, Kiela PR. High vitamin D3 diet administered during active colitis negatively affects bone metabolism in an adoptive T cell transfer model. *Am J Physiol Gastrointest Liver Physiol.* 2013; 305:G35-G46.
 42. Eisman JA, Bouillon R. Vitamin D: Direct effects of vitamin D metabolites on bone: Lessons from genetically modified mice. *Bonekey Rep.* 2014; 3:499.
 43. van de Peppel J, van Leeuwen JP. Vitamin D and gene networks in human osteoblasts. *Front Physiol.* 2014; 5:137.
 44. Hernandez CJ, Guss JD, Luna M, Goldring SR. Links between the microbiome and bone. *J Bone Miner Res.* 2016; 31:1638-1646.
 45. Khosravi A, Yanez A, Price JG, Chow A, Merad M, Goodridge HS, Mazmanian SK. Gut microbiota promote hematopoiesis to control bacterial infection. *Cell Host Microbe.* 2014; 15:374-381.

46. Balmer ML, Schurch CM, Saito Y, Geuking MB, Li H, Cuenca M, Kovtonyuk LV, McCoy KD, Hapfelmeier S, Ochsenbein AF, Manz MG, Slack E, Macpherson AJ. Microbiota-derived compounds drive steady-state granulopoiesis *via* MyD88/TICAM signaling. *J Immunol.* 2014; 193:5273-5283.
47. Charles JF, Ermann J, Aliprantis AO. The intestinal microbiome and skeletal fitness: Connecting bugs and bones. *Clin Immunol.* 2015; 159:163-169.
48. Asquith M, Elewaut D, Lin P, Rosenbaum JT. The role of the gut and microbes in the pathogenesis of spondyloarthritis. *Best Pract Res Clin Rheumatol.* 2014; 28:687-702.
49. Sjögren K1 EC, Henning P, Lerner UH, Tremaroli V, Lagerquist MK, Bäckhed F, Ohlsson C. The gut microbiota regulates bone mass in mice. *J Bone Miner Res.* 2012 ; 27:1357-1367.
50. Atarashi K, Tanoue T, Shima T, *et al.* Induction of colonic regulatory T cells by indigenous *Clostridium* species. *Science.* 2011; 331:337-341.
51. Zaiss MM, Axmann R, Zwerina J, Polzer K, Guckel E, Skapenko A, Schulze-Koops H, Horwood N, Cope A, Schett G. Treg cells suppress osteoclast formation: A new link between the immune system and bone. *Arthritis Rheum.* 2007; 56:4104-4112.
52. Kong YY, Feige U, Sarosi I, *et al.* Activated T cells regulate bone loss and joint destruction in adjuvant arthritis through osteoprotegerin ligand. *Nature.* 1999; 402:304-309.
53. Adamopoulos IE, Chao CC, Geissler R, Laface D, Blumenschein W, Iwakura Y, McClanahan T, Bowman EP. Interleukin-17A upregulates receptor activator of NF-kappaB on osteoclast precursors. *Arthritis Res Ther.* 2010; 12:R29.
54. Wu HJ, Ivanov II, Darce J, Hattori K, Shima T, Umesaki Y, Littman DR, Benoist C, Mathis D. Gut-residing segmented filamentous bacteria drive autoimmune arthritis *via* T helper 17 cells. *Immunity.* 2010; 32:815-827.
55. Farkas AM, Panea C, Goto Y, Nakato G, Galan-Diez M, Narushima S, Honda K, Ivanov, II. Induction of Th17 cells by segmented filamentous bacteria in the murine intestine. *J Immunol Methods.* 2015; 421:104-111.
56. Sato K, Suematsu A, Okamoto K, Yamaguchi A, Morishita Y, Kadono Y, Tanaka S, Kodama T, Akira S, Iwakura Y, Cua DJ, Takayanagi H. Th17 functions as an osteoclastogenic helper T cell subset that links T cell activation and bone destruction. *J Exp Med.* 2006; 203:2673-2682.
57. Lam J TS, Barker JE, Kanagawa O, Ross FP, Teitelbaum, SL. TNF- α induces osteoclastogenesis by direct stimulation of macrophages exposed to permissive levels of RANK ligand. *J Clin Invest.* 2000; 106:1481-1488.
58. Wei S, WM, Teitelbaum SK, Ross FP. Interleukin-4 reversibly inhibits osteoclastogenesis *via* inhibition of NF- κ B and mitogen-activated protein kinase signaling. *J Biol Chem.* 2002; 277:6622-6630.
59. Wesemann DR. Microbes and B cell development. *Adv Immunol.* 2015; 125:155-178.
60. Clarke G, Stilling RM, Kennedy PJ, Stanton C, Cryan JF, Dinan TG. Minireview: Gut microbiota: The neglected endocrine organ. *Mol Endocrinol.* 2014; 28:1221-1238.
61. Manolagas SC, O'Brien CA, Almeida M. The role of estrogen and androgen receptors in bone health and disease. *Nat Rev Endocrinol.* 2013; 9:699-712.
62. Weinstein RS. Glucocorticoids, osteocytes, and skeletal fragility: The role of bone vascularity. *Bone.* 2010; 46:564-570.
63. Zhou H, Cooper MS, Seibel MJ. Endogenous glucocorticoids and bone. *Bone Res.* 2013; 2:107-119.
64. Parvaneh K, Ebrahimi M, Sabran MR, Karimi G, Hwei AN, Abdul-Majeed S, Ahmad Z, Ibrahim Z, Jamaluddin R. Probiotics (*Bifidobacterium longum*) increase bone mass density and upregulate *sparc* and *Bmp-2* genes in rats with bone loss resulting from ovariectomy. *Biomed Res Int.* 2015; 2015:897639.
65. Collins S, Reid G. Distant site effects of ingested prebiotics. *Nutrients.* 2016; 8:E523. .
66. Cho I, Yamanishi S, Cox L, Methé BA, Zavadil J, Li K, Gao Z, Mahana D, Raju K, Teitler I, Li H, Alekseyenko AV, Blaser MJ. Antibiotics in early life alter the murine colonic microbiome and adiposity. *Nature.* 2012; 488:621-626.
67. Bonjour JP, Kraenzlin M, Levasseur R, Warren M, Whiting S. Dairy in adulthood: From foods to nutrient interactions on bone and skeletal muscle health. *J Am Coll Nutr.* 2013; 32:251-263.
68. Mutus R, Kocabagli N, Alp M, Acar N, Eren M, Gezen SS. The effect of dietary probiotic supplementation on tibial bone characteristics and strength in broilers. *Poult Sci.* 2006; 85:1621-1625.
69. Cox LM, Yamanishi S, Sohn J, *et al.* Altering the intestinal microbiota during a critical developmental window has lasting metabolic consequences. *Cell.* 2014; 158:705-721.
70. Blanton LV, Charbonneau MR, Salih T, *et al.* Gut bacteria that prevent growth impairments transmitted by microbiota from malnourished children. *Science.* 2016; 351:6275.
71. Iwami K, Moriyama T. Effects of short chain fatty acid, sodium butyrate, on osteoblastic cells and osteoclastic cells. *Int J Biochem.* 1993; 25:1631-1635.
72. Cornish J, MacGibbon A, Lin JM, Watson M, Callon KE, Tong PC, Dunford JE, van der Does Y, Williams GA, Grey AB, Naot D, Reid IR. Modulation of osteoclastogenesis by fatty acids. *Endocrinology.* 2008; 149:5688-5695.
73. Pittenger MF MA, Beck SC, *et al.* Multilineage potential of adult human mesenchymal stem cells. *Science.* 1999; 284:5143-5147.
74. Ottewell PD. The role of osteoblasts in bone metastasis. *J Bone Oncol.* 2016; 5:124-127.
75. Prideaux M, Findlay DM, Atkins GJ. Osteocytes: The master cells in bone remodelling. *Curr Opin Pharmacol.* 2016; 28:24-30.
76. Ducy P, Karsenty G. The two faces of serotonin in bone biology. *J Cell Biol.* 2010; 191:7-13.
77. Yano JM, Yu K, Donaldson GP, Shastri GG, Ann P, Ma L, Nagler CR, Ismagilov RF, Mazmanian SK, Hsiao EY. Indigenous bacteria from the gut microbiota regulate host serotonin biosynthesis. *Cell.* 2015; 161:264-276.
78. Yadav VK, Ryu JH, Suda N, Tanaka KF, Gingrich JA, Schütz G, Glorieux FH, Chiang CY, Zajac JD, Insogna KL, Mann JJ, Hen R, Ducy P, Karsenty G. *Lrp5* controls bone formation by inhibiting serotonin synthesis in the duodenum. *Cell.* 2008; 135:825-837.
79. Nzakizwanayo J, Dedi C, Standen G, Macfarlane WM, Patel BA, Jones BV. *Escherichia coli* Nissle 1917 enhances bioavailability of serotonin in gut tissues through modulation of synthesis and clearance. *Sci Rep.*

- 2015; 5:17324.
80. Yun HM, Park KR, Hong JT, Kim EC. Peripheral serotonin-mediated system suppresses bone development and regeneration *via* serotonin 6 G-protein-coupled receptor. *Sci Rep*. 2016; 6:30985.
81. Whisner CM, Martin BR, Schoterman MH, Nakatsu CH, McCabe LD, McCabe GP, Wastney ME, van den Heuvel EG, Weaver CM. Galacto-oligosaccharides increase calcium absorption and gut bifidobacteria in young girls: A double-blind cross-over trial. *Br J Nutr*. 2013; 110:1292-1303.
82. Bonomo A, Monteiro AC, Goncalves-Silva T, Cordeiro-Spinetti E, Galvani RG, Balduino A. A T cell view of the bone marrow. *Front Immunol*. 2016; 7:184.
83. Gattinoni L, Lugli E, Ji Y, *et al*. A human memory T cell subset with stem cell-like properties. *Nat Med*. 2011; 17:1290-1297.
84. Ciccocioppo R, Cangemi GC, Kruzliak P, *et al*. Ex vivo immunosuppressive effects of mesenchymal stem cells on Crohn's disease mucosal T cells are largely dependent on indoleamine 2,3-dioxygenase activity and cell-cell contact. *Stem Cell Res Ther*. 2015; 6:137.
85. Di Nicola M, Carlo-Stella C, Magni M, Milanese M, Longoni PD, Matteucci P, Grisanti S, Gianni AM. Human bone marrow stromal cells suppress T-lymphocyte proliferation induced by cellular or nonspecific mitogenic stimuli. *Blood*. 2002; 99:3838-3843.
86. Ben-Ami E, Berrih-Aknin S, Miller A. Mesenchymal stem cells as an immunomodulatory therapeutic strategy for autoimmune diseases. *Autoimmun Rev*. 2011; 10:410-415.

(Received May 21, 2018; Revised August 12, 2018; Accepted August 17, 2018)

National information system for rare diseases with an approach to data architecture: A systematic review

Simin Derayeh, Alireza Kazemi, Reza Rabiei*, Azamossadat Hosseini, Hamid Moghaddasi

Department of Health Information Technology and Management, Faculty of Paramedical Sciences, Shahid Beheshti University of Medical Sciences, Tehran, Iran.

Summary

The study aims to systematically review literature on the rare diseases information system to identify architecture of this system from a data perspective. The search for relevant English language articles, based on keywords in title, abstract, Mesh and Emtree terms, was done in Pubmed and Embase (from 1980 to June 2017), Scopus, Science Direct and Cochran (from 1980 to July 2017). Articles were selected if they addressed data architecture of information systems with a focus on rare disease, and if at least one of their objectives dealt with design, implementation, and development of rare diseases information systems. Thirty-five studies met the inclusion criteria. The findings were categorized into six groups. This first group addressed organizations acting as data generators, data users, and data governors. The second group was related to data sources and databases. Datasets and data elements formed the third group of findings, including common datasets, specific datasets, and complementary datasets. The fourth group of findings was in relation to data standards. Data sharing and interactions among relevant bodies included the fifth group of the findings. The last group of findings was pertinent to procedures and criteria used for checking the quality of data, as cross review checking was a main procedure assessing the accuracy, consistency, and completeness of data. Design and development of an integrated information system for rare diseases considering data architecture principles in practice could help eliminating issues with management of rare diseases through facilitating sharing information and experiences.

Keywords: Rare disease, information system, data architecture, registry, data set

1. Introduction

A rare disease is a health condition that affects a small number of people in comparison with other common diseases (1,2). In most definitions of rare diseases suggested in various countries, a specific prevalence threshold is assigned for these diseases considering the population of countries and their requirements and policies (2,3). The World Health Organization (WHO) has suggested a frequency of less than 6.5 to 10 per 10,000 people to define rare diseases. In the European

Union (EU), this definition is for less than 5 in 10,000 people (or 1 in 2,000). In the United States of America (USA), a number fewer than 200,000 people has been defined for rare diseases, but less than 50,000 in Japan and less than 2,000 people in Australia (2,3). The majority of countries have referred to the EU definition as their national strategy for rare diseases (2).

In addition to disease prevalence, other criteria common in rare diseases are considered in identifying these diseases (2). For example, these diseases are chronic, progressive, life threatening, body tissues degenerative and causing disability, and there is no curative and effective treatment for the majority of them (2,4). These diseases have genetic origins in 80% of the cases, 50-70% of the patients are children, 30% of patients die before they reach the age of five (4,5). So far, about 5,000 to 7,000 rare diseases have been identified and new rare diseases are regularly reported (2,4). Most of the known diseases are categorized

Released online in J-STAGE as advance publication August 28, 2018.

*Address correspondence to:

Dr. Reza Rabiei, Department of Health Information Technology and Management, Faculty of Paramedical Sciences, Shahid Beheshti University of Medical Sciences, Darband St., Qods Square (Tajrish), Tehran, Iran, Post Code: 1971653313.
E-mail: R.Rabiei@sbm.ac.ir

into several main groups including: metabolic disorders, neuromuscular disorders, blood disorders, cardiovascular and respiratory disorders, autoimmune diseases, skin diseases and rare neoplasms (4).

There are challenges with the management of rare diseases. These challenges include the geographical dispersion of patients and rare diseases specialists, limited number of specialists, the lack of consistency and integrity of studies, limited access to credible sources, and limited information and knowledge (4,6). Development of an integrated information system for rare diseases, for example, at a national level could help to eliminate part of the challenges experienced due to information restrictions (7,8). This issue was emphasized in the main recommendations of the European Union Council on rare diseases in 2013 (9,10). A well-developed information system for rare diseases requires addressing the principles of information systems architecture in practice (7). A key aspect of information systems architecture is data architecture (11,12), consisted of models, standards and methods that depict various data types and the methods for data collection, storage, processing, retrieval, and sharing (12,13). In relation to information system for rare diseases, the data architecture provides an overview of the data that should be available in the information system and provides a concrete infrastructure for data flow and sharing (14).

The main objective of this review is to identify the data architecture of rare diseases information system in the published studies addressing this system in terms of data content and data interactions. By presenting the current literature in rare diseases information systems, it is hoped that this review could contribute to a better understanding of the system data architecture.

2. Data Collection

The search for relevant English language articles, based on keywords in title, abstract, Mesh and Emtree terms, was done in Pubmed and Embase (from 1980 to June

2017), Scopus, Science Direct and Cochran (from 1980 to July 2017). Figure 1 shows the search strategy for identifying the relevant articles. The first part (Part A) included terms used for rare diseases. In the second part (Part B), the keywords related to the data management tools were used. The third part (Part C) contained terms in relation to studies on information system data architecture. The results of these three parts were combined using the Boolean operator "and". Searching was supplemented with checking the bibliographies of identified articles.

Three reviewers examined independently the title and abstracts of the identified articles. Articles were selected if they address data architecture of information systems with a focus on rare diseases, and if at least one of their objectives dealt with design, implementation, and development of rare diseases information systems, and if they studied the network, databases, and registries of these diseases at the regional, national or international level. All studies that merely focused on the design and evaluation of specific software, or data architecture with no focus on rare diseases were excluded. The process and the results of the literature search are illustrated in Figure 2.

3. Data Analysis

Searching the online databases resulted in 3520 articles from Pubmed, Embase, Scopus, Science Direct, and Cochran after removing duplicates. Initial screening of titles and abstracts resulted in 145 articles, of which 113 articles were excluded because they did not address data architecture in relation to rare diseases. Three further articles were identified through checking the bibliographies, leading to a total of 35 articles for full text review (Figure 2).

Considering the geographical origins of the reviewed studies, 20 studies conducted in Europe (8-10,12,15-30), 7 studies in USA (31-37), 4 studies in Australia (38-41) and 4 studies were performed in Asia (42-45).

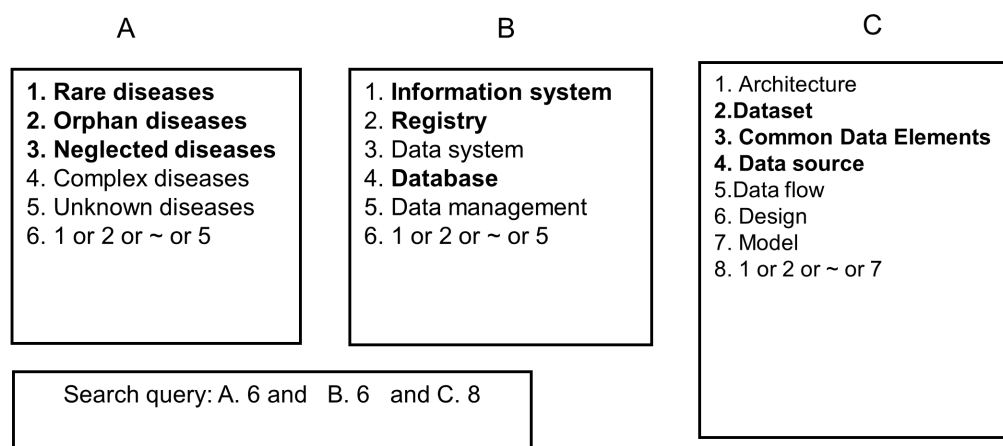


Figure 1. Keywords, Emtree and MeSH terms (bold terms) used in the search strategy.

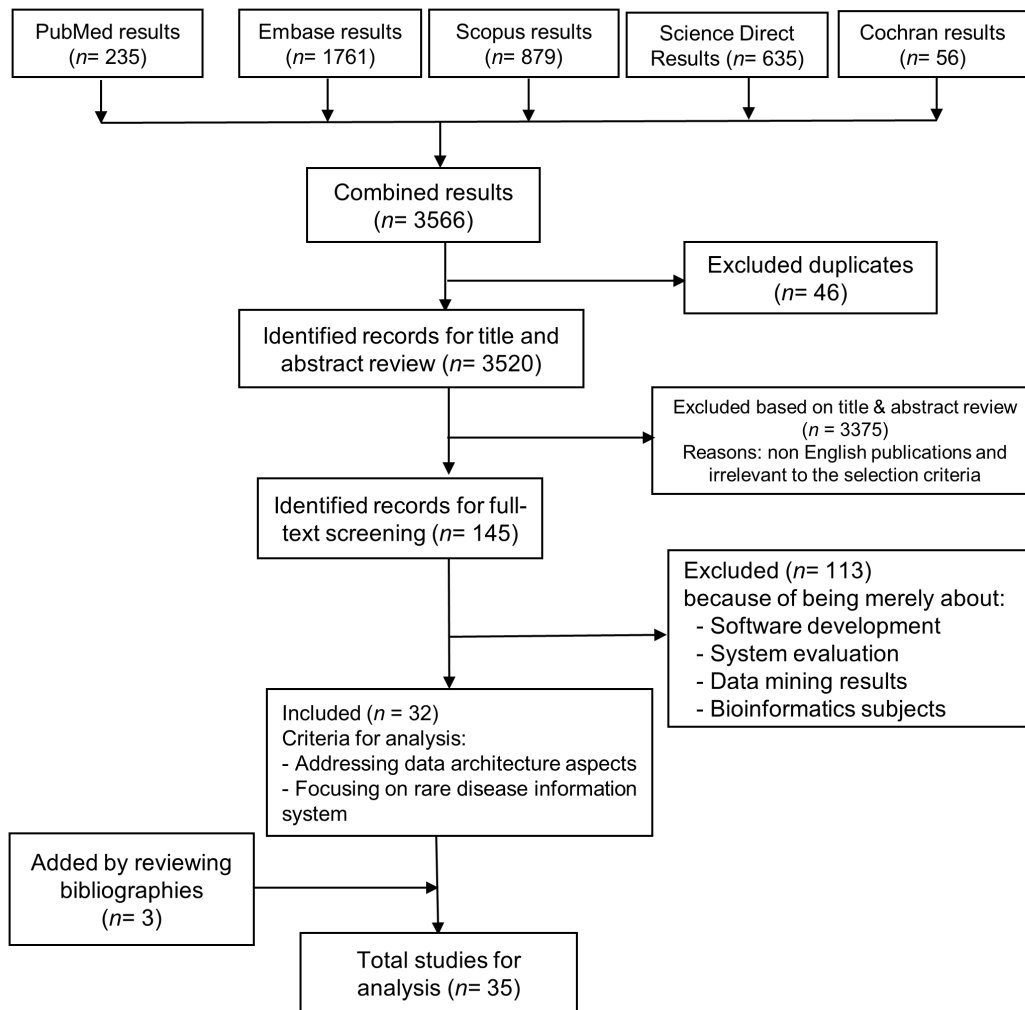


Figure 2. Search flow diagram.

The main findings from the analysis of the studies are categorized in the following six groups, including organization in charge of rare diseases data generation, adoption and governance (10,15,17,18,20-24,27-41,43-45); data sources (8-10,15-18,20-24,26-36,39,40,43,45), datasets, (8-10,15-17,19,21-24,26,28-32,34,37-41) data standards (8,9,16,19-22,24,27,29,32,36,37,43,45), data sharing (15-18,20-22,27-29,31,33-35,38,40,43-45) and data quality (10,15-18,21-25,27,28,30-32,43,45).

3.1. Organizations involved in data generation, adoption, and governance

Identifying the organizations that generate, adopt, and govern data could help to lay the foundation for concrete data architecture of information system for rare diseases. According to the studies, organizations dealing with rare disease information systems could be categorized into three main groups: (i) data-producers (10,17,18,20-23,28,29,31-33,35,36,38-40,44,45), (ii) data users (15,17,18,21-23,27-29,31-35,37-39,41,43-45), and (iii) data coordinators and governors (10,15,17,18,20-24,27-31,33,35-37,45).

Some of these organizations may belong to more than one group. The most important organizations producing rare disease data are clinics, reference centers for rare diseases, hospitals, research consortia, universities and academic centers (21,31,35).

Organizations considered as data-user included research centers, specialized scientific associations, physicians, universities, health managers and policy makers, insurance companies, pharmaceutical companies and medical equipment providers (18,21,27,31,35,38). The third group, i.e., coordinating and governing bodies, are in charge of implementing laws and standards and overseeing activities related to data generation, processing, storage and use to ensure that data are handled in safe and secure manner (18). The Office of Rare Diseases Research (ORDR) at the National Institutes of Health (NIH) in USA (31,35), and the NHS National Institute of Health Research (NIHR) in England (18) are examples of governing organizations.

3.2. Data Sources and Databases

The most significant data sources are the general and

Table 1. Identified common data sources in rare diseases information system and registration networks

Data source (Ref.)	Frequency of studies
Reference centers or clinics (clinical and epidemiological data) (9,10,15-17,20-22,24,31,33,34,39,40,43)	15
Research centers and consortia (research data) (10,31,33,35,43,45)	6
Patient self-reported data (15-18,23,26,28,31-33,39)	11
Laboratory, genetics and imaging data (15,16,28,30,31,34,35,40,45)	9
Specific databases or registries for diseases (9,17,18,28,29,32,34,36,43)	9
Data from cohort studies (15,18,20,23,24,31)	6
Medical Records (Electronic Medical Records, Electronic Health Records, Primary Care Records) (8,9,17,18,20,24,32,34,36,43,45)	11
Biobanks and bio-specimen (29,32)	2
Drug registry (9,28,31,35)	4
Birth registry (8,9,21,22,40)	5
Death registry (9, 24)	2

specialized rare diseases clinics and research centers, which are the most important producers of clinical and epidemiological data for these diseases. Furthermore, data can be captured from hospitals, research centers, bio-banks. In some systems, it is possible for patients or their relatives to enter data related to disease progress, the quality of their lives and other issues (15,16,31,39). A summary of the data sources is categorized in Table 1.

3.3. Datasets and data elements

Twenty three studies addressed datasets and their related data elements. The datasets are categorized into three main groups: a common dataset for rare diseases, specific datasets, and complementary or extended dataset. Common dataset and its data elements were mentioned in 22 studies (8-10,15-17,19,21-24,26,28-32,37-41). This dataset includes data elements applied to a wide range of rare diseases, such as patients' demographic data, different types of rare diseases, centers delivering services to patients, medication history and medical records of patients, family history, prenatal and neonatal records (Table 2). Eight studies indicated the data elements required for a specific dataset (8,10,17,19,21,26,34,39). This dataset includes data specific to a particular rare disease and is only applied for the same disease. The dataset for Cystinosis, Nephronophytosis, Turner Syndrome and Neonatal Diabetes (21) are examples of this type of dataset. The extended dataset includes data elements that are not available in the two aforementioned groups, but they add to, and improve, the knowledge about rare diseases. This category includes high encouraged data such as the experiences of patients and care givers, and data from studies addressed a particular aspect and conducted on an ad hoc basis (8,10,15,16,24,26).

3.4. Data standards

Fifteen studies showed the application of terminologies, nomenclatures, and international classifications of diseases including ICD 10, Systematized Nomenclature of Medicine-Clinical Terms (SNOMED-CT), and

Logical Observation Identifiers Names and Codes (LOINC), as well as information exchange standards such as HL7 for data organization, developing datasets, and data sharing. The most commonly used standards are listed in Table 3. Classification systems such as ICD 10, Online Mendelian Inheritance in Man (OMIM) and ORPHA-codes were the most used systems.

3.5. Data sharing

Nineteen studies indicated data sharing among different bodies. Data sharing among parties such as scientific and academic communities, clinics, and the national database of rare diseases was reported in 12 studies (15-17,21,22,27-29,31,33-35). Data exchange of central registry with the local databases or registries were indicated in 12 studies (20-22,27-29,31,33,38,40,43,45).

Data interactions among academies, research centers and clinics were reported in 10 studies (18,20-22,27,31,33,35,38,44). In addition, seven studies indicated data sharing of patients or their relatives with registries of rare diseases (17,18,29,31,33,35,40).

3.6. Data quality control

The necessity of controlling the quality of data generated in the information systems was highlighted in 17 studies. In 14 studies, the data producers were in charge of data quality control (15-17,21,22,24,25,27,28,30-32,43,45); and in 8 studies, data coordinators and governors took this responsibility (10,15,16,18,24,27,31,45). In some studies, bodies such as quality control committees or departments (10,16,23) and independent experts (10,17,25,30,43) were in charge of checking the quality of data.

Table 4 demonstrates a summary of the main data quality control procedures together with criteria used in this respect. Ten studies referred to cross review checking as a routine for checking the quality of data through applying measures including accuracy, consistency, and completeness. Checking for duplications and missing data were among the other approaches for controlling data quality focusing mainly on the adequacy of data.

Table 2. The main categories of Common Data Elements in rare diseases registration and information system

Core Data category	Data Elements Instances	Frequency of Studies	Ref.
Demographic data	- Sex - Age (or date of birth) - Education level - Occupation - City and country of birth - City and country of residence - Contact details - Date of death	17	(8,9,15-17,21-24,26,30,32,37-41)
Diagnosis	- Date of current diagnosis - Status of diagnosis - Proof of diagnosis	15	(8,9,15-17,19,21-24,26,30,37,40,41)
Care pathway	- Type and name of treatment center - Referring physician - Center patient referred to - Documented visits - Date of contact	7	(8,16,17,26,30,37,39)
Medical history and medication	- Date of first treatment - Symptoms and date of onset of symptoms - Birth and reproductive history - Prenatal and neonatal information - Physical examination - Treatment strategy - Orphan drug treatment - Type of tests & results	20	(8,9,15-17,19,21-24,26,28,30,32,36-41)
Family history		9	(8,15-17,19,24,36,37,40)
Research and bio- banks data	- Patient participation in trials - Bio specimen storing in biobanks	6	(8,16,24,26,28,43)

Table 3. The most commonly used data standards

Category	Standard	Frequency of Studies	Ref.
Terminology and classification			
Code set	LOINC	3	(8,36,37)
Diagnostic Classification Systems	ICD 10	6	(9,16,20,27,29,43)
	ICD-9-CM or ICD 9	2	(9,27)
	Specific International Classification systems	9	(9,16,20,27,29,32,36,37)
Nomenclature	SNOMED-CT	7	(8,9,19,27,32,36,37)
Classification & Code Sets	ORPHA-codes	9	(8,9,19-22,27,29,43)
Information interchange	HL7	3	(8,32,36)
Gene codes set	OMIM	10	(8,16,19-22,24,27,43,45)

Table 4. The most common procedures conducted for controlling data quality

Quality Control Procedure	Data Quality Criteria	Frequency of Studies	Ref.
Predefined quality criteria for data	- Completeness - Accuracy	5	(10,23,25,27,30)
Cross review checking	- Accuracy - Consistency - Completeness	10	(15-18,23-25,28,30,32)
Checking for missing data	- Completeness - Adequacy	3	(15,23,31)
Checking for duplications	- Adequacy - Accuracy	5	(21,22,25,27,45)
Unification of data format	- Consistency	2	(23,43)
Double entry of part of all data	-Accuracy	2	(23,25)

Accuracy, as a data quality measure, was referred to in all of the studies that remarked the necessity of controlling data quality.

4. Discussion

Over the past two decades, there has been an increasing attention to rare diseases and managing these diseases (6). France, the United Kingdom (UK), and the United States are viewed as pioneer countries in terms of legislation, setting standards, developing of a network infrastructure for rare diseases, and creating information systems for these diseases (6,10,18,21,27,29-31,35,37).

4.1. Organizations involved in data generation and governance

Different organizations are dealing with rare diseases data. Continued monitoring and financial support by coordinators and governors could help data producer organizations to generate data considering data quality requirements. Data producer organizations, in turn, could feed governor organizations by high quality data to set and update relevant policies. In addition, data user organizations, such as research and care centers could have improved performance when using high quality data.

One of the main issues with management of rare diseases data is collecting data by different organizations in parallel resulted in data redundancy and duplication of efforts. Organizations such as research centers, clinics and hospitals may have their own exclusive databases for data collection. Developed countries have design and implemented a national integrated information network for managing rare diseases data, in which governing organizations play a coordinating role to avoid duplication of data collection (31,32).

4.2. Data sources and datasets

As the findings showed, there are a variety of data sources for a rare disease information system. Developing a national rare disease information system with the capability of data sharing with different data sources has a key role to play in efficient data management (9,46).

Due to the diversity of data sources, it is very challenging to determine a certain dataset for rare diseases. Common and specific datasets are two main datasets for rare diseases, in which the association between the common and specific datasets could be depicted in the form of a flower known as the Petal model (17). In this model, the common dataset constitutes the central core of the flower and the specific datasets of each rare disease make the petals and can be gradually added to the core part (17,21). In developed countries, work groups and specialized consortia are in charge of defining specific datasets for each of the rare

diseases groups (8,26,35,47).

The findings indicated the diversity of rare diseases data and data sources causing difficulties with data management. This issue could be eliminated through developing an integrated information system and the application of data standards.

4.3. Data standards

The use of standards could improve data quality and the interoperability of systems (8). In relation to the terminology and classification standards, these standards could be used to report the results of diagnostic tests (8,21,22), classify the conditions and provided services for statistical analysis, and reimburse of the costs (20,27,29). Since no standard for diagnostic codes is yet created for the classification of rare diseases, many countries have been using ICD-10. However, this disease classification lacks many of rare diseases and genetic disorders and does not fully support the detailed classification of these diseases (21,22,48). To overcome this issue, there have been global efforts coordinated by the World Health Organization to develop classification codes for rare diseases (5,48). Currently, a greater compatibility with the majority of genetic rare diseases is anticipated in ICD 11. Therefore, it is highly recommended to use ICD 11 and the ORPHA-codes simultaneously, as a valid ontology for rare diseases, although the alignment of ORPHA codes with SNOMED-CT, ICD-10 and OMIM is still in progress and requires further development (5,17,48). Some European countries such as France, use ORPHA codes rather than ICD-10 and SNOMED-CD (21,22), and this could be due the ORPHA codes being more specific and allowing better organization of rare diseases data.

4.4. Data sharing

With respect to data sharing, standards such as the HL7 support the exchange of data. This standard facilitates data sharing among different organizations, such as health and research centers, as well as policy making organizations (8,31,35). As findings indicated, different types of data could be shared among different bodies (46). Data sharing of health and research centers with the rare diseases registry is a main type of data interaction. Knowing that the most of bodies involved in data sharing are considered as both data producers and data users, their interactions with rare diseases registry is often two-dimensional, as they could send clinical and epidemiological data to the registry and receive information such as the relationship between phenotype and genotype characteristics of any rare disease (18,27,46). Another important type of data sharing could be seen between a central database or registry and other databases or specialized registries. In

this type of data sharing, the central registry acts as a hub and interacts with other registries (20,43).

4.5. Data quality control

The other key aspect of data architecture for rare diseases deals with laying the foundation for checking the quality of data, as the use of standards could improve the efficient use of the information system when data quality is addressed. Therefore, applying data quality procedures could help to ensure the quality of data.

5. Conclusion

To eliminate the challenges with the management of rare diseases, development of an integrated information system considering data architecture is crucial. Identifying data sources, defining datasets and data elements, and defining the interactions between data sources could help to design an integrated rare disease information system that could facilitate information sharing and provide the opportunity for sharing experiences at regional, national, and even transnational levels.

Acknowledgements

This study was part of a PhD project conducted at Shahid Beheshti University of Medical Sciences.

References

- Gupta H, Badapanda C, Ghosh A, Chikara S. Rare DDB: An Integrated Catalog of Rare Disease Database. *Clin Med Biochem.* 2016; 2:111. doi:10.4172/2471-2663.1000111
- Richter T, Nestler-Parr S, Babela R, Khan ZM, Tesoro T, Molsen E, Hughes DA; International Society for Pharmacoeconomics and Outcomes Research Rare Disease Special Interest Group. Rare Diseases Terminology and Definitions- A systematic Global Review: Report of the ISPOR Rare Disease Special Interest Group. *Value Health.* 2015; 18:906-914.
- Aronson JK. Rare diseases and orphan drugs. *Br J Clin Pharmacol.* 2006; 61:243-245.
- Zmazek V. EURORDIS Rare diseases Europ. What is a Rare disease. http://www.mz.gov.si/fileadmin/mz.gov.si/pageuploads/kakovost/Redke_bolezni/prezentacija_2_Vlasta_Zmazek_EURORDIS.pdf (accessed June 15, 2018)
- The UK strategy for Rare Diseases. In: Department of Health. London: Crown, 2015. p. 1-35. https://assets.publishing.service.gov.uk/government/uploads/system/uploads/attachment_data/file/260562/UK_Strategy_for_Rare_Diseases.pdf (accessed June 15, 2018)
- Schieppati A, Henter JI, Daina E, Aperia A. Why rare diseases are an important medical and social issue. *Lancet.* 2008; 371:2039-2041.
- Elze R, Fähnrich K P. The dispedia Framework: A Semantic Model for Medical Information Supply. *ICONS International Conference on Systems.* 2013; 59-63.
- Choquet R, Maaroufi M, de Carrara A, Messiaen C, Luigi E, Landais P. A methodology for a minimum data set for rare diseases to support national centers of excellence for healthcare and research. *J Am Med Inform Assoc.* 2015; 22:76-85.
- Zoni AC, Domínguez Berjón MF, Barceló E, Esteban Vasallo MD, Abaitua I, Jiménez Villa J, Margolles Martins M, Navarro C, Posada M, Ramos Aceitero JM, Vázquez Santos C, Zurriaga Llorens O, Astray Mochales J; Spain-RDR Group. Identifying data sources for a national population- based registry; the experience of the Spanish Rare diseases Registry. *Public Health.* 2015; 129:271-275.
- Vittozzi L, Gainatti S, Mollo E, Donati C, Taruscio D. A Model for the European platform for Rare Disease Registries. *Public Health Genomics.* 2013; 16:299-304.
- Winter A, Haux R, Ammenwerth E, Brigl B, Hellrung N, Jahn F. *Health Information Systems Architecture and Strategies.* 2nd ed. (Hannah K, Ball M, eds). Springer, London, UK, 2011; pp. 51-73.
- Costechi N, Moisescu MM, Scacala S, Colin AM. Enterprise Architecture for e-Health System. The 4th IEEE International Conference on E-Health and Bioengineering-EHB. Popa University of Medicine and Pharmacy, Iasi, Romania., IEEE. 2013. DOI: 10.1109/EHB.2013.6707265
- Cavalcanti JC. Effects of IT on Enterprise Architecture, Governance, and Growth. IGI Global, Hershey PA, USA, 2015; pp. 148-149.
- Yilmaz S, Jonveaux P, Bicep C, Pierron L, Smail-Tabbone M, Devignes MD. Gene-disease relationship discovery based on model-driven data integration and database view definition. *Bioinformatics.* 2009; 25:230-236.
- Evangelista T, Wood L, Torron RF, Williams M, Smith D, Lunt P, Hudson J, Norwood F, Orrel R, Willis T, Hilton-Jones D, Rafferty K, Guglieri M, Lochmuller H. Design, set-up and utility of the UK facioscapulohumeral muscular dystrophy patient registry. *J Neurol.* 2016; 263:1401-1408.
- Farmer A, Aymé S, de Heredia ML, Maffei P, MacCafferty S, Mlynarski W, Nunes V, Parkinson K, Paquis-Flucklinger V, Rohayem J, Sinnott R, Tillmann V, Tranebjærg L, Barrett T.G. EURO-WABB: an European rare diseases registry for wolfram syndrome, Alstrom syndrome and Bardet-Biedl syndrome. *BMC Pediatrics.* 2013; 13:130.
- Kingswood JC, Bruzzi P, Curatolo P, *et al.* TOSCA-first international registry to address knowledge gaps in the natural history and management of tuberous sclerosis complex. *Orphanet J Rare Dis.* 2014; 9:182.
- Javaid MK, Foretier-Zhang L, Watts L, *et al.* The RUDY study platform- a novel approach to patient driven research in rare musculoskeletal diseases. *Orphanet J Rare Dis.* 2016; 11:150.
- Jaulent M-C, Asséle-Kama A, Savard S, Giavarini A, Touzé E, Jeunemaitre X, Ugon A, Plouin PF, Toubiana L. Building a Semantic Interoperability Framework for Care and Research in Fibromuscular Dysplasia. *Stud Health Technol Inform.* 2015; 216:217-221.
- Toubiana L, Ugon A, Giavarini A, Riquier J, Charlet J, Jeunemaitre X, Plouin PF, Jaulent MC. A "Pivot" Model to Set up Large Scale Rare Diseases Information Systems: Application to the Fibromuscular Dysplasia Registry. *Stud Health Technol Inform.* 2015; 210:887-89.
- Landais P, Messiaen C, Rath A, *et al.* CEMARA an

- information system for rare diseases. *Stud Health Technol Inform.* 2010; 160:481-485.
22. Messian C, Le Mignot L, Rath A, *et al.* CEMARA: a Web Dynamic Application within a N-tier Architecture for Rare Diseases. *Stud Health Technol Inform.* 2008; 136:51-56.
 23. D'Agnolo HM, Kievit W, Andrade RJ, Karlsen TH, Wedemeyer H, Drenth JP. Creating an effective clinical registry for rare diseases. *United European Gastroenterol J.* 2016; 4:333-338.
 24. Nagel G, Unal H, Rosenbohm A, Ludolph AC, Rothenbacher D. Implementation of a population-based epidemiological rare disease registry: Study protocol of the amyotrophic lateral sclerosis (ALS)-registry Swabia. *BMC Neurol.* 2013; 13:22.
 25. Lill CM, Bertram L. Developing the "Next Generation" of Genetic Association Databases for Complex diseases. *Hum Mutat.* 2012; 33:1366-1372.
 26. Taruscio D, Mollo E, Gainotti S, Posada de la Paz M, Bianchi F, Vittozzi L. The EPIRARE proposal of a set of indicators and common data elements for the European platform for rare disease registration. *Arch Public Health.* 2014; 72:35.
 27. Taruscio D, Gainotti S, Mollo E, Vittozzi L, Bianchi F, Ensini M, Posada M. The current Situation and Needs of Rare Disease Registries in Europe. *Public Health Genomics.* 2013; 16:288-298.
 28. Pareyson D, Fratta P, Pradat PF, Soraru G, Finsterer J, Vissing J, Jokela M.E, Udd B, Ludolph A.C, Sagnelli A, Weydt P. Towards a European Registry and Biorepository for Patients with Spinal and Bulbar Muscular Atrophy. *J Mol Neurosci.* 2016; 58:394-400.
 29. Thompson R, Johnston L, Taruscio D, *et al.* RD-Connect: An integrated platform connecting database, registries, biobanks and clinical bioinformatics for rare disease research. *J Gen Intern Med.* 2014; 29:s780-s787.
 30. Taruscio D, Vittozzi L, Choquet R, Heimdal K, Iskvov G, Kodra Y, Landais P, Posada M, Stefanov R, Steinmueller C, Swinnen E, Van Oyen H. National Registries of Rare Diseases in Europe: An Overview of the Current Situation and Experiences. *Public Health Genomics.* 2015; 18:20-25.
 31. Krischer JP, Gopal_Srivastava R, Groft SC, Eckstein DJ. The Rare diseases clinical Research Network's Organization and Approach to Observational Research and Health Outcomes Research. *J Gen Intern Med.* 2014; 29(suppl 3):739-744.
 32. Rubinstein YR, Groft SC, Bartek R, *et al.* Creating a Global Rare Disease Patient Registry Linked to a Rare Diseases Biorepository Database: Rare Disease-HUB (RD-HUB). *Contemp clin Trials.* 2010; 31:394-404.
 33. Richesson RL, Sutphen R, Shereff D, Krischer JP. The Rare Diseases Clinical Research Network Contact Registry Update: Features and Functionality. *Contemp clin Trials.* 2012; 33:647-656.
 34. Rubinstein YR, McInnes P. NIH/NCATS/GRDR Common Data Elements: A leading force for standardized data collection. *Contemp clin Trials.* 2015; 42:78-80.
 35. Groft SC, Gopal_Srivastava R. A model for collaborative clinical research in rare diseases: Experience from the rare disease clinical research network program. *Clin Invest.* 2013; 3:1015-1021.
 36. Richesson R, Shereff D, Andrews J. [RD] PRISM Library: Patient Registry Item Specifications and Metadata for Rare Diseases. *J Libr Metadata.* 2010; 10:119-135.
 37. Daneshvari S, Youssof S, Kroth PJ. The NIH Office of Rare Diseases Research Patient Registry Standard: A Report from the University of New Mexico's Oculopharyngeal Muscular Dystrophy Patient Registry. *AMIA Annu Symp proc.* 2013; 269-277.
 38. Bellgard MI, Macgregor A, Janon F, Harvey A, O'Leary P, Hunter A, Dawkins H. A Modular Approach to Disease Registry design: Successful adoption of an Internet-based Rare disease Registry. *Hum Mutat.* 2012; 33:E2356-E2366.
 39. Bellgard MI, Napier KR, Bittles AH, Szer J, Fletcher S, Zeps N, Hunter AA, Goldblatt J. Design of a framework for the deployment of collaborative independent rare disease-centric registries: Gaucher disease registry model. *Blood Cells Mol Dis.* 2018; 68:232-238.
 40. Louise S, Fyfe S, Bebbington A, Bahi-Buisson N, Anderson A, Pineda M, Percy A, Zeev BB, Wu XR, Bao X, Leod PM, Armstrong J, Leonard H. InterRett, a model for international data collection in a rare genetic disorder. *Res Autism Spectr Disord.* 2009; 3:639-659.
 41. Bellgard MI, Beroud C, Parkinson K, Harris T, Ayme S, Baynam G, Weeramanthri T, Dawkins H, Hunter A. Correction: Dispelling myths about rare disease registry system development. *Source Code Biol Med.* 2013; 8:21.
 42. Song P, He J, Li F, Jin C. Innovative measures to combat rare diseases in China: The national rare diseases registry system, larger-scale clinical cohort studies, and studies in combination with precision medicine research. *Interactable Rare Dis Res.* 2017; 6:1-5.
 43. Seo H, Kim D, Chae JH, Kang HG, Lim BC, Cheong HI, Kim JH. Development of Korean Rare disease knowledge base. *Health Inform Res.* 2012; 18:272-278.
 44. Song P, Gao J, Inagaki Y, Kokudo N, Tang W. Intractable and rare diseases research in Asia. *BioSci Trends.* 2012; 6:48-51.
 45. Sinha S, Black ML, Agarwal S, Das R, Bittles AH, Bellgard MI. ThalInd, $\alpha\beta$ -Thalassemia and Hemoglobinopathies Database for India: Defining a model country-specific and disease-centric bioinformatics resource. *Hum Mutat.* 2011; 32:887-893.
 46. Kole A, Ensini M, Cam YI. Proposed aims, scope, governance and sustainability options for a European platform for rare disease registries. In: *European Organization for Rare Diseases, EURODIS, Paris; 2013: 1-20.*
 47. Minimum Data Set for Rare Disease Registries. In: *EUCERD Joint Action. 2015. http://www.eucerd.eu/wp-content/uploads/2015/03/WP8_Registries_MDS.pdf (accessed June 15, 2018).*
 48. Coding of rare diseases in health information systems with Orphacode. In: *EUCERD Joint Action. 2014. Available from: http://www.eucerd.eu/wp-content/uploads/2014/10/WP5_WSReport_Ispra_Oct2014.pdf (accessed June 15, 2018).*

(Received June 17, 2018; Revised August 20, 2018; Accepted August 22, 2018)

Assessment of the impact of an exercise program on the physical and functional capacity in patients with autosomal recessive spastic ataxia of Charlevoix-Saguenay: An exploratory study

Olivier Audet¹, Hung Tien Bui², Maxime Allisse³, Alain-Steve Comtois⁴, Mario Leone^{3,*}

¹ Department of Kinesiology, Université Laval, Québec, Canada;

² Department of Applied Sciences, Université du Québec à Chicoutimi, Saguenay, Canada;

³ Department of Health Sciences, Université du Québec à Chicoutimi, Saguenay, Canada;

⁴ Department of Exercise Sciences, Université du Québec à Montréal, Montréal, Canada.

Summary

Autosomal recessive spastic ataxia of Charlevoix-Saguenay (ARSACS) is a neuromuscular disorder caused by the mutation of the SACS gene. Clinical symptoms of this disease include progressive ataxia, spasticity, and peripheral neuropathy. Similar to other neuromuscular disorders, these patients are prone to physical deconditioning which may lead to a loss of functional capacity. This paper aims to evaluate the impact of a training program on the physical fitness and the functional capacity of ARSACS patients. Twelve patients (age: 28.1 ± 8.2 years) participated in this study. They followed an eight-week training program including physical activities, strength-power and aerobic training. Compared to the initial evaluation, measures of physical fitness and functional capacity were significantly improved ($p \leq 0.05$) for 11 of the 12 tests. Positive gains were also observed for fall frequency and for upper-limb incoordination. This paper supports the importance of a training program for ARSACS patients in order to improve their quality of life. Through these types of interventions, it may be possible to slow down the progression of the disease and help maintain functional capacity.

Keywords: ARSACS, Ataxia, exercise training, functional capacity, upper-limb incoordination

1. Introduction

Autosomal recessive spastic ataxia of Charlevoix-Saguenay (ARSACS) is a rare disease which has been documented for the first time by Bouchard *et al.* in 1978 (1). The discovery of the disease's etiology is recent, and the pathology basis and the mechanical physiopathology are not fully understood. Located on chromosome 13, a mutation of the SACS gene hinders the proper production of the saccin protein (4,579-aa), which is the cause of ARSACS. This disruption leads

to an abnormal dendrite morphology which affects the transfer of nerve impulses and consequently leads to the death of Purkinje cells in the cerebellum (2). The main clinical symptoms associated to this disease are progressive ataxia, spasticity and peripheral neuropathy (3). ARSACS is a hereditary disease that is specific to the Charlevoix and Saguenay-Lac-Saint-Jean (CSLSJ) regions (4,5). Like other recessive diseases, ARSACS has a high prevalence in these regions while it is rare worldwide. Nevertheless, some cases were observed in countries like Japan, Italy, Tunisia and Turkey (6).

ARSACS, as with other neuromuscular/neurological diseases, generally brings patients to be less active and causes physical deconditioning (7,8). This could result in an important decrease in functional capacity and could even lead to a premature loss of autonomy. Actual best practice management of ARSACS patients is mostly palliative and is not sufficient to maintain their quality of life.

Recent research demonstrated that physical activity

Released online in J-STAGE as advance publication August 15, 2018.

*Address correspondence to:

Dr. Mario Leone, Department of Health, Kinesiology Division, Université du Québec à Chicoutimi, 555 boulevard de l'Université, Saguenay (Québec), G7H 2B1, Canada.

E-mail: mario.leone@uqac.ca

and training have a positive impact on patients with pathologies similar to ARSACS. More precisely, results show a positive association between strength training and certain symptoms of neuromuscular disorder (NMD) and neurological conditions (9-21). Furthermore, as demonstrated by several authors (8,12,17,22-25), patients affected by certain NMD can even improve their locomotor skills following specific training programs. However, to our knowledge, the impact of physical training has not yet been established with ARSACS patients.

Thus, the objective of this paper is to evaluate the impact of an exercise program on the physical fitness and the functional capacity of patients affected by ARSACS. Based on results from existing NMD studies, our hypothesis is that the exercise program will have a positive impact on ARSACS patients by increasing their physical fitness level and, consequently, their functional capacity.

2. Materials and Methods

2.1. Participants

Twelve early-onset ARSACS patients (5 males and 7 females) aged between 17-45 years (28.1 ± 8.2 years) participated in this study. They were recruited from a list provided by Muscular Dystrophy Canada. Traditionally, the severity of the disease in ARSACS patients is typically evaluated in clinic based on walking mobility (3,26) rather than using a standardized scale. While several ataxia severity scales exist, such as the Scale for the Assessment and Rating Ataxia - SARA (27) and the International Cooperative Ataxia Rating Scale - ICARS (28), they do not consider all three components of the disease (pyramidal, cerebellar and neuropathic) in order to provide a more complete picture. In addition, none of these scales have been validated in patients with ARSACS. Even though it is conceptually possible to perform a combination of these severity scales, it is not a viable option due to large number of items that need to be evaluated. Participants were thus classified by severity according to their ability to walk: light ($n = 5$, walking without aid), moderate ($n = 3$, walking aid required) and severe ($n = 4$, wheelchair-bound).

All participants were at least sixteen years of age, which is the legal age at which a person can give their consent to participate in a study according to the applicable local laws. To be included in the study, participants must have been diagnosed with ARSACS through genetic testing. The only exclusion criterion was to have received medical contraindications for the practice of physical activities. All participants gave their informed written consent to participate in this research, which was approved by the University Ethics Committee Board (No.602.381.01).

2.2. Testing protocol

During the first week, all participants were assessed using 5 strength and 7 functional tests, for a total of 12 assessment tests. Assessments were separated into two 90-minute sessions to ensure optimal performance. There were 12 stations, each corresponding to a different test, and participants went through each one sequentially. Between each station, there was a two-minute rest period. This same procedure was also followed during the last (ninth) week of the program.

2.3. Physical fitness tests

Assessment of physical fitness was performed using conventional weight training equipment. During the first week, a maximum strength test was administered for each of the 5 strength exercises (Figure 1) identified using the one-repetition maximal load (1RM). Since it is difficult and time-consuming to precisely establish the maximum load that can only be lifted once, the maximum load was established from the 1RM table suggested by Baechle *et al.* (29). In order to estimate the 1RM, the maximum number of repetitions accepted was 6 without which the participant had to start again with a load increased by 20%.

To assess abdominal strength, the participant was seated in front of the pulley and held the rope handle on his chest. The aim is to lift the heaviest possible load by bending the trunk forward to an angle of 90° (Figure 1A).

Upper-limb strength (bench press) was measured while the participant was sitting. The arms are bent at 90° at shoulder height. The participant would then lift the load with a complete extension of the arms (Figure 1B).

The biceps curl was assessed while the participant was seated with elbows supported in extension (180°) and hands in supine position. The participant would then lift the load (flexion of the elbows) with both arms in order to reach a vertical position with arms bent at 50° - 60° (Figure 1C).

Maximal muscle strength of the quadriceps was measured on a knee extension device (Figure 1D). While the participant was seated, their feet were placed under the cushioned roll while the thigh-calf angle is at 90° . The load was lifted with a full extension of the knees which represents 180° .

Finally, pectoral strength was assessed using a pectoral fly device (Figure 1E). In the sitting position, the participant had their arms open so that they form an angle of 180° while the elbows are bent at 90° . From this position, the elbows were bent forward by a movement towards the median plane (adduction).

2.4. Functional capacity tests

Functional capacity was evaluated using parts of the testing protocol proposed by Kalinova and Leone (30)




Figure 1. Pictures of the training devices used with ARSACS patients. (A) Abdominal strength; (B) Bench press; (C) Biceps curls; (D) Knee extension; (E) Pectoral fly.

which include one-hand plate tapping, sit-and-stand, six-minute walk test and the hand grip strength test (Table 1). In addition, a Swiss ball was used to assess trunk stability/balance, a bench press test was used to evaluate muscular endurance of the upper-limbs, a 10m-walk test assessed the maximal walking speed and a questionnaire was used to evaluate the frequency of falls within the previous week.

The one-hand plate tapping test, which assesses the speed of the upper-limbs, consisted of moving laterally the dominant hand as quickly as possible by touching alternatively each of the two circles which were separated by a distance of 60 cm. The result is expressed as the total number of hits within 20 seconds (nb·20s⁻¹).

The sit-and-stand test requires participants to sit and rise from a standard chair without using their arms. The test ended after 20 seconds during which the number of sit-and-stand was counted (nb·20s⁻¹).

The bench press test allows for the measurement of the participant's capacity to move a load that represents 40% of 1RM as many times as possible within 20 seconds (nb·20s⁻¹). The total number of repetitions was noted.

Several reliable test batteries, such as the Berg

Table 1. Description of factors and variables used to assess ARSACS patients for functional capacity and physical fitness evaluations

Factors	Variables
Functional capacity variables	
Speed (upper limbs)	1- One-hand plate tapping (nb·20s ⁻¹)
Speed (lower limbs)	2- Sit-and-stand (nb·20s ⁻¹)
Endurance (upper limbs)	3- Bench press (nb·20s ⁻¹)
Balance	4- Swiss ball balance test (s)
Grip strength	5- Hand grip strength (kg)
Functional capacity to walk	6- Six-minute walk test (m)
Walking maximal speed	7- 10m-walk test (s)
Physical fitness variables	
Maximum muscle strength	8- Abdominal strength (kg)
	9- Bench press (kg)
	10- Biceps curls (kg)
	11- Knee extension (kg)
	12- Pectoral fly (kg)

Number of repetitions (nb) ; Kilogram (kg); Second (s); Watts (w); Meter (m).

balance scale, can be used to evaluate balance and/or stability in the general population. However, since the majority of the participants are either wheelchair bound

Table 2. Specific parameters of the strength and the power training

Items	Parameter	Strength training	Power training
Week 1	Initial evaluation	-	-
Week 2	Set	1	1
	Repetition	3-6	6-8
	Rest period	2 minutes	1 minute
	Load	80% of 1 RM	40% of 1 RM
Weeks 3 to 8	Set	2	1
	Repetition	3-6	6-8
	Rest period	2 minutes	1 minute
	Load	80% of 1 RM	40% of 1 RM

1 RM = One repetition maximum.

Table 3. Specific parameters of the aerobic training

Week	Session 1		Session 2		Weekly volume (min)
	Set × [minutes ran (r) and/or walked (w)]		Set × [minutes ran (r) and/or walked (w)]		
1	Initial evaluation		Initial evaluation		Initial evaluation
2	1 × (15r)		1 × (15r)		30
3	3 × (4 r/1w)		8 × (1r/1w)		31
4	4 × (4r/1w)		10 × (1r/1w)		40
5	1 × 21r		11 × (1r/1w)		43
6	5 × (4r/1w)		12 × (1r/1w)		49
7	4 × (5r/1w)		13 × (1r/1w)		50
8	4 × (6r/1w)		13 × (1r/1w)		54

or require a walking aid, most items in the balance scale would not be feasible. Therefore, the Swiss ball trunk stability test with eyes open, proposed by Noehren and colleagues, was used (31). This test determines the participant's capacity to maintain their stability/balance in a seated position while having one foot in contact with the ground. The final score corresponds to the length of time (s) that the participant was able to remain seated on the Swiss ball without using their hands or the free leg. The test can also end if the participant succeeds to maintain balance for one minute.

The hand grip test (manual dynamometer; Takei Kiki Kogyo model tk-1210, Japan) allows for the measurement of the maximal strength developed by the finger joints and the forearm. Two trials for each hand were allowed and the sum of the best score for each hand was noted (kg).

The six-minute walk test is a popular method of assessing the walking ability of individuals affected by different conditions. This test was administered according to the procedure described by American Association of Cardiovascular and Pulmonary Rehabilitation (32) for patients who are able to walk with or without walking aid. Wheelchair patients performed the test using their own wheelchair. The results are expressed as the distance (m) traveled in 6 minutes.

The 10m-walk test consists in traveling a distance of 10m as fast as possible (33). The original procedure was slightly modified by adjusting the distance to 10m instead of the more common typical 7.62 m distance. Patients were allowed to use their wheelchairs

or walking aid when needed. The results of the test correspond to the time (s) required to complete the total 10m distance.

In addition, upper-limb coordination was also assessed using a computerized version of the Archimedes spiral test (34). Results were extracted and frequency analysis was performed in order to examine smoothness of movement, which is a good indicator of coordination. Finally, participants completed a questionnaire aiming to assess, on a scale from 1 (never) to 10 (very often), the impact of the program on the frequency of their falls (pre vs. post-training).

The eight-week training program consists of two 90-minute sessions every week. The content of each training session depends on the degree of severity of the disease. For the lightly and moderately affected groups, the sessions were divided into three parts: *i*) 30 minutes of physical activities or sports (volleyball, badminton, etc.); *ii*) 30 minutes of strength and power training using resistance training devices; *iii*) 30 minutes of aerobic fitness training on an indoor track or an aerobic training machine (treadmill, bicycle, rowing machine). The group consisting of severely affected patients did not participate in the physical activities and sports portion of the training. Instead, their training only focused on strength and power exercises (45 minutes) and aerobic fitness (45 minutes). This ensures that both groups have the same training volume. The specific parameters of the training program are presented in Table 2 (strength and power exercises) and Table 3 (aerobic fitness). Each training session was supervised by two qualified kinesiologists.

Table 4. ARSACS patient performance on functional capacity evaluations

Variables	Pre-training (<i>n</i> = 12)	Post-training (<i>n</i> = 12)	<i>p</i> -values	Cohen's <i>d</i> Effect Size
1. Plate tapping (nb·20s ⁻¹)	49.8 ± 14.1	56.0 ± 13.6	0.003	0.45
2. Sit-and-stand (nb·20s ⁻¹)	8.3 ± 3.0	10.1 ± 2.2	0.007	0.68
3. Bench press (nb·20s ⁻¹)	16.8 ± 9.2	21.5 ± 9.3	0.003	0.51
4. Swiss ball balance test (s)	4.3 ± 5.8	6.7 ± 7.9	0.003	0.35
5. Hand grip strength (kg)	54.8 ± 20.8	60.1 ± 21.5	0.005	0.25
6. Six-minute walk test (m)	318.7 ± 120.4	375.6 ± 131.6	0.008	0.45
7. 10m-walk test (s)	9.1 ± 6.4	8.1 ± 4.6	0.117	0.18

Descriptive statistics are presented as means and standard deviation (mean ± SD). Bold characters indicate statistical significance at $p < 0.05$. Cohen's *d* coefficient: 0.20 small; 0.50 medium; 0.80 large. Number of repetitions (nb).

Table 5. ARSACS patient performance on physical fitness evaluations

Variables	Pre-training (<i>n</i> = 13)	Post-training (<i>n</i> = 13)	<i>p</i> -values	Cohen's <i>d</i> Effect Size
Physical fitness				
1. Abdominal strength (kg)	31.4 ± 7.9	44.1 ± 11.7	0.003	1.10
2. Bench press (kg)	56.0 ± 27.4	76.1 ± 41.7	0.003	0.58
3. Biceps curls (kg)	21.2 ± 8.7	26.8 ± 8.0	0.005	0.67
4. Knee extension (kg)	58.8 ± 20.9	75.5 ± 26.9	0.002	0.69
5. Pectoral fly (kg)	41.2 ± 18.4	49.8 ± 19.6	0.003	0.45
Fall frequency				
1. Number of falls (nb/week)	2.9 ± 1.7	1.7 ± 0.8	0.015	0.90

Descriptive statistics are presented as means and standard deviation (mean ± SD). Bold characters indicate statistical significance at $p < 0.05$. Cohen's *d* coefficient: 0.20 small; 0.50 medium; 0.80 large.

2.5. Statistical analysis

Participants' physical fitness and functional capacity measurements are reported as mean ± standard deviation (SD). Because of the small sample size and violation of normality test assumptions, nonparametric paired-samples Wilcoxon signed-rank tests were used to analyze the differences between pre and post-training evaluations. Cohen's *d* coefficients were calculated in order to estimate the effect sizes (ES). All statistical analyses were performed using SPSS version 24. Finally, values of $p \leq 0.05$ were established as significant.

3. Results

3.1. Functional capacity and physical fitness evaluations

Table 4 and Table 5 present the results of the physical fitness and functional capacity tests. They show that most tests (11 out of 12) display statistically significant improvements between the initial and the final evaluations. When considering functional capacity, 6 out of 7 tests showed significant differences (one-hand plate tapping, sit-and-stand test, bench press (muscular endurance), Swiss ball balance test, hand grip strength, six-min walk test). The majority of functional tests showed ES values ranging from moderate to large (Table 4). Results obtained for the 10m-walk test revealed no significant improvement. With respect to physical fitness evaluations, all 5 tests showed significant

differences between pre and post-training periods (Table 5). Their calculated ES ranged from moderate to very high.

3.2. Questionnaire on the frequency of falls

Answers to the questionnaire on the frequency of falls (Table 5) reveal that there is a significant difference ($p = 0.04$) between pre-training scores (2.2) and post-training scores (3.2). The calculated ES is considered moderate (0.5).

3.3. Upper-limb coordination

Figures 2A, 2B and 2C show the superimposed spiral traces drawn by all participants. Figure 2A shows the results of spiral traces performed by ARSACS patients before training whereas Figure 2B shows the results after the eight-week program. For the purpose of comparison, Figure 2C presents spiral traces produced by 36 healthy age-matched participants. It shows a spiral shape of a certain thickness that illustrates that even healthy participants deviate a little from the reference.

Compared to Figure 2C, the spiral traces from Figure 2A were markedly entangled. After an eight-week training program, the spiral traces produced by the participants became visibly less entangled (Figure 2B). Pre and post-training results of frequency analysis were compared and *p*-values for each frequency are plotted in Figure 2D. The figure indicates that frequency

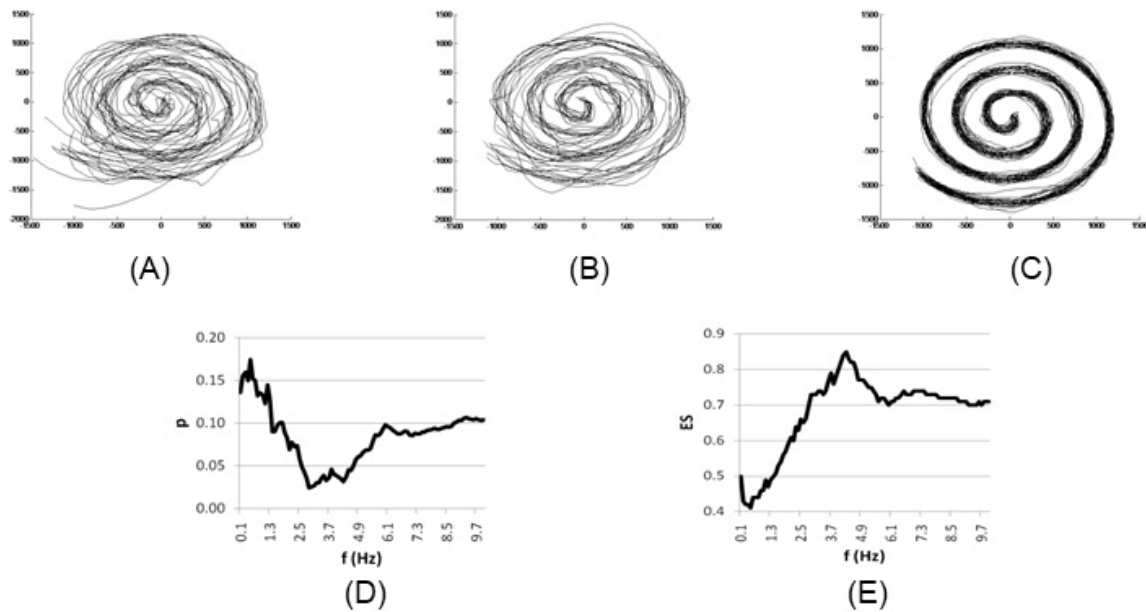


Figure 2. Comparison between ARSACS patients before (A) and after training (B); Spiral trace performed by healthy participants (C); p values related to the statistical significance of differences between trained and untrained ARSACS patients (D); ES coefficients related to the clinical differences between trained and untrained ARSACS patients (E).

components between 2.5 Hz and 4.7 Hz showed significant changes after the exercise program. Figure 2D shows the result of the comparison (p value) for each frequency between pre and post-training. Beyond the statistical significance, the values of the ES coefficients highlight the clinical importance of the changes in the level of ataxia (Figure 2E). At $f = 4.3$ Hz, the ES coefficients reached a maximum value of 0.85, indicating a high clinical impact.

4. Discussion

Results of this study support the hypothesis that an eight-week specific training program improves physical fitness and functional capacity of ARSACS patients. This demonstration is similar to what was observed in the case of neuromuscular (9,18) or neurological conditions (10,19). This study is, to our knowledge, the first one to assess the impact of an exercise program on the physical fitness and functional capacity of patients affected by ARSACS.

4.1. Impact of resistance training on muscle strength and functional capacity

The strength-power training program generated positive adaptations in a number of muscular groups. In addition, according to the evaluation, functional capacity was also improved. This is interesting as there was no specific exercise aimed at improving functional capacity. This can be partially explained by Bohannon's theory (35) which hypothesizes that a gain in strength improves the neuronal condition between the agonist and the

antagonist muscles, which enhances the execution of certain functional tasks.

4.2. Changes in walking ability and balance

The participants recruited in this study were initially considered inactive. As the study progressed, their walking ability improved possibly due to the development of their aerobic capacity, lower limb strength and balance. The results of the questionnaire revealed that participants fell less often at the end of the eight-week training program. This outcome may be attributed to benefits obtained from the strength-power training program. Indeed, strength and power have often been associated to fall prevention and the results from this study support those findings (36-38).

Comparison between pre and post-training for the 10m-walk test showed no significant differences. As well, the ES value was also modest. Several reasons may explain this result. The most likely explanation is that this test was not well adapted to the chosen population. In fact, ARSACS patients in our sample formed a very heterogeneous group with some who are able to walk and others who are wheelchair-bound. When the four wheelchair patients were excluded from the analysis, the 10m-walk test became statistically significant ($p = 0.05$). Despite this result, the ES values remain fairly modest, with values below 0.25. Indeed, steady-state aerobic training is not known to contribute to improve the performance in a walking speed task. In addition, strength and power training of leg muscles, without specific sprint training, will likely not improve the performance of the 10m-walk test.

4.3. Impact of upper-limb strength training program on movement incoordination

Upper-limb coordination of ARSACS patients, as measured by the Archimedes spiral test, showed statistical and clinical improvement after the eight-week training program. These changes can be observed when visually comparing the superimposed spiral traces pre and post training. In addition, these visual differences also reflect changes in frequency analysis results. Indeed, analysis was performed on a large range of frequencies and results showed significant differences on certain frequency bands between pre and post-training. These results support previous observations that certain frequency bands are more sensitive than others in evaluating incoordination (34). Indeed, the work of Bui *et al.* has shown that frequency analysis is a very sensitive tool to discriminate healthy participants from ARSACS patients, particularly between 1.2 Hz and 1.7 Hz. In this study, after an eight-week training period, the ARSACS patients significantly improved their frequency analysis scores between frequency bands of 2.5 Hz and 4.7 Hz. This difference in frequency bands suggests that the training program helps improve coordination, as measured by the spiral test, but does not necessarily improve frequency components that distinguish ARSACS participants from healthy ones. While there were no coordination-specific exercises performed during the program, the authors believe that physical fitness training was a major contributor in this positive change. Indeed, a better stability of the shoulder, due to improved shoulder girdle strength, may be responsible for coordination gain and decreased symptoms of ataxia.

4.4. Study limitations

Due to the fact that ARSACS is a rare disease, the number of participants was limited to twelve. While it may seem like a small number, it is important to state that there are only about 300 known cases of ARSACS in the CSLSJ region. In addition, the problem with limited participation is also common in others studies with rare NMD (39). A second limitation of this study is that the training period consisted of eight weeks and that no conclusions can be drawn on its impact in the long-term. Finally, the absence of a control group can be considered a limitation. However, since the objective of this study was to examine the response to physical exercise, pre and post-training evaluations seem to indicate promising results on their physical autonomy.

5. Conclusion

This study presents an eight-week exercise program and its effect on the physical fitness and functional capacity of people affected by ARSACS. To our knowledge, this is the first study that evaluates the impact of training on

the ARSACS population. While this is still a preliminary study, our results suggest that physical training does not have a deleterious effect on their musculoskeletal and/or cardiorespiratory functions. In fact, results of pre and post-training assessments show that most tests (11 out of 12) presented significant improvement. For instance, maximal strength evaluations suggest that muscular capacity can be improved following a resistance training program. These results also seem to contribute to improving functional capacity even though no specific exercises were prescribed, which is in accordance with Bohannon's theory. In addition, since ES values range from moderate to high for most variables studied, these changes seem to suggest that important improvements can be obtained from a patient's clinical perspective in day-to-day activities. Indeed, as indicated by the significant reduction in the frequency of falls and by the large value of the effect size, these results can be seen as a global indicator of the potential benefits of this type of intervention.

The overall positive change observed in these patients provides an encouraging sign that it is possible to help ARSACS patients maintain or regain their autonomy. This can have a positive impact both on an economic and a social level.

Acknowledgements

The authors wish to thank *Muscular Dystrophy Canada and Ataxia Charlevoix-Saguenay* for their time, materials and the funding which allowed us to conduct this research. We would also like to thank all participants who volunteered to participate in this study.

References

1. Bouchard JP, Barbeau A, Bouchard R, Bouchard RW. Autosomal recessive spastic ataxia of Charlevoix-Saguenay. *Can J Neurol Sci.* 1978; 5:61-69.
2. Girard M, Larivière R, Parfitt DA, *et al.* Mitochondrial dysfunction and Purkinje cell loss in autosomal recessive spastic ataxia of Charlevoix-Saguenay (ARSACS). *Proc Natl Acad Sci USA.* 2012; 109:1661-1666.
3. Duquette A, Brais B, Bouchard JP, Mathieu J. Clinical presentation and early evolution of spastic ataxia of charlevoix-saguenay. *Mov Disord.* 2013; 28:2011-2014.
4. Heyer E, Tremblay M, Desjardins B. Seventeenth-century European origins of hereditary diseases in the Saguenay population (Quebec, Canada). *Hum Biol.* 1997; 69:209-225.
5. Thiffault I, Dicaire MJ, Tetreault M, *et al.* Diversity of ARSACS mutations in French-Canadians. *Can J Neurol Sci.* 2013; 40:61-66.
6. Takiyama Y. Autosomal recessive spastic ataxia of Charlevoix-Saguenay. *Neuropathology.* 2006; 26:368-375.
7. Anziska Y, Sternberg A. Exercise in neuromuscular disease. *Muscle Nerve.* 2013; 48:3-20.
8. Roeder L, Costello JT, Smith SS, Stewart IB, Kerr GK. Effects of resistance training on measures of muscular strength in people with Parkinson's disease: A systematic

- review and meta-analysis. *PLoS One*. 2015; 10:e0132135.
9. Lambert CP, Archer RL, Evans WJ. Muscle strength and fatigue during isokinetic exercise in individuals with multiple sclerosis. *Med Sci Sports Exerc*. 2001; 33:1613-1619.
 10. Mantrria S, Fullarda ME, Duda JE, Morley JF. Physical activity in early Parkinson disease. *J Parkinsons Dis*. 2018; 8:107-111.
 11. Logan LR. Rehabilitation techniques to maximize spasticity management. *Top Stroke Rehabil*. 2011; 18:203-211.
 12. Stevenson VL. Rehabilitation in practice: Spasticity management. *Clin Rehabil*. 2010; 24:293-304.
 13. Labruyère R, van Hedel HJA. Strength training versus robot-assisted gait training after incomplete spinal cord injury: A randomized pilot study in patients depending on walking assistance. *J Neuroeng Rehabil*. 2014; 11:4.
 14. Reid S, Hamer P, Alderson J, Lloyd D. Neuromuscular adaptations to eccentric strength training in children and adolescents with cerebral palsy. *Dev Med Child Neurol*. 2010; 52:358-363.
 15. Krivickas LS. Exercise in Neuromuscular Disease. *J Clin Neuromuscul Dis*. 2003; 5:29-39.
 16. Richardson D. Physical therapy in spasticity. *Eur J Neurol*. 2002; 9:17-22.
 17. Voet NB, van der Kooi EL, Riphagen II, Lindeman E, van Engelen BG, Geurts AC. Strength training and aerobic exercise training for muscle disease. *Cochrane Database Sys Rev*. 2013; 7:CD003907.
 18. Surakka J, Romberg A, Ruutiainen J, Aunola S, Virtanen A, Karppi SL, Mäentaka K. Effects of aerobic and strength exercise on motor fatigue in men and women with multiple sclerosis: A randomized controlled trial. *Clin Rehabil*. 2004; 18:737-746.
 19. Ferraz DD, Trippo KV, Duarte GP, Neto MG, Bernardes Santos KO, Filho JO. The effects of functional training, bicycle exercise, and exergaming on walking capacity of elderly patients with Parkinson disease: A pilot randomized controlled single-blinded trial. *Arch Phys Med Rehabil*. 2018; 99:826-833.
 20. Snider J, Müller ML, Kotagal V, Koeppel RA, Scott PJ, Frey KA, Albin RL, Bohnen NI. Non-exercise physical activity attenuates motor symptoms in Parkinson disease independent from nigrostriatal degeneration. *Parkinsonism Relat Disord*. 2015; 21:1227-31.
 21. Aitkens SG, McCrory MA, Kilmer DD, Bernauer EM. Moderate resistance exercise program: Its effect in slowly progressive neuromuscular disease. *Arch Phys Med Rehabil*. 1993; 74:711-715.
 22. Adams MM, Hicks AL. Comparison of the effects of body-weight-supported treadmill training and tilt-table standing on spasticity in individuals with chronic spinal cord injury. *J Spinal Cord Med*. 2011; 34:488-494.
 23. Mayer M. Clinical neurokinesiology of spastic gait. *Bratisl Lek Listy*. 2002; 103:3-11.
 24. Adams MM. Assessment and activity-based management of spasticity after spinal cord injury. (Master thesis). McMaster (ON): McMaster University; 2008.
 25. Dietz V, Harkema SJ. Locomotor activity in spinal cord-injured persons. *J Appl Physiol*. 2004; 96:1954-1960.
 26. Gagnon C, Lessard I, Brais B, Côté I, Lavoie C, Synofzik M, Mathieu J. Validity and reliability of outcome measures assessing dexterity, coordination, and upper limb strength in autosomal recessive spastic ataxia of Charlevoix-Saguenay. *Arch Phys Med Rehabil*. 2018; doi: 10.1016/j.apmr.2018.01.
 27. Schmitz-Hübsch T, du Montcel ST, Baliko L, *et al*. Scale for the assessment and rating of ataxia: Development of a new clinical scale. *Neurology*. 2006; 66:1717-1720.
 28. Trouillas P, Takayanagi T, Hallett M, *et al*. International Cooperative Ataxia Rating Scale for pharmacological assessment of the cerebellar syndrome. The Ataxia Neuropharmacology Committee of the World Federation of Neurology. *J Neurol Sci*. 1997; 145:205-211.
 29. Baechle TR, Earle RW, Wathen D. Resistance training. In: Baechle TR, Earle RW (eds): *Essentials of strength training and conditioning*. 2nd ed. Champaign (IL): Human Kinetics; 2000.
 30. Kalinova E, Leone M. Tests d'évaluation de la capacité fonctionnelle chez l'adulte de 55 ans et mieux (Assessment of functional capacity in adults aged 55 and over). Presses de l'Université du Québec, Québec (QC), Canada, 2009. (in French)
 31. Noehren B, Abraham A, Curry M, Johnson D, Ireland ML. Evaluation of proximal joint kinematics and muscle strength following ACL reconstruction surgery in female athletes. *J Orthop Res*. 2014; 32:1305-1310.
 32. American Association of Cardiovascular and Pulmonary Rehabilitation. *Guidelines for pulmonary rehabilitation programs* (2nd ed.). Champaign (IL): Human Kinetics; 1993.
 33. Bohannon RW, Andrews AW, Thomas MW. Walking speed: Reference values and correlates for older adults. *J Orthop Sports Phys Ther*. 1996; 24:86-90.
 34. Bui HT, Audet O, Mathieu J, Gagnon C, Leone M. Computer-based assessment of upper-limb incoordination in autosomal recessive spastic ataxia of Charlevoix-Saguenay patients: A pilot study. *J Neurol Sci*. 2017; 380:68-73.
 35. Bohannon RW. Muscle strength and muscle training after stroke. *J Rehabil Med*. 2007; 39:14-20.
 36. Kilmer DD. Response to resistive strengthening exercise training in humans with neuromuscular disease. *Am J Phys Med Rehabil*. 2002; 81:121-126.
 37. Allen NE, Sherrington C, Canning CG, Fung VS. Reduced muscle power is associated with slower walking velocity and falls in people with Parkinson's disease. *Parkinsonism Relat Disord*. 2010; 16:261-264.
 38. Toole T, Park S, Hirsch MA, Lehman DA, Maitland CG. The multicomponent nature of equilibrium in persons with parkinsonism: A regression approach. *J Neural Transm*. 1996; 103:561-580.
 39. Gschwind YJ, Kressig RW, Lacroix A, Muehlbauer T, Pfenninger B, Granacher U. A best practice fall prevention exercise program to improve balance, strength/power, and psychosocial health in older adults: Study protocol for a randomized controlled trial. *BMC Geriatr*. 2013; 13:105.

(Received June 4, 2018; Revised June 27, 2018; Accepted June 29, 2018)

Multidrug resistant *Elizabethkingia meningoseptica* bacteremia – Experience from a level 1 trauma centre in India

Aishwarya Govindaswamy¹, Vijeta Bajpai¹, Vivek Trikha², Samarth Mittal²,
Rajesh Malhotra², Purva Mathur^{1,*}

¹ Department of Microbiology & Hospital Infection Control, Jai Prakash Narayan Apex Trauma Centre, All India Institute of Medical Sciences, New Delhi, India;

² Department Orthopaedics, Jai Prakash Narayan Apex Trauma Centre, All India Institute of Medical Sciences, New Delhi, India.

Summary

Elizabethkingia meningoseptica (*E. meningoseptica*) is a non-fermenting gram negative organism that is commonly detected in the soil and water but is rarely reported to cause human infection. However it is emerging as a nosocomial pathogen in patients admitted in intensive care units (ICUs). Infections caused by this organism have a high mortality rate due to lack of effective therapeutic regimens and its intrinsic resistance to multiple antibiotics. We report our experience in managing *Elizabethkingia meningoseptica* (*E. meningoseptica*) septicemia in our ICU patients with septic shock during prolonged intensive care management. Over a two year period four cases were admitted into the polytrauma ICU developed sepsis due to *E. meningoseptica*. All these patients were on mechanical ventilation, had central venous catheter (CVC) and were exposed to various broad spectrum antibiotics. Of the four patients, three died and one recovered. *E. meningoseptica* infection should be considered as a possible etiological agent of sepsis in patients who do not respond to empirical therapy, as this results in an inappropriate choice of antimicrobial therapy, leading to increased morbidity and mortality of patients. Its unusual resistance pattern along with inherent resistance to colistin makes this organism difficult to treat unless susceptibility patterns are available.

Keywords: *Elizabethkingia meningoseptica* (*E. meningoseptica*), septicemia, Intensive Care Unit (ICU), multi-drug resistance

1. Introduction

Elizabethkingia species are gram negative bacilli which are aerobic, oxidase positive, indole positive, non-motile bacilli and does not ferment glucose. They can be found commonly in freshwater, saltwater, soil and in hospital environments (1). They do not normally exist in the human body, but have been reported to cause various invasive infections like meningitis, pneumonia, endocarditis, and bacteremia in adults and neonates in association with severe underlying illness (2). The risk factors associated with acquisition of

this infection include immunosuppression, underlying medical diseases, prolonged hospital stay, prior use of higher antibiotics, indwelling central venous catheter and other invasive devices (3). This organism is resistant to many antibiotics like beta-lactam antibiotics, aminoglycosides, tetracyclines, and chloramphenicol. However, it is susceptible to some agents used to treat Gram-positive bacteria like erythromycin, clindamycin, rifampicin, trimethoprim-sulfamethoxazole, quinolones and vancomycin (4). Selecting appropriate antimicrobial agents for patients infected with *E. meningoseptica* is difficult due to lack of data on clinical response to different treatments and also due to multiple drug resistance. In this report, we describe a series of four cases with *E. meningoseptica* bacteraemia and septic shock admitted to the ICUs of our level 1 Trauma Centre.

2. Patients and Methods

This is a retrospective study conducted over a two

Released online in J-STAGE as advance publication August 28, 2018.

*Address correspondence to:

Dr. Purva Mathur, Department of Microbiology & Hospital Infection Control, Jai Prakash Narayan Apex Trauma Centre, All India Institute of Medical Sciences, New Delhi 110029, India.

E-mail: purvamathur@yahoo.co.in

year period from June 2016 - May 2018 at our level 1 Trauma Centre. During the above time frame, four cases admitted in the polytrauma ICU developed sepsis due to *Elizabethkingia meningoseptica*. Blood cultures of these patients grew *E. meningoseptica* which were identified up to the species level by VITEK 2 GN card (version 7.02, BioMérieux, Inc. Durham, USA). Antimicrobial susceptibility testing was performed by Kirby-Bauer disc diffusion method on Muller Hinton agar and by Vitek 2 (BioMérieux) system. The MICs were interpreted based on the Clinical and Laboratory Standard Institute (CLSI) criteria for other non-*Enterobacteriaceae*. Patient's details and clinical data included sex, age, diagnosis at admission, presence of central venous catheter, dates and dosages of antibiotic drug administration, dates of catheter removal, and outcome of bacteraemia were recorded. The reports of culture of other samples were also recorded.

2.1. Case 1

A 54 year old male patient admitted with history of Road Traffic Accident (RTA), presented with loss of consciousness during admission. On examination, the patient was intubated from an outside hospital, stable haemodynamically, the Glasgow Coma Scale (GCS) being E4VTM5. The case was suspected to have head injury with chest trauma, abdominal injury and pelvic fracture along with fracture of long bones (Polytrauma). On local examination of the right leg, the patient had swelling, tenderness and deformity. X-ray finding revealed intertrochanteric fracture of femur following which the patient was started on intravenous (IV) augmentin 1.2 gram and injection metrogyl 750mg IV stat and operated on an emergency basis and was shifted to polytrauma ICU. On 3rd post-operative day in the ICU, the patient developed high grade fever along with pus from the operated site. The pus culture grew *Acinetobacter baumannii* sensitive to colistin and tigecycline. Based on the culture reports,

the patient was started on colistin 4.5 million IU IV BD and meropenem 1gram IV TDS for 14 days. Despite two weeks of antibiotic treatment, the patient still had persistent fever. The antibiotic was changed to IV tigecycline 50 mg BD. Total leucocyte count (TLC) was 13,350 cells/mm³ (4,500 - 11,000), hemoglobin 9.5 g/dL (13 - 15), sodium 136 meq/L (145 - 150), potassium 4.8 meq/L (3.5 - 5.5) and chlorides were 105 meq/L (96 - 106). The symptoms persisted with increasing TLC counts, thrombocytopenia and raised procalcitonin levels 2.53 ng/mL (normal < 0.15) suggestive of sepsis. Two sets of blood cultures were sent, one from central line and one from peripheral line. Both the cultures grew *E. meningoseptica* which was resistant to most of the antibiotics. The MICs of various antibiotics are shown in Table 1. The patient was started on IV levofloxacin and inotropic support. Despite all possible resuscitative measures the patient had a fatal outcome on the 42nd day of hospitalization.

2.2. Case 2

A 30 year old female was admitted in our emergency department following history of fall due to which she had sustained injury on the right side of the hip. On local examination there was tenderness, swelling, painful and restricted movements. X-ray revealed intertrochanteric fracture with proximal femoral nail (PFNA) in situ. The patient was started on injection cefoperazone/sulbactam 2 gm IV BD, injection levofloxacin 750 gm IV OD. She was operated on an elective basis and shifted to the orthopaedic ward. During the 14th postoperative day, the patient developed fever, hypotension, and generalised edema with tachycardia and was shifted to the ICU. In the ICU, the antibiotics were escalated to injection colistin 1 million units IV TDS and injection meropenem 1 gm IV TDS. Multiple blood cultures were sent. The blood culture sent on the 13th day of ICU stay grew *E. meningoseptica* sensitive to cefepime-tazobactam and piperacillin-

Table 1. Antimicrobial susceptibility profile of *E. meningoseptica* isolated from four cases

Antibiotics	Minimum Inhibitory concentration (MIC)			
	Isolate 1	Isolate 2	Isolate 3	Isolate 4
Amikacin	≥ 64(R)	≥ 64(R)	≥ 64(R)	≥ 64(R)
Gentamicin	≥ 16(R)	≥ 16(R)	≥ 16(R)	≥ 32(R)
Cefepime	≥ 64(R)	≥ 32(R)	≥ 64(R)	≥ 64(R)
Cefoperazone	≥ 64(R)	≥ 64(R)	≥ 32(I)	≥ 64(R)
Ceftazidime	≥ 32(R)	≥ 64(R)	≥ 64(R)	≥ 64(R)
Ciprofloxacin	≥ 4(R)	≥ 4(R)	≥ 4(R)	0.5 (S)
Levofloxacin	≥ 4(I)	≥ 8(R)	≥ 8(R)	0.5 (S)
Imipenem	≥ 16(R)	≥ 16(R)	≥ 16(R)	≥ 16(R)
Meropenam	≥ 16(R)	≥ 16(R)	≥ 16(R)	≥ 16(R)
Piperacillin	≥ 128(R)	≥ 64(I)	≥ 128(R)	≥ 128(R)
Piperacillin/Tazobactam	≥ 128(R)	≤ 16(S)	≥ 128(R)	≥ 128(R)
Ticarcillin/Clavulanic acid	≥ 128(R)	≥ 128(R)	≤ 16(S)	≥ 128(R)
Trimethoprim/Sulphamethoxazole	≥ 320(R)	≥ 160(R)	≥ 160(R)	≤ 2(S)

tazobactam. The antibiotic was changed to piperacillin-tazobactam based on the susceptibility report. On the 19th day of ICU stay, the patient again had an episode of fever, hypotension and also sustained a cardiac arrest. The patient was started on multiple inotropes, but could not be revived.

2.3. Case 3

A 76 year old female had a history of fall following which she sustained injury to the left hip. She was admitted to our emergency department. Local examination revealed pain, swelling and deformity of the left thigh. X-ray revealed sub trochanteric fracture of left femur. The patient was a known case of hypertension and Type 2 diabetes mellitus and had deranged kidney and cardiac parameters and was investigated for surgical clearance. Following surgical clearance the patient was operated on and owing to high risk and underlying illness, she was shifted to the ICU. On the 5th postoperative day, she developed high grade fever and the blood cultures grew *Escherichia coli* sensitive to tigecycline and colistin. The patient was started on the above antibiotics as per the culture report. Despite these antibiotics the patient continued to have fever and the blood cultures sent on the 15th day of ICU stay grew *Enterococcus faecium* sensitive to ampicillin-sulbactam, vancomycin, teicoplanin and linezolid. The patient was started on linezolid 600 mg IV BD. The patient still persisted to have fever on and off. The blood cultures sent on the 31st day of hospitalisation grew *E. meningoseptica* sensitive to cefepime-tazobactam, cefoperazone-sulbactam, piperacillin-tazobactam and ticarcillin-clavulanate. The patient was started on cefepime-tazobactam. Despite all the efforts the patient succumbed to death on the 47th day of ICU stay.

2.4. Case 4

A 16 year old male was admitted with a history of RTA following which he presented with loss of

consciousness and vomiting. He was suspected to have head injury. The CT scan revealed left temporal and occipital contusion with mass effect and midline shift. The patient was started on augmentin 1.2 mg IV stat. An emergency decompressive craniectomy was done and he was shifted to the ICU. Post operatively, the patient was started on injection cefoperazone-sulbactam 1 gm IV BD and injection netilmicin 200 mg IV OD and was kept under observation in the ICU. On the 5th postoperative day the patient developed fever along with chest infiltrates, following which endotracheal aspirate (ETA) sample was sent to the lab. The ETA grew *Pseudomonas aeruginosa* which was sensitive only to colistin. The patient was then started on IV colistin. The patient still continued to have fever with increasing TLC counts. Multiple blood culture samples were sent. The blood sample sent on the 9th day of ICU stay grew *Elizabethkingia meningoseptica* sensitive to ciprofloxacin, levofloxacin and trimethoprim/sulphamethoxazole. The MIC values of the antibiotics are shown in Table 1. Prompt treatment with ciprofloxacin led to improvement of the patient.

3. Results and Discussion

Four cases of *E. meningoseptica* infections were reported in our ICU from June 2016 - May 2018. All four patients blood samples grew *E. meningoseptica*. The colony morphology of *E. meningoseptica* was smooth circular 1-2 mm colonies with entire edges and regular margins with a slight yellow pigmentation on nutrient agar after 24 hours incubation. The growth on blood agar showed 1-2 mm smooth, circular, greyish-white non-hemolytic colonies. There was no growth on MacConkey agar. All isolates grew at a temperature of 37°C.

Among the four patients, three patients were immunocompetent, one was immunocompromised with underlying illness. The mean age of the patients was 43.7 years. Two were males and two were females. The median time from admission to isolation of *E. meningoseptica* was 12 days range (10-25 days). Two of them had long bone fracture, one had multiple rib

Tables 2. Summary of patients with *Elizabethkingia meningoseptica* infections

Case	Age	Sex	Diagnosis	Underlying illness	Length of stay	Previous antibiotic exposure	Antibiotic treatment	Outcome
1	53	M	Hemopneumothorax with septic shock	Nil	42	Meropenam, Tigecycline Colistin,	Levofloxacin	Death
2	30	F	Intertrochanteric fracture femur with septic shock	Nil	55	Cefepazone sulbactam, Levofloxacin, Meropenam Colistin,	Piperazillin/Tazobactam	Death
3	76	F	Subtrochanteric fracture femur with sepsis	HT, Type 2 DM	63	Colistin	Cefepime-tazobactam	Death
4	16	M	Head Injury with sepsis	Nil	15	Cefepazone-sulbactam, Netilmicin	Ciprofloxacin	Survived

fractures with hemopneumothorax, and one had head injury with acute Extra Dural Haematoma (EDH). Among the four, two of them underwent surgical procedures for long bone fracture and one underwent surgical evacuation of EDH. All four patients had history of a recent hospitalization. At the time of bacteremia, all four patients were in the ICU and required mechanical ventilation. All four patients had a central line at the time of bacteremia. All the patients received combination therapy with two or more antibiotics, which included ceftazidime-sulbactam, meropenem, tigecycline and colistin. Of the four patients, three died and one recovered. The clinical features and risk factors of all the patients are summarized in Table 2. Antimicrobial susceptibility of all the isolates was performed and the minimum inhibitory concentration (MICs) of the isolates are shown in Table 1. All four isolates were resistant to most of the antibiotics commonly use in the ICUs. Among the four only one isolate tested was susceptible to trimethoprim-sulfamethoxazole, ciprofloxacin, and levofloxacin.

E. meningoseptica is capable of survival in hospital environments. The source of the organism is most likely from contaminated water supply (since it survives chlorine treatment) or from hospital equipment and other sources such as saline solutions used for flushing procedures, disinfectants, hands of hospital staffs, infant formulas etc. (5). The risk factors for infection by this organism includes diabetes mellitus, steroid use, malignancies, organ transplantation, neutropenia, prolonged hospitalisation, prior exposure to multiple antibiotics, immunocompromised host and chronic haemodialysis (6). In our study, we observed that prolonged hospital stay especially in the ICUs, presence of central venous catheter (CVC), exposure to various broad spectrum antibiotics, presence of shock and recent surgery were the major risk factors. A similar study conducted in Taiwan showed that 60% of the infection were acquired in the ICUs (7). In our study too, all four patients were in the ICUs with CVC in place at the time of development of bacteraemia. One of the patients had diabetes mellitus as an underlying risk factor.

Elizabethkingia spp are known to be intrinsically resistant to tigecycline and polymyxins due to the production of both class A extended spectrum beta lactamases (ESBL) and class B metallo- β -lactamases (MBLs). The MBLs confer resistance to aztreonam and carbapenems, the latter being the mainstay drugs for the treatment of multidrug-resistant Gram negative bacteria (8). A study conducted by Khan *et al.* has shown that previous exposure to Gram negative antibiotic cover is known to predispose to hospital infections caused by *Elizabethkingia spp.* (9). Our study also showed similar findings where all four patients had received prolonged gram negative antimicrobial cover in the ICUs.

Infections caused by *Elizabethkingia spp.* are very difficult to treat and have a high mortality rate especially in immunocompromised patients. A study conducted by Boroda K *et al.* reported a 28 day mortality rate of 41% for nosocomial infections and 9.1% for community acquired infections (10).

We also observed a high mortality, where three out of four cases had a fatal outcome. Presence of shock and use of inappropriate antibiotics acted as independent risk factors for mortality as seen in the other studies (11). Delay in the identification of the organism may lead to treatment failure. Different AST methods gives varied susceptibility results, further complicating its management. The disc diffusion methods are considered to be unreliable and broth micro dilution is the preferred method. There are no standard guidelines for empiric treatment of *E. meningoseptica* infection and most authors suggest using antimicrobial agents based on the minimal inhibitory concentration results from properly performed susceptibility tests (12).

To conclude, *Elizabethkingia meningoseptica* is an emerging pathogen in trauma victims who undergo various surgical procedures. It is essential to keep a high index of suspicion for this infection since failure to start the appropriate antibiotic therapy may lead to a fatal outcome. In the hospital setting, strict contact isolation should be implemented to prevent colonisation of individuals and outbreak.

Acknowledgements

I wish to acknowledge my laboratory staff and technicians for helping in laboratory testing and identification of isolates.

References

1. Shinha T, Ahuja R. Bacteremia due to *Elizabethkingia meningoseptica*. IDCases. 2015; 2:13-15.
2. Han MS, Kim H, Lee Y, Kim M, Ku NS, Choi JY, Yong D, Jeong SH, Lee K, Chong Y. Relative prevalence and antimicrobial susceptibility of clinical isolates of *Elizabethkingia* species based on 16S rRNA gene sequencing. J Clin Microbiol. 2016; 55:274-280.
3. Tak V, Mathur P, Varghese P, Misra MC. *Elizabethkingia meningoseptica*: An emerging pathogen causing meningitis in a hospitalized adult trauma patient. Indian J Med Microbiol. 2013; 31:293-295.
4. Jung SH, Lee B, Mirrakhimov AE, Hussain N. Septic shock caused by *Elizabethkingia meningoseptica*: A case report and review of literature. BMJ Case Rep. 2013; 2013. pii:bcr2013009066.
5. Rastogi N, Mathur P, Bindra A, Goyal K, Sokhal N, Kumar S, Sagar S, Aggarwal R, Soni KD, Tandon V. Infections due to *Elizabethkingia meningoseptica* in critically injured trauma patients: A seven-year study. J Hosp Infect. 2016; 92:30-32.
6. Ceyhan M, Yildirim I, Tekeli A, Yurdakok M, Us E, Altun B, Kutluk T, Cengiz AB, Gurbuz V, Barin C, Bagdat A, Cetinkaya D, Gur D, Tuncel O. A

- Chryseobacterium meningosepticum outbreak observed in 3 clusters involving both neonatal and non-neonatal pediatric patients. *Am J Infect Control*. 2008; 36:453-457.
7. Lin YT, Chiu CH, Chan YJ, Lin ML, Yu KW, Wang FD, Liu CY. Clinical and microbiological analysis of *Elizabethkingia meningoseptica* bacteremia in adult patients in Taiwan. *Scand J Infect Dis*. 2009; 41:628-634.
 8. Ceyhan M, Celik M. Elizabethkingia meningosepticum (Chryseobacterium meningosepticum) infections in Children. *Int J Pediatr*. 2011; 215237.
 9. Khan ID, Lall M, Sen S, Ninawe SM, Chandola P. Multiresistant *Elizabethkingia meningoseptica* infections in tertiary care. *Med J Armed Forces India*. 2015; 71:282-286.
 10. Boroda K, Li L. Elizabethkingia meningosepticum in a patient with six-year bilateral perma-catheters. *Case Rep Infect Dis*. 2014; 985306.
 11. Swain B, Rout S, Otta S, Rakshit A. *Elizabethkingia meningoseptica*: An unusual cause for septicaemia. *JMM Case Rep*. 2015; doi:10.1099/jmmcr.0.000005
 12. Bennett JE, Dolin R, Blaser MJ. Mandell, Douglas, and Bennett's Principles and Practice of Infectious Diseases 8th Edition. Elsevier Health Sciences; 2014; pp 293.

(Received July 27, 2018; Revised August 16, 2018; Accepted August 19, 2018)

Underlying etiology determines the outcome in atraumatic chylous ascites

Harshal S Mandavdhare^{1,*}, Vishal Sharma¹, Harjeet Singh², Usha Dutta¹

¹Department of Gastroenterology, Postgraduate Institute of Medical Education and Research, Chandigarh, India;

²Department of Surgery, Postgraduate Institute of Medical Education and Research, Chandigarh, India.

Summary

Chylous ascites is an uncommon entity and infectious etiology is the most common cause in developing countries. However, recently, whether there is any change in trend of etiologies in developing countries is not known. In this study, a retrospective analysis of the data of cases of atraumatic chylous ascites was conducted. Twelve patients of atraumatic chylous ascites with a mean age of 35 years were studied and 6 of them were males. The mean duration of symptoms was 9.6 months and the clinical presentation was abdominal distension (12 cases), pain abdomen (10 cases), loss of appetite and weight (9 cases), peripheral lymphadenopathy (4 cases) and fever (3 cases). Etiologies were tuberculosis (3 cases), malignancy (2 cases), radiotherapy related (2 cases), pancreatitis related (2 cases), lymphatic malformation (2 cases) and multifactorial (1 case). Eight improved with conservative measures, 2 were lost to follow up and 2 died. Our outcomes found infectious etiology still as the most common cause of atraumatic chylous ascites. Benign treatable causes could be managed successfully with conservative measures while malignant etiology had a poor prognosis. Underlying etiology determines the outcome in atraumatic chylous ascites.

Keywords: Ascites, chylous, tuberculosis, lymphatic malformation, lymphoscintigraphy

1. Introduction

Chylous ascites, an uncommon entity, is characterized by presence of milky peritoneal fluid abundant in triglycerides, nutrients and immunoglobulins resulting from congenital or acquired abnormalities of abdominal lymphatics. Although various etiologies have been described that result in this clinical entity, v.i.z, malignancy, infection, abdominal surgery, trauma, cirrhosis among others, the condition is uncommon and chylous ascites accounts for a very small number of overall ascites cases and as per published literature the current incidence is 1 case per 20,000 admissions (1).

Traditionally it has been taught that the most common etiologies for atraumatic chylous ascites in developed

countries are malignancy and cirrhosis and that in developing countries it is due to infectious etiologies like tuberculosis and filariasis (1). The data for atraumatic chylous ascites is scant as can be seen from a systematic review, which reported that only 21% of the studies in their literature search reported on atraumatic chylous ascites (2). Also the data of atraumatic chylous ascites from India is scarce and we do not know whether the trend of etiologies remains the same or has changed in developing countries like India.

Here, we report our experience with patients who presented with atraumatic chylous ascites from North India and report about underlying causes, clinical presentation and outcomes in these patients.

2. Patients and Methods

This is a retrospective analysis of our prospectively maintained database of patients who presented with chylous ascites over a period of 3 years from 2014 to 2017. We evaluated clinical presentation, etiologies, treatment modalities used and the outcome. The diagnosis was suspected in patients who had milky

Released online in J-STAGE as advance publication August 15, 2018.

*Address correspondence to:

Dr. Harshal S Mandavdhare, Department of Gastroenterology, Postgraduate Institute of Medical Education and Research, Chandigarh160012, India.

E-mail: hmandavdhare760@gmail.com

hue of the fluid and this was tested for triglyceride level. The cut off triglyceride value to label the case as chylous ascites was taken > 110 mg/dL. We present our experience of these patients who had chylous ascites.

3. Results and Discussion

3.1. Clinical presentation

Over a period of 3 years, 12 patients who presented with chylous ascites were seen (Table 1). The mean age was 35 years (range 15-72) and 6 (50%) were males. The mean duration of symptoms was 9.6 months (range 0.5-84 months). The presenting complaints in decreasing order were abdominal distension in 12 cases (100%), pain abdomen in 10 cases (83.3%), loss of weight and appetite in 9 cases (75%), peripheral lymphadenopathy in 4 cases (33.3%) and fever in 3 cases (25%) patients. The mean triglyceride value was 507 mg/dL (range 130-1,600 mg/dL).

3.2. Etiologies

3.2.1. Tuberculosis

Three patients had tuberculosis as the etiology of chylous ascites. All 3 were young females aged between 25-26 years and presented with 2-6 months history of abdominal distension along with loss of appetite and weight and fever. While one of them, a 25-year-old, had history of genitourinary tract tuberculosis and was a defaulter and her ascitic fluid examination showed milky fluid with triglycerides of 1,600 mg/dL with low serum

ascites albumin gradient (SAAG) of 0.5 and high ADA of 45 IU/L. She had peripheral lymphadenopathy and the FNAC from retroperitoneal lymph nodes showed granulomatous inflammation with AFB stain positive and also was GenXpert positive for tuberculosis. She was started on standard 4 drug antitubercular therapy (ATT) along with octreotide and medial chain triglyceride (MCT) based diet and at 6 months of follow up she had gained weight and the ascites had disappeared.

Another 25-year-old female had a ascitic fluid triglyceride of 323 mg/dL with low SAAG of 0.3 and ADA of 18 IU/L. She too had peripheral lymphadenopathy, and chest x ray showed military shadows and abdominal CT scan showed gross ascites with omental nodularity with a sheet like lymph nodal mass encasing the inferior vena cava with calcification. The FNAC from this lymph nodal mass showed granulomatous inflammation with AFB stain positive. She was started on standard 4 drug ATT with MCT, however, subsequently she died of ATT induced liver failure.

The third patient a 25 year old female presented with above the complaints and ascitic fluid triglyceride was 400 mg/dL with low SAAG of 0.2 and high ADA of 74 IU/L. Her abdominal CT scan showed gross ascites with multiple mesenteric lymph nodes. She had cervical lymphadenopathy and its FNAC showed granulomatous inflammation and AFB stain was positive. She was started on standard 4 drug ATT with MCT based diet and after completion of 6 months of ATT and a further 5 months follow up is doing fine with disappearance of ascites and weight gain. All 3 patients were HIV negative.

Table 1. Summary of the cases of atraumatic chylous ascites

Characteristics	Summary
Age mean (range)	35 years (15-72)
Males	6 cases
Mean duration of symptoms	9.6 months (range 0.5-84)
Clinical presentation	Abdominal distension: 12 cases (100%) Pain abdomen: 10 cases (83.3%) Loss of weight and appetite: 9 cases (75%) Peripheral lymphadenopathy: 4 cases (33.3%) Fever: 3 cases (25%)
Mean triglyceride value	507 mg/dL (range 130-1600)
Etiologies	Tuberculosis: 3 cases Malignancy: 2 cases Radiotherapy related: 2 cases Pancreatitis related: 2 cases Lymphatic malformation (Milroy disease and primary intestinal lymphangiectasia): 2 cases Multifactorial: 1 case
Outcome	Improved with conservative measures: 8 Lost to follow up: 2 cases Died: 2 cases

3.2.2. Malignancy

Two patients had malignancy associated chylous ascites. A 72-year-old female with history of diabetes mellitus and coronary artery disease presented with a 1 ½ year history of loss of weight of around 25 kg and abdominal pain and distension for 2 weeks. The CECT abdomen showed a 1.2 × 1.3 cm hypodense lesion in the body of pancreas with multiple hypodense lesions in both lobes of liver with gross ascites. The ascitic fluid triglyceride was 130 mg/dL with high SAAG of 2.0, however, the malignant cytology was negative. The FNAC from the pancreatic lesion showed features of adenocarcinoma. She was discharged on MCT based diet and asked to follow under the department of radiotherapy, but was lost to follow up.

The second patient was a 16-year-old male who presented with 3 months history of abdominal distension, generalized weakness and weight loss of 10 kg. The ascitic fluid triglycerides were 241 mg/dL and ascitic fluid malignant cytology was positive. He also complained of nausea and postprandial vomiting. We did an esophagogastroduodenoscopy that revealed thickened gastric fold to the extent that the scope was not negotiable beyond the antrum (Figure 1). The histopathology from the stomach biopsy showed poorly differentiated signet ring cell carcinoma. We advised MCT based diet and explained the prognosis of this metastatic disease to the family after which they took discharge and were lost to follow up.

3.2.3. Radiation induced

Two patients developed radiation induced chylous ascites. A 40-year-old female who was a known case of carcinoma of the cervix had received chemo radiotherapy for the disease. After completion of her radiotherapy cycles she was asymptomatic for 4 months after which

she noticed gradually progressive abdominal distension over a period of 6 months. Her ultrasound abdomen showed gross ascites with fluid triglyceride of 600 mg/dL, however, the malignant cytology was three times negative. She was started on MCT based diet with octreotide and improved with it.

Another patient a 39-year-old male had unresectable carcinoma of the esophagus for which he received radiotherapy, however, later developed constrictive pericarditis and then presented with abdominal distension and had gross ascites with fluid triglyceride of 512 mg/dL. He was started on MCT based diet, but developed recurrence of the primary malignancy and later on succumbed to it.

3.2.4. Pancreatitis related

A 15-year-old male presented with abdominal pain for 3 months and distension for 1 month. His Serum amylase was 1,160 U/L and CT scan revealed dilated main pancreatic duct (MPD) with gross ascites. Ascitic fluid was milky with triglyceride of 281 mg/dL and amylase of 7,000 U/L. All etiologic work up for chronic pancreatic disease was negative so the case was labeled as idiopathic chronic pancreatitis with pancreatic chylous ascites and was started on MCT based diet and octreotide, however ascites persisted so the patient was taken up for ERCP which revealed hugely dilated, tortuous MPD with contrast extravasation at the head region of pancreas and a 5 F stent was placed across the disruption. Patient showed clinical improvement and 4 weeks later a repeat CT scan revealed disappearance of ascites with stent in situ.

Another patient a 35-year-old chronic alcoholic male presented with abdominal pain and distension over 15 days and CT scan revealed non-enhancing pancreas with gross ascites. The Fluid appeared milky with triglyceride of 220 mg/dL and amylase of 19,950 U/L. The patient

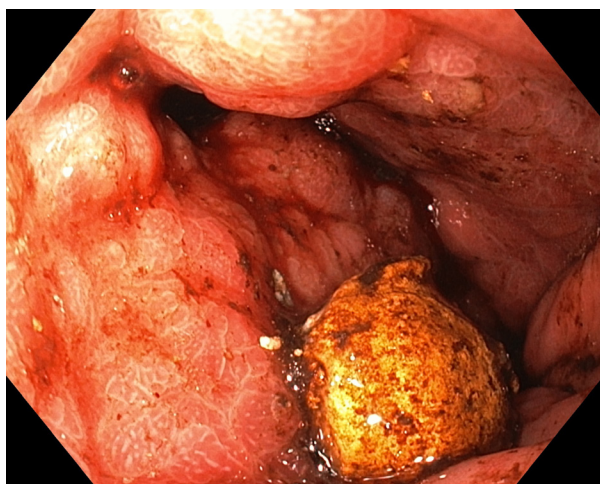


Figure 1 showing unhealthy edematous gastric folds with narrowing in the antral region with a food bolus.

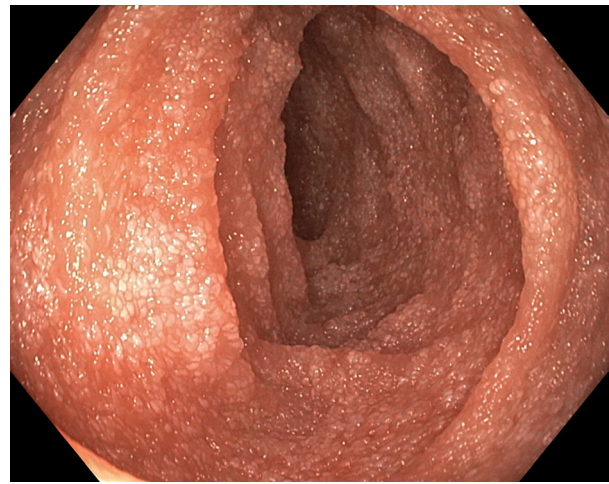


Figure 2 showing granular edematous mucosal surface of duodenum with scattered whitish specs throughout the duodenum.

was febrile with total leucocyte count of 23,600/dL so was started on antibiotics and pigtail drainage was done and was started on MCT based diet with octreotide and improved with the above measures.

3.2.5. Lymphatic malformation

A 34-year-old male with prolonged history of bipedal edema over 10 years presented with gradually progressive abdominal distension over 2 months. The fluid triglyceride was 206 mg/dL and MR lymphangiogram revealed lymphatic channels absent above the ankle suggestive of Milroy's disease. Patient was started on MCT based diet and improved gradually with disappearance of ascites in 2 months.

Another patient a 42-year-old male with history of diarrhea with malabsorption over 7 years presented with abdominal distension over 3 months. Ascitic fluid had low SAAG of 0.6 and triglyceride of 560 mg/dL and esophagogastroduodenoscopy revealed a granular edematous mucosal surface of duodenum with scattered whitish specs throughout the duodenum (Figure 2). The biopsy was suggestive of lymphangiectasia. Patient was started on MCT based diet and improved.

3.2.6. Multifactorial

A 51-year-old female with previous co morbidities in the form of hypertension and hypothyroidism presented with progressive abdominal distension over 2 months. Four years back she was diagnosed as a case of chronic pancreatitis and had developed a symptomatic large pseudocyst that required cystogastrostomy and also had extrahepatic cholestasis due to common bile duct stricture resulting from chronic pancreatitis and had undergone choledochojejunostomy. This time along with abdominal distension she had pedal edema, pallor with hemoglobin of 8.2 gm % and deranged renal function with creatinine of 6.2 mg/dL and 24-hour urine protein of 7 gm. Her ultrasound abdomen revealed a shrunken liver with irregular outline and raised echotexture and esophagogastroduodenoscopy revealed portal hypertensive gastropathy. Her ANA titer was 1:80 and SMA titer 1:40. All other work up for etiology of chronic liver disease was negative. Ascitic fluid showed low SAAG 0.2 with triglycerides of 1,010 mg/dL and the renal biopsy showed features suggestive of membranous lupus nephritis. The etiology of chylous ascites was thought to be multifactorial with contributions from cirrhosis and lupus and she was started on steroids with octreotide, MCT based diet and diuretics and improved dramatically with disappearance of ascites and improvement of renal function.

3.2.7. Discussion

Our series is a compilation of cases of atraumatic

chylous ascites seen in the medical gastroenterology unit from 2014 till 2017. In our series infection due to tuberculosis was the most common etiology suggesting that the trend still has not changed and the traditional teaching that malignancy and cirrhosis are the causes of atraumatic chylous ascites in developed and infection due to tuberculosis/filariasis in developing countries still remains the same (1). Our study highlights the fact that a benign treatable etiology for atraumatic chylous ascites has good prognosis with most recovering with conservative measures along with treatment of the underlying etiology, however, malignancy will have a poor prognosis as 1 of the 3 patients with malignancy died (one who had constrictive pericarditis due to radiotherapy ultimately died due to recurrence of the primary esophageal malignancy) and the other 2 patients who also had a disseminated malignancy were lost to follow up but the prognosis in such a situation is expected to be adverse. Two of our patients had lymphatic malformation (Milroy disease and primary intestinal lymphangiectasia) and both of them had resolution of the chylous ascites with conservative measures suggesting a good prognosis. In lymphatic malformations where conservative measures fail one can get a pre-operative lymphoscintigraphy which can show back flow and/or a lymphangiography that can clearly show dysplastic areas and sites of lymphatic leaks. Presence of localized abdominal dysplasia, lymphatic blocks, evidence of back flows, ectatic lymphatic vessels and tissue areas and lymphangiomatosis can be dealt with surgery. The lymphangiectasias and lymphangiomatosis are sclerosed with polidocanol and then are surgically debulked. The incompetent lymph vessels can be surgically ligated in a "stair like" manner. The ectatic vessels with low degree of dilatation can be welded with the help of a CO₂ laser. In presence of proper chylous and lymphatic vessels, Chylovenous or lymphovenous microsurgical shunts can be performed in iliac or mesenteric areas (3).

None of our patients required surgery as most of our patients had benign treatable causes and all resolved with conservative therapy. The role of surgery comes when we have refractory chylous ascites not responding to the conservative measure in the form of low fat, high protein, medium chain triglyceride based diet with or without somatostatin or octreotide and diuretics and in some cases total parenteral nutrition in which case a pre-operative or intra operative lymphangiogram helps to localize the leak and then a fistula closure or bowel resection can be done (4). Where intervention radiology facilities with expertise in lymphangiography and embolization are available the need for surgery can be circumvented with good results, however, sometimes the conventional lymphangiography may not pick up the leak in such cases an MR lymphangiogram and recently balloon occluded retrograde abdominal lymphangiography and embolization have been found useful (5,6). The peritoneovenous shunt has been

abandoned due to high rate of shunt block with repeated replacement and also serious complications (7).

To conclude infective causes still lead the list of etiology of atraumatic chylous ascites in developing countries like India. A benign treatable cause in a majority of cases recovers with conservative measures with dietary modification with or without octreotide/somatostatin and diuretics and treating the underlying cause while malignancy portends a poor prognosis.

References

1. Lizaola B, Bonder A, Trivedi HD, Tapper EB, Cardenas A. Review article: The diagnostic approach and current management of chylous ascites. *Aliment Pharmacol Ther.* 2017; 46:816-824.
2. Steinemann DC, Dindo D, Clavien PA, Nocito A. A traumatic chylous ascites: Systematic review on symptoms and causes. *J Am Coll Surg.* 2011; 212:899-905.e1-4.
3. Campisi C, Bellini C, Eretta C, Zilli A, da Rin E, Davini D, Bonioli E, Boccardo F. Diagnosis and management of primary chylous ascites. *J Vasc Surg.* 2006; 43:1244-1248.
4. Al-Busafi SA, Ghali P, Deschênes M, Wong P. Chylous ascites: Evaluation and management. *ISRN Hepatol.* 2014; 2014:240473.
5. Nadolski GJ, Chauhan NR, Itkin M. Lymphangiography and lymphatic embolization for the treatment of refractory chylous ascites. *Cardiovasc Intervent Radiol.* 2018; 41:415-423.
6. Srinivasa RN, Gemmete JJ, Osher ML, Hage AN, Chick JFB. Endolymphatic balloon-occluded retrograde abdominal lymphangiography (BORAL) and embolization (BORALE) for the diagnosis and treatment of chylous ascites: Approach, technical success, and clinical outcomes. *Ann Vasc Surg.* 2018; 49:49-56.
7. Aalami OO, Allen DB, Organ CH Jr. Chylous ascites: A collective review. *Surgery.* 2000; 128:761-778.

(Received March 27, 2018; Revised May 29, 2018; Accepted June 21, 2018)

Is it always cancer? A curious case of benign intracranial hypertension in chronic myeloid leukemia

Purva V. Sharma^{1,*}, Omar Ilyas¹, Yash Jobanputra¹, Teresita Casanova², Venkat Kalidindi¹, Napolean Santos³

¹Department of Internal Medicine, University of Miami Palm Beach Regional Consortium, Atlantis, FL, USA;

²Department of Neurology, JFK Medical Center, Atlantis, FL, USA;

³Department of Hematology/Oncology, JFK medical Center, FL, USA.

Summary

28-year-old African American female with chronic myeloid leukemia (CML) presented with blurry vision for 4-5 days prior to presentation associated with right-sided headaches. Patient was on treatment for the CML but never had hematological remission. Patient saw an ophthalmologist who told her that she has bilateral optic disc swelling and advised her to get an MRI of the brain. She came to the ER due to worsening headache and blurry vision. The funduscopic examination showed significant bilateral papilledema. Laboratory evaluation revealed a leukocytosis of $240 \times 10^3/\mu\text{L}$ with platelet count of $1,202 \times 10^3$. The white cell differential count showed 17% blasts along with myelocytes and meta-myelocytes. MRI of brain revealed non-specific CSF flair signal. Lumbar puncture (LP) showed significantly elevated opening pressures. The CSF composition was however normal. The patient felt much relief of her symptoms following the LP. The papilledema was thought to be due to benign intracranial hypertension (ICH), which was attributed to poor CSF absorption due to resistance to flow of CSF caused by the high WBC count. She received 2 cycles of leukopheresis which dropped her WBC count. She was also started on acetazolamide for the benign ICH and her symptoms improved considerably. Patients with CML can thus present with symptoms mimicking CNS involvement of the disease such as headaches and blurry vision, but that could be attributed to the poor CSF resorption given the leukocytosis rather than spread of the disease itself.

Keywords: Intracranial hypertension, chronic myeloid leukemia, papilledema

1. Introduction

Chronic myeloid leukemia (CML) is a myeloproliferative disorder characterized by overproduction of myeloid cells. CML accounts for approximately 15 to 20 percent of leukemias in adults (1). The median age at presentation is 50 years of age. It commonly presents in 3 different clinical courses – chronic phase, accelerated phase and blast crisis. CML in blast crisis has been

shown to have a propensity for CNS involvement (2). This can cause seeding of the leukemic cells in the CNS especially with high WBC counts at presentation (3).

We present an interesting case of a young African American lady with CML who presented with blurry vision and headaches. She was found to have bilateral optic disc edema secondary to increased intracranial pressure.

2. Case Report

28-year-old African American female with history of CML presented to JFK Medical Center in November 2017 with symptoms of blurred vision for 4-5 days prior to presentation. Patient states the blurry vision started insidiously and is worse in the right eye. It gets worse with movement of her head. The blurry

Released online in J-STAGE as advance publication July 27, 2018.

*Address correspondence to:

Dr. Purva V. Sharma, Department of Internal Medicine, University of Miami Palm Beach Regional Consortium, Atlantis, FL 33462, USA.

E-mail: purva7sharma@gmail.com

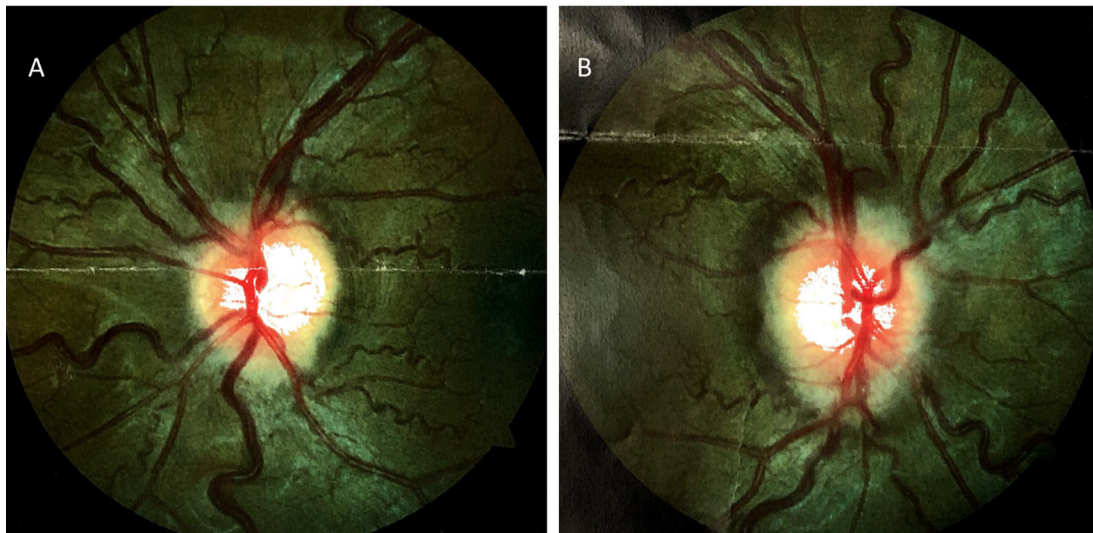


Figure 1 showing left (A) and right (B) optic disc edema visualized on the fundoscopic examination.

vision is associated with right sided headaches in the frontal, temporal and occipital region which have also been ongoing for 3-4 days prior to presentation. The headaches were described as continuous, sharp and relieved by OTC analgesics. The patient saw an ophthalmologist 2 days prior to presentation due to the blurry vision. She was told to get an MRI as there was bilateral optic disc edema visualized on the fundoscopic examination (Figure 1). Patient, however, was not able to have the MRI done until the time of presentation.

The patient was diagnosed with CML in chronic phase back in 2014. Since then she has received multiple lines of therapy including Imatinib, Dasatinib and Nilotinib. However, she never reached a durable hematologic remission. More recently she was started on Bosutinib.

At the time of arrival, patient was in mild to moderate distress due to the headaches. She was afebrile, with HR 92 and regular, BP- 138/68 mmHg and saturating well at 98% on room air. The physical examination was consistent with bilateral papilledema. Her head and neck examination was within normal limits, visual fields and remainder of neurologic exam was intact.

Her laboratory evaluation revealed white cell count of 240×10^3 . The differential count showed 7% myelocytes, 12% meta-myelocytes and 17% blast cells. Her Hb was 8.7 g/dL and platelet count was $1,202 \times 10^3$. MRI of the brain showed non-specific abnormal specific CSF flair which was questionable for early signs of meningitis. This was followed by a lumbar puncture which showed clear, colorless fluid with 0 white cells and 0 red blood cells. The CSF analysis also showed normal protein and glucose. The lumbar puncture was remarkably significant for an elevated opening pressure of 65 cm H₂O. The patient felt much improvement of symptoms of headache and blurry vision after the lumbar puncture. MRA did not show any abnormality in the flow rate of

venous filling of the dural sinuses. MRI did not show enlarged ventricles and the patient had no clinical signs or symptoms of meningitis which was suspected on the imaging. After multidisciplinary discussion between Neurology, Oncology and the primary team, the decision was made to start Acetazolamide to treat for elevated intracranial hypertension. Leukopheresis was initiated as well to reduce the white cell count. She received 2 cycles of leukopheresis and her white cell count steadily dropped to 27×10^3 . Her symptoms of blurred vision and headaches also considerably improved. Patient was discharged on acetazolamide and Bosutinib. One month later she had a follow-up with Neurology and Oncology and no recurrence of her symptoms at that time.

3. Discussion

CML is a myeloproliferative neoplasm characterized by the uncontrolled proliferation of mature and maturing granulocytes. CML is associated with the fusion of two genes: BCR (on chromosome 22) and ABL1 (on chromosome 9) resulting in the BCR-ABL1 fusion gene. This abnormal fusion typically results from a reciprocal translocation between chromosomes 9 and 22, t (9;22) (q34; q11), that gives rise to an abnormal chromosome 22 called the Philadelphia (Ph) chromosome. If untreated, CML can progress from a chronic phase to an accelerated phase and then a blast crisis.

Blast phase of CML is defined by more than 20% blasts in the blood/bone marrow or 5-10% blasts in the extramedullary sites (3). Lymph nodes, skin and soft tissues, bone, gastrointestinal and genitourinary tract are the most common sites of extramedullary blast crises. CNS involvement by extramedullary crises is rare and involves systemic involvement.(3,4) Also, CNS involvement is commonly seen in patients who are

treated with Imatinib for several months. This is because the drug is shown to have poor penetration into the CNS and allows leukemic infiltration (4).

However, in CNS leukemia the CSF will show evidence of increased WBC count as well as blasts which is not the case in our patient. The MRI of our patient did show some non-specific CSF flair but the CSF had 0 WBC count, which makes CNS infiltration by the leukemia very unlikely. The most significant physical examination finding in our patient was the bilateral optic disc edema seen on funduscopic evaluation.

Optic disc swelling in leukemia may be due to either direct leukemic infiltration of the optic nerve or papilledema secondary to raised intracranial pressure (ICP). Direct leukemic infiltration however is more common in acute leukemias and the presentation is usually asymmetric or unilateral (5,6). The appearance of the disc is also very different in direct infiltration as compared to papilledema. The disc is more opaque and asymmetrically placed. Also, reducing the ICP should reduce the papilledema, but will not affect the disc appearance in direct leukemic infiltration. In our patient, the optic discs were bilaterally edematous and symmetrically enlarged. This also makes direct involvement of the CML through infiltration of the optic nerve very less likely.

Although it is possible to have CNS leukemia without detection of leukemic cells in the CSF fluid, it is extremely unlikely that our patient's presentation was as a result of that. We believe that the bilateral optic disc swelling was secondary to papilledema. This is consistent with the initial CSF opening pressure of 65 cm H₂O with subsequent clinical course of reduction in papilledema with the reduction in ICP. The mechanism of raised ICP is most likely from obstruction to CSF outflow (7). The obstruction to CSF flow could be seen as a result of direct meningeal infiltration in CNS leukemia, with cells proliferating in the arachnoid space. However, the patient had no signs of a CNS leukemia on MRI or lumbar puncture. A patient with raised ICP and normal CSF composition and neuro-imaging, by definition, has benign intracranial hypertension. Thrombosis of the dural venous sinuses could result in raised ICP, however our patient's MRA showed no signs of thrombosis (8).

We therefore postulate that the increase in ICP was due to poor absorption of CSF into the patent sinuses. This is due to increased resistance to outflow secondary to the very high WBC count (9). Børgesen *et al.* have shown that there is a linear relationship between resistance to CSF outflow and ICP (10). Increased white count causes increased viscosity which in turn can lead to an increased resistance to flow of CSF from the arachnoid villi into the sinuses. The rapid resolution of papilledema with reduction of ICP after lumbar puncture

also favors this hypothesis.

Additionally, the patient benefited from leukopheresis and her WBC count dropped considerably after two rounds of treatment. Leukopheresis is known to be an effective treatment modality, especially in cases of hyperviscosity syndrome in patients with CML and is able to achieve rapid cyto-reduction (11).

4. Conclusion

Papilledema in a patient with leukemia with normal CSF and neuro-imaging is most likely due to benign intracranial hypertension. The most likely pathogenesis of the elevated ICP in such cases is that the elevated white cell count in leukemia causes hyperviscosity which decreases the absorption of CSF from the arachnoid villi. This results in increased intracranial pressures. It is significantly improved after reducing the ICP by lumbar puncture.

References

1. Siegel RL, Miller KD, Jemal A. Cancer Statistics, 2017. *CA Cancer J Clin.* 2017; 67:7-30.
2. Kim HJ, Jung CW, Kim K, Ahn JS, Kim WS, Park K, Ko YH, Kang WK, Park K. Isolated blast crisis in CNS in a patient with chronic myelogenous leukemia maintaining major cytogenetic response after imatinib. *J Clin Oncol.* 2006; 24:4028-4029.
3. Altintas A, Cil T, Kilinc I, Kaplan MA, Ayyildiz O. Central nervous system blastic crisis in chronic myeloid leukemia on imatinib mesylate therapy: A case report. *J Neurooncol.* 2007; 84:103-105.
4. Rajappa S, Uppin SG, Raghunadharao D, Rao IS, Surath A. Isolated central nervous system blast crisis in chronic myeloid leukemia. *Hematol Oncol.* 2004; 22:179-181.
5. Allen RA, Straatsma BR. Ocular involvement in leukemia and allied disorders. *Arch Ophthalmol.* 1961; 66:490-508.
6. Chalfin AI, Nash BM, Goldstein JH. Optic nerve head involvement in lymphocytic leukemia. *J Pediatr Ophthalmol Strabismus.* 1973; 10:39-43.
7. Ellis W, Little HL. Leukemic infiltration of the optic nerve head. *Am J Ophthalmol.* 1973; 75:867-871.
8. Foley J. Benign forms of intracranial hypertension; toxic and otitic hydrocephalus. *Brain.* 1955; 78:1-41.
9. Guymer RH, Cairns JD, O'Day J. Benign intracranial hypertension in chronic myeloid leukemia. *Aust N Z J Ophthalmol.* 1993; 21:181-185.
10. Børgesen SE, Gjerris F. Relationships between intracranial pressure, ventricular size, and resistance to CSF outflow. *J Neurosurg.* 1987; 67:535-539.
11. Shafique S, Bona R, Kaplan AA. A case report of therapeutic leukapheresis in an adult with chronic myelogenous leukemia presenting with hyperleukocytosis and leukostasis. *Ther Apher Dial.* 2007; 11:146-149.

(Received May 2, 2018; Revised July 4, 2018; Accepted July 10, 2018)

Traumatic neuroma as a rare cause of intractable neuropathic breast pain following cancer surgery: Management and review of the literature

Nikolaos S. Salemis*

Breast Unit, 2nd Department of Surgery, Army General Hospital, Athens, Greece.

Summary

Traumatic neuroma of the breast after cancer surgery is a very rare clinical entity with only a few cases having been reported to date. We herein present a very rare case of traumatic breast neuroma in a postmenopausal patient with a history of breast-conserving surgery, who presented with a four-month history of intractable neuropathic breast pain. Diagnostic evaluation and management are discussed along with a review of the literature. Traumatic breast neuromas are very rare benign lesions that have been reported mainly after mastectomy. Our literature review yielded only 35 cases of traumatic breast neuromas in 28 patients, reported so far. Although imaging features may be indicative of a benign lesion, surgical excision is necessary to obtain a definitive diagnosis and to rule out a recurrent breast cancer. Conservative treatment is feasible in properly selected cases with asymptomatic neuromas after an accurate tissue sampling. The case presented herein underlines the necessity to consider traumatic neuroma in the differential diagnosis in patients with a history of breast surgery presenting with refractory neuropathic breast pain. A high index of suspicion is required because the lesion may be too small and can be missed on imaging investigations.

Keywords: Neuroma, breast, traumatic, neuropathic, pain

1. Introduction

Traumatic neuroma (TN) is a nonneoplastic reactive proliferation of the proximal end of a partially transected or severed nerve as a result of trauma or surgery (1,2). It is a disorganized tangled mass of axons, Schwann cells and perineural fibroblasts that is formed as a result of a failed attempt to reestablish axonal continuity following disruption of neuronal axons (3). Although TN is a well-established finding in patients who have undergone amputation (4), it, however, may occur in almost any anatomical site of the body and may resemble a peripheral nerve sheath tumor on imaging (5). Histologically, TN is characterized by a nonencapsulated,

disordered proliferation of small nerve fascicles, composed of axons, Schwann cells, endoneurial and perineurial cells, embedded in dense fibrous stroma (6,7). TN may produce severe refractory neuropathic pain, functional impairment, and psychological distress thus decreasing the quality of life (8,9). TN of the breast following cancer surgery is a very rare clinical entity with only a few cases reported in the literature so far. We herein present a very rare case of traumatic breast neuroma in a postmenopausal patient with a history of breast-conserving cancer surgery followed by radiotherapy, who presented with a four-month history of severe neuropathic refractory breast pain. Diagnostic evaluation and management are discussed along with a review of the literature.

2. Case Report

A 65-year old woman presented with a four-month history of left breast pain. She stated that the pain was severe and constant, with paroxysms of burning and electrical shock-like sensations, was exacerbated with

Released online in J-STAGE as advance publication August 15, 2018.

*Address correspondence to:

Dr. Nikolaos S. Salemis, Breast Unit, 2nd Department of Surgery, Army General Hospital, 19 Taxiarchon Street, 19014 Kapandriti, Athens, Greece.

E-mail: nikos.salemis@gmail.com

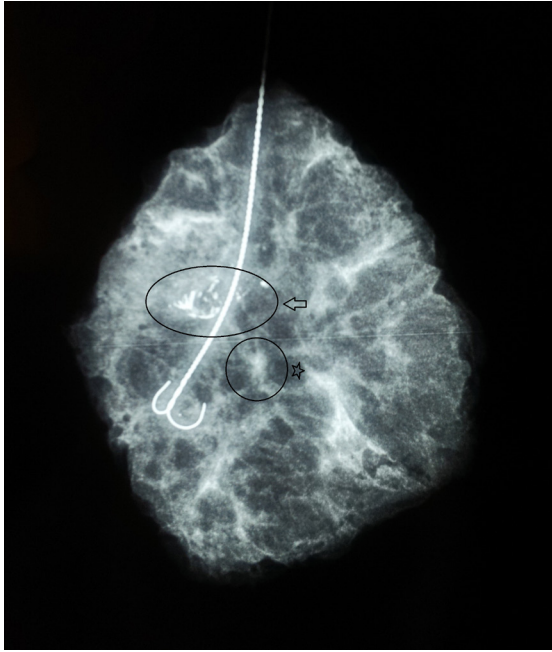


Figure 1. Specimen radiography showing clustered microcalcifications (arrow), along with a small area of architectural distortion (star).

pressure and was refractory to analgesics.

Her medical history was significant for a breast-conserving surgery, due to a ductal carcinoma in situ (DCIS) two years ago, followed by adjuvant radiation therapy and hormonal treatment with tamoxifen.

Clinical examination revealed severe left breast tenderness that was exacerbating with pressure over the area of the surgical scar. The mammogram revealed clustered microcalcifications in the area of the previously resected DCIS, along with a small area of architectural distortion. Ultrasonography was unremarkable.

In order to exclude the possibility of a recurrent DCIS a complete surgical excision of the mammographic lesions after wire localization was performed. Specimen radiography confirmed that the mammographic lesions were entirely removed (Figure 1). Immediately after surgery, the patient experienced complete pain relief.

The histopathological findings were consistent with fat necrosis and confluent microcalcifications. In addition, a small eosinophilic tumor measuring 0.2 cm was detected in the area of the architectural distortion. The tumor consisted of haphazardly arranged, eosinophilic cells with oval to spindle nuclei, without atypia, necrosis or mitosis. The periphery of the nodule was composed of perineural cells, while the inside consisted of proliferated Schwann cells (Figure 2). No evidence of malignancy was noted. The histological findings, in correlation with the clinical history and the complete relief of the breast pain immediately after surgery, indicated the diagnosis of traumatic breast neuroma.

The patient is completely asymptomatic, without

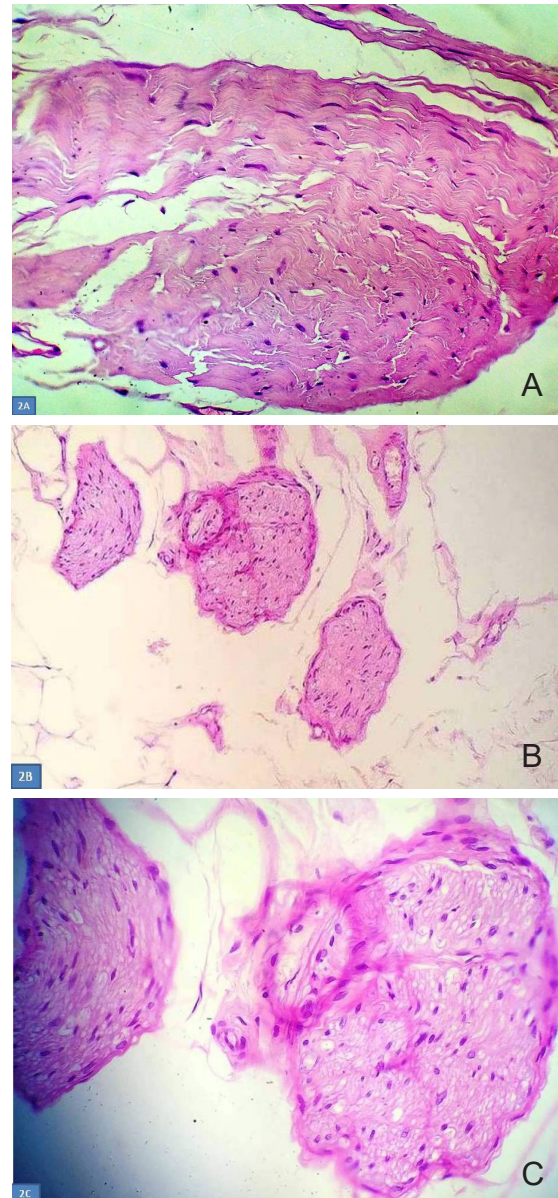


Figure 2. Histopathological findings of traumatic breast neuroma. (A) The tumor consists of haphazardly arranged, eosinophilic cells with oval to spindle nuclei, without atypia, necrosis or mitosis. (Hematoxylin and Eosin $\times 400$); **(B)** Tangles of small and medium, well circumscribed nerve fiber bundles, that do not invade the surrounding fibroadiposal tissue. (Hematoxylin and Eosin $\times 100$); **(C)** High power photomicrograph, of eosinophilic cells, with bubbly cytoplasm, bland, oval to spindle nuclei, without significant atypia. The periphery of the nodule is composed of perineural cells, while the inside consists of proliferated Schwann cells. (Hematoxylin and Eosin $\times 400$).

any suspicious mammographic findings four years after surgery.

3. Discussion

TN is not a true tumor but a reactive proliferation of nerve tissue of the proximal end of a severed nerve in an unsuccessful attempt to reestablish axonal continuity (7). TNs are divided into two major categories: spindle neuromas that are focal swellings caused by chronic

irritation to an injured but non severed nerve and terminal neuromas that have a bulbous-end morphology as a result of a partial disruption or total transection of the nerve as a result of surgery (5,7,10).

The exact pathogenesis of TN has not been clearly defined. Foltan *et al.* (11), suggested that the development of a TN may be divided into five phases and caused by simultaneous regeneration of nerve fibers and excessive fibrous tissue proliferation which results in contraction of nerve fibers within the scar tissue and the establishment of a chronic defensive proliferation process involving nerve fibers and scar fibrous tissue.

TN may develop 1-12 months after transection or injury secondary to a variety of surgical procedures such as radical neck dissections, abdominal surgery, limb amputations, orthognathic surgery, parotidectomy and tooth extractions (11). TN most commonly occurs in the lower extremities followed by head and neck, radial nerve and brachial plexus (7). In an early study by Tapas *et al.* (12), involving 67 cancer patients with TN the most frequently reported sites were radically dissected necks followed by upper and lower extremities.

TN typically presents as a firm, slowly growing painful or tender nodule not larger than 2 cm (3,11). Pain may be evoked by palpation or tapping over the lesion (Tinel sign) and may be associated with burning, stabbing or gnawing sensations (7,9).

Postoperative breast pain is a frequent issue reported in up to 60% of patients undergoing breast surgery (13-15) and may interfere with sexual activity, exercise, social activity and employment (13). Severe postoperative pain persists for 1 month and for 6-12 months in 25% and 10% of the breast surgery patients respectively (14).

Chronic post mastectomy pain is a chronic pain affecting the anterior chest wall, axilla and the upper half of the arm that begins after mastectomy or quadrantectomy and persists for more than three months after surgery (16). Although its exact pathogenesis is unclear, it is however believed, that an injury of the intercostobrachial nerve is the most common cause. The most common distribution of pain is the axilla and the arm (20-60%) followed by pain in the surgical scar (23-49%) (16). Pain can be experienced as a burning sensation or tenderness with paroxysms of lancinating shock-like pain, is exacerbated by pressure or movement and may be associated with discomfort or paresthesia (16). Neuromas trapped in the scar tissue may cause chronic neuropathic pain (15).

Jung *et al.* (8), classified chronic neuropathic pain following breast surgery into four categories: I phantom breast pain, II intercostobrachial neuralgia as a result of injury to the intercostobrachial nerve, associated with sensory changes in the distribution of the intercostobrachial nerve, III neuroma pain in the region of scar of the breast that is provoked or exacerbated by percussion, and IV other nerve injury pain secondary

to injury to medial or lateral pectoral, long thoracic or thoracodorsal nerves. Neuroma pain has been more frequently encountered following lumpectomy plus radiotherapy than mastectomy (8).

In a retrospective review of 57 patients with postsurgical chronic breast pain Ducic *et al.* (13), described five zones of nerve injury. The lateral zone was the most commonly injured area (79%) followed by inferior (10.5%), medial (5%), central (3.5%) and superior (2%) zones.

Traumatic neuroma of the breast (TBN) following cancer surgery is a very rare clinical entity (18,21). The first case was reported in 2000 (17). Our literature review yielded only 35 TBNs in 28 patients reported so far (1,2,4,6,10,14-24) (Table 1).

In a retrospective review Al Sharif *et al.* (6), reported a 0.09% incidence of TBN among 9,293 ultrasound-guided breast biopsies performed over a 10 year period. TBN can occur either after mastectomy or lumpectomy (8) and may develop 2-22 years after surgery (6).

Clinically TBN may present as a palpable mass or may be identified incidentally (1,6,10). It is most commonly encountered in the upper outer quadrant of the breast (6,10). Although in some cases the mass is painless (18,21), however, persistent chronic pain has been reported (19,24). In all six cases presented by Sung *et al.* (10), the TBN was located within the pectoralis major muscle near the mastectomy scar. TBN may be occult on mammogram (6,18).

On ultrasonography, TBN may appear as a homogenous well circumscribed hypoechoic mass with no internal vascular flow on color Doppler imaging (6,18,20,21). In some cases, however, TBN may appear as an irregularly shaped mass with indistinct margins and nonparallel orientation (10,23). A tail sign on ultrasonography has been reported in 50% of the cases reported by Al Sharif *et al.* (6). In the same study, 40% of the cases were occult on MRI evaluation. The most common MRI finding in the remaining cases was an isointense foci on T1 weighted images with a benign type I enhancement curve (2). On positron emission tomography (PET) computed tomography (CT) scan no fluorodeoxyglucose (FDG) focal uptake of TBN has been reported (10,20).

TBN should always be distinguished from recurrent breast cancer (21,23). Clinically, the location of TBN in the pectoral muscle layer may be helpful in the differential diagnosis, since a recurrent breast cancer is most commonly detected in the subcutaneous fat layer of the chest wall (10,20). The definitive diagnosis of TBN is, however, obtained by histopathological evaluation (1,4,18,21,23).

Treatment approaches for TBN include conservative management or surgery. The conservative approach, which has been reported to be successful in 50% of the cases, includes injection of a long-acting local anesthetic, corticosteroids, anti-inflammatory and antidepressant

Table 1. The clinical characteristics of reported cases with traumatic breast neuromas

Reference	Patients	Age	Neuromas (n)	Neuroma size (cm)	Time after surgery (months)	Palpable	Pain/Tenderness	Ultrasound features	Treatment
Rosso <i>et al.</i> (17), 2000	2	55, 67	2	0.4-0.6	22, 50	Yes	Yes	N/A	Surgical excision
Haj <i>et al.</i> (19), 2004	1	47	1	N/A	120	No	No	N/A	Stereotactic vacuum -assisted core needle biopsy
Baltalarli <i>et al.</i> (2), 2004	1	54	1	1	15	Yes	No	Well-circumscribed, homogeneous, hypoechoic	Surgical excision
Wang <i>et al.</i> (23), 2007	6	33-61	8	1	33-96	Yes	No	Well-circumscribed, homogeneous, Hypoechoic (4) Poorly defined hypoechoic (2)	Surgical excision
Kim <i>et al.</i> (20), 2011	1	47	1	1	168	No	No	Oval circumscribed hypoechoic	Surgical excision
Li <i>et al.</i> (21), 2012	1	43	1	0.5	24	Yes	N/A	Well-circumscribed, echo-heterogeneous	Surgical excision
Ashkar <i>et al.</i> (1) 2013	1	42	1	0.7	36	No	Yes	Well-defined, homogeneous, Hypoechoic	Ultrasound-guided core biopsy
Shin <i>et al.</i> (22), 2013	1	7	1	0.5	144	N/A	N/A	Oval circumscribed hypoechoic	Surgical excision
Zhu <i>et al.</i> (24), 2015	1	65	2	N/A	24	No	Yes	N/A	Surgical excision
Al Sharif <i>et al.</i> (6), 2016	6	48-71 mean:56	8	0.2-0.9 mean:0.46	24-264 mean:123	3/8 (38%)	1/8 (13%)	Hypoechoic with parallel orientation (7), Oval shape with circumscribed margins (1)	Ultrasound-guided core biopsy
Messinger <i>et al.</i> (4), 2017	1	74	2	0.6, 1.6	N/A	No	No	Parallel, oval, hypoechoic masses	Ultrasound-guided core biopsy
Fitzpatrick <i>et al.</i> (18), 2017	1	73	1	0.7	192	No	No	Hypoechoic, oval with parallel orientation and circumscribed margins	Ultrasound-guided core biopsy
Sung <i>et al.</i> (10), 2017	5	33-63 mean:44	6	0.39-0.55 Mean:0.48	23-133 mean:67	No	No	Oval shape with a circumscribed margin (4), Irregular shape and an indistinct margin (2)	Surgical excision
Salemis (present case), 2018	1	65	1	0.2	24	No	Yes	N/A	Surgical excision

medications, opioids, acupuncture, physical therapy and electrical stimulation (2,6,7,9,16,18,24).

An image-guided percutaneous biopsy is the standard of care for TBN (2,4,6,19). The procedure may be associated with severe pain despite generous local anesthesia (6). If a correct diagnosis is established, there is no need for further treatment, unless the TBN is painful (18). Sonographic surveillance is, however, indicated (2,6). Fine needle aspiration (FNA) cytology of TBN may be inconclusive (2,4,17).

Surgical treatment should be considered in cases not responding to conservative management presenting with chronic neuropathic pain (9,18,24). Surgical treatment includes resection of the neuroma, neurolysis, and implantation of the nerve stump into adjacent muscles (6,9) and can result in complete pain relief (24), as in our case.

Long-standing traumatic neuromas may undergo osseous metaplasia (19), or granular cell changes thus constituting a granular cell traumatic neuroma (17). The latter should be differentiated from malignant tumors such as apocrine carcinoma and alveolar soft part sarcoma. Kos *et al.* (3), reported a malignant peripheral nerve sheath tumor that arose within a long-standing traumatic neuroma.

In our case, similarly to the cases reported in the literature the neuroma was detected in the area of the surgical scar. The lesion was diagnosed 20 months after the primary surgery, while the reported cases have been reported to occur 24 months to 22 years after surgery. The size of the neuroma in our case was too small and was not detected on ultrasonography but was only seen as a small architectural distortion on mammography. Another different aspect in our case was the fact that the lesion was non palpable and provoked neuropathic breast pain refractory to analgesics, while in the literature most neuromas refer to palpable and painless nodules (18,21). In addition, a characteristic feature in our case was that our patient experienced complete relief of the breast pain immediately after surgery.

In conclusion, traumatic neuroma after breast cancer surgery is a very rare clinical entity with only a few cases reported in the literature so far. It should always be considered as a potential diagnosis in patients with a history of breast cancer surgery presenting with refractory neuropathic breast pain. Although the imaging features may be suggestive of a benign lesion, surgical excision is necessary to obtain a definitive diagnosis and to exclude a recurrent breast cancer. Conservative treatment is feasible in properly selected cases with asymptomatic neuromas after an accurate tissue sampling.

Acknowledgements

The author would like to thank Dr. Katikaridis I, and Dr. Sambaziotis D, from the Department of Pathology for providing the histology slides.

References

1. Ashkar L, Omeroglu A, Halwani F, Alsharif S, Loutfi A, Mesurolle B. Post-traumatic neuroma following breast surgery. *Breast J.* 2013; 19:671-672.
2. Baltalarli B, Demirkan N, Yağci B. Traumatic neuroma: Unusual benign lesion occurring in the mastectomy scar. *Clin Oncol (R Coll Radiol).* 2004; 16:503-504.
3. Kos Z, Robertson SJ, Purgina BM, Verma S, Gravel DH. Malignant peripheral nerve sheath tumor arising in a traumatic neuroma: A case report. *Hum Pathol.* 2013; 44:2360-2364.
4. Messinger JD, Crawford SM. Traumatic neuroma in axillary dissection scar bed following mastectomy. *Appl Radiol.* 2017; 46:38-39.
5. Ahlawat S, Belzberg AJ, Montgomery EA, Fayad LM. MRI features of peripheral traumatic neuromas. *Eur Radiol.* 2016; 26:1204-1212.
6. AlSharif S, Ferré R, Omeroglu A, El Khoury M, Mesurolle B. Imaging Features Associated With Posttraumatic Breast Neuromas. *AJR Am J Roentgenol.* 2016; 206:660-665.
7. Kransdorf MJ, Murphey MD. Neurogenic tumors. In: *Imaging of soft tissue tumors.* Kransdorf MJ, Murphey MD (eds). Philadelphia PA, Lippincott, Williams & Wilkins, 2006; pp:328-380.
8. Jung BF, Ahrendt GM, Oaklander AL, Dworkin RH. Neuropathic pain following breast cancer surgery: Proposed classification and research update. *Pain.* 2003; 104:1-13.
9. Yao C, Zhou X, Zhao B, Sun C, Poonit K, Yan H. Treatments of traumatic neuropathic pain: A systematic review. *Oncotarget.* 2017; 8:57670-57679.
10. Sung HS, Kim YS. Ultrasonographic features of traumatic neuromas in breast cancer patients after mastectomy. *Ultrasonography.* 2017; 36:33-38.
11. Foltán R, Klíma K, Spacková J, Sedý J. Mechanism of traumatic neuroma development. *Med Hypotheses.* 2008; 71:572-576.
12. Das Gupta TK, Brasfield RD. Amputation neuromas in cancer patients. *NY State J Med.* 1969; 2129-2132.
13. Ducic I, Seiboth LA, Iorio ML. Chronic postoperative breast pain: Danger zones for nerve injuries. *Plast Reconstr Surg.* 2011; 127:41-46.
14. Fecho K, Miller NR, Merritt SA, Klauber-Demore N, Hultman CS, Blau WS. Acute and persistent postoperative pain after breast surgery. *Pain Med.* 2009; 10:708-715.
15. Ramesh, Shukla NK, Bhatnagar S. Phantom breast syndrome. *Indian J Palliat Care.* 2009; 15:103-107.
16. Kaur N, Jain A. Postmastectomy chronic pain in breast cancer survivors: An update on definition, pathogenesis, risk factors, treatment and prevention. *Clin Oncol.* 2017; 2:1300.
17. Rosso R, Scelsi M, Carnevali L. Granular cell traumatic neuroma: A lesion occurring in mastectomy scars. *Arch Pathol Lab Med.* 2000; 124:709-711.
18. Fitzpatrick KA, Borders MH, MacKerricher WS, Bracamonte ER. Traumatic neuroma of the breast after mastectomy. *Appl Radiol.* 2017; 46:26-28.
19. Haj M, Bickel A, Cohen I. Osseous metaplasia of breast neuroma: Diagnosis with stereotactic core biopsy. *Breast J.* 2004; 10:366-367.
20. Kim EY, Kang DK, Kim TH, Kim KS, Yim H. Traumatic neuroma in a breast cancer patient after modified radical

- mastectomy: A case report. *J Korean Soc Radiol.* 2011; 64:515-518.
21. Li Q, Gao EL, Yang YL, Hu HY, Hu XQ. Traumatic neuroma in a patient with breast cancer after mastectomy: A case report and review of the literature. *World J Surg Oncol.* 2012; 10:35.
 22. Shin S. A traumatic neuroma in breast cancer patient after mastectomy: A case report. *J Korean Soc Radiol.* 2013; 69:405-407.
 23. Wang X, Cao X, Ning L. Traumatic neuromas after mastectomy. *ANZ J Surg.* 2007; 77:704-705.
 24. Zhu L, Batdorf NJ, Meares AL, Sukov WR, Lemaine V. Bilateral thoracodorsal neuromas: A cause of persistent breast pain after bilateral latissimus dorsi breast reconstruction. *Arch Plast Surg.* 2015; 42:499-502.

(Received April 28, 2018; Revised July 27, 2018; Accepted August 1, 2018)

Co-occurrence of Gomez-Lopez-Hernandez syndrome and Autism Spectrum Disorder: Case report with review of literature

Bakur Kotetishvili¹, Malkhaz Makashvili^{2,*}, Michael Okujava^{3,4}, Alexandre Kotetishvili¹, Tamar Kopadze⁵

¹B.Kotetishvili Psycho-Neurological Clinic, Tbilisi, Georgia;

²Faculty of the Art and Sciences, Ilia State University, Tbilisi, Georgia;

³Research Institute of Clinical Medicine, Tbilisi, Georgia;

⁴Faculty of Natural Sciences and Engineering, Ilia State University, Tbilisi, Georgia;

⁵European University, Tbilisi, Georgia.

Summary

We report on Gomez-Lopez-Hernandez syndrome (GLHS) in a Caucasian patient, Georgian, 36 months, male, only child born to non-consanguineous parents. There were no similar cases in the family and among close relatives. MRI study confirmed rhombencephalosynapsis (fusion of cerebellar hemispheres in combination with the agenesis of cerebellar vermis) and mild dilation of the lateral ventricles. Other main findings are bilateral parieto-temporal alopecia and brachiturricephaly (broad skull shape and tower-like elongation of the cranium in the vertical axis), low-set posteriorly retracted ears, strabismus (in the right eye), hypotonia (Beighton scale score – 6) and ataxia (trouble maintaining balance). Patient has no signs of trigeminal anesthesia, no recurrent, painless eye infections, corneal opacities and ulcerated wounds on the facial skin and buccal mucosa were observed. Based on the scientific literature we suggest a finding of brachiturricephaly in addition to rhombencephalosynapsis and bilateral alopecia sufficient to put a diagnosis of GLHS. Patient did not speak, disregarded guardians and clinician addressing him, did not make eye contact, was restless and occasionally displayed aggression and self-injurious behavior. These symptoms confirm the earlier diagnosis of Autism Spectrum Disorder (ASD). Therefore, the current study describes a case of co-occurrence of GLHS and ASD.

Keywords: Rhombencephalosynapsis, alopecia, brachiturricephaly, Gomez-Lopez-Hernandez syndrome, autism

1. Introduction

Gomez-Lopez-Hernandez syndrome (GLHS) is characterized by so called "GLHS triad" - rhombencephalosynapsis, trigeminal anesthesia and partial bilateral alopecia of the scalp. Rhombencephalosynapsis denotes brain malformation, mainly expressed in agenesis of cerebellar vermis and fusion of the cerebellar

hemispheres. Rhombencephalosynapsis is observed not only in the case of GLHS, but as an isolated phenomenon as well as in combination with other brain malformations (1). Symptoms, concomitant to GLHS triad, are hydrocephalus, craniosynostosis, midfacial hypoplasia and low set ears, as well as bilateral corneal opacities, ocular hypertelorism-telescanthus, strabismus, clinodactyly of fifth fingers, short stature and intellectual impairment (2-15).

The studies of GLHS are limited in number. To our knowledge, a total of 36 cases of GLHS have been described since the first reports of this clinical condition by Gomez (12) and Lopez-Hernandez (14). Symptomatology of GLHS varies from patient to patient (2-15) and further case studies are important to complete the clinical description of this disease.

Released online in J-STAGE as advance publication August 23, 2018.

*Address correspondence to:

Dr. Malkhaz Makashvili, Faculty of the Art and Sciences, Ilia State University, Cholokashvili st. 3/5, Tbilisi 0113, Georgia.

E-mail: malkhaz_makashvili@iliauni.edu.ge

2. Case Report

Anamnesis: Patient, J.K. (initials are changed), male, Georgian, Caucasian, only child born to non-consanguineous parents. Parents are in good health and there were no similar cases in the family nor among close relatives. Parents do not confirm the incidence of marriage between relatives in their ancestors. J.K. was delivered via Caesarean section, planned beforehand on the mother's demand. Weight at birth – 3.360 kg, length – 52 cm, head circumference - 37 cm. Bilateral parieto-temporal alopecia and brachiturriccephalic dismorphism as well as low-set ears were observed in the first months after birth (Figure 1). Congenital mild hydronephrosis, open foramen ovale and mild deficiency of the tricuspid valve, as well as strabismus were diagnosed one week after birth. J.K. was treated for hydronephrosis. Second examination at the age of 12 months confirmed cessation of cardiological and nephrological complications. At the age of three months J.K. was surgically treated for inguinal hernia. At the age of 5 months, he started to display involuntary head shaking, mainly in posterior direction and increased tension of lower shoulder muscles. EEG examination did not reveal signs of epileptiform activity. EEG parameters were found to fall into age standards. Transfontanel ultrasound revealed dilation of lateral ventricles and longitudinal fissure. At the age of 32 months, J.K. was diagnosed as having Autism Spectrum Disorder (ASD). Diagnostic procedure was performed according to DSM-V criteria and with the use of ADOS-2 and M-CHAT-R™ as additional instruments for completing ASD diagnosis.

The current study: In May 2018, at the age of 36 months J.K. was admitted to the clinic. Weight at the day of admission - 15.300 kg, height - 87 cm and head circumference 48.2 cm. Patient underwent clinical and MRI examination. MRI was performed on 3T scanner (Magnetom Verio, Siemens): T2-(tse), T1-(fl), FLAR, EPI). Pulse sequences in the axial, sagittal and coronal plane were used. Motor development, sensitivity of trigeminal nerve as well as behavior displayed in the clinic were evaluated.

We did not mention any changes in the clinical status of J.K. in the follow up study (June-July 2018). Behavior of J.K. remained unchanged as well.

Parents signed informed consent for publication of the photographs of J.K. in a scientific periodical. Study was conducted in accordance with Declaration of Helsinki principles and has approved by the Ethic Commission of the Georgian Association of Child Neurologists and Neurosurgeons, Tbilisi, Georgia. The results obtained in the current study are summarized in Table 1.

3. Discussion

Absence of cerebellar vermis and fusion of cerebellar

hemispheres, as well as bilateral scalp alopecia are described in all 36 cases of GLHS (see for review 2,9). The current study provides one more description of rombencephalosynapsis and bilateral alopecia in a GLHS sufferer. This is another argument that rombencephalosynapsis and bilateral alopecia represent obligatory symptoms of GLHS. Since it is principal to decide if the presence of trigeminal anesthesia is obligatory for GLHS diagnosis, the data of the literature concerning this issue is summarized in the Table 2.

Authors propose the presence of trigeminal anesthesia and/or bilateral alopecia to complete the diagnosis of GLHS (4). Trigeminal anesthesia, however, was not present in some studies of GLHS. For example, out of four patients only one was found to display trigeminal numbness in (7), one patient out of two was diagnosed as having trigeminal numbness in (3), no signs of trigeminal anesthesia have been revealed in five patients with GLHS (5) and we report on another case of the absence of trigeminal anesthesia in GLHS.

According to (7) "Rhombencephalosynapsis and scalp alopecia are considered obligate criteria for diagnosing GLHS, while trigeminal anesthesia in conjunction with the two obligate criteria represents a diagnosis of GLHS and as such should stand alone as a separate criterion". At the same time, the finding of brachiturriccephaly in addition to rhombencephalosynapsis and bilateral alopecia is considered sufficient to make a diagnosis of GLHS (7). Skull malformation, mainly brachiturriccephaly, is described in most cases of GLHS (see for example 2,7-9). The current study reports on another case of the tower-like deformation of the skull of brachiturriccephalic character. In our opinion, taken together, the data suggest trigeminal anesthesia is not obligatory for diagnosing GLHS in the case of combined rhombencephalosynapsis, alopecia and brachiturriccephaly.

Malformation of the corpus callosum in GLHS is an inconsistent finding: dysgenesis of the corpus callosum in GLHS sufferers is described in (8), thin corpus callosum was revealed in one case of GLHS (6), while other studies do not report on abnormality of this structure in the case of GLHS (4,11). Corpus callosum in J.K. is of normal size and thickness. Arching of the truncus of the corpus callosum (see Figure 1) should be due to the overall cranial and cerebral dismorphism. The finding of the dilation of the lateral ventricle in the current study confirms the presence of ventricular enlargement in GLHS (3). Other brain malformations, described in GLHS sufferers are absence of the septum pellucidum and a thin cortex (3), but not observable in the current study.

As for the law set years, this symptom does not seem obligatory for GLHS, as it is not apparent in some patients with GLHS. For example, authors (5) observed displacement of ears in four out of six patients with GLHS. Strabismus represents a symptom, concomitant

Table 1. Symptoms, observed in the clinical and MRI examination

Symptoms observed	Comments
Craniofacial features:	
Brachiturriccephaly	Broad skull shape and tower-like elongation in vertical axis (Figure 2)
Alopecia	Bilateral parieto-temporal patch of alopecia (Figure 2)
Displaced ears	Low set, posteriorly retracted ears (Figure 2)
Strabismus	
MRI examination	
Rhombencephalosynapsis	Agenesis of cerebellar vermis and fusion of the cerebellar hemispheres (Figure 3)
Other MRI findings	Ventriculomegaly- mild dilatation of the lateral ventricles
Neurodevelopment:	
Hypotonia	Beighton scale score - 6
Ataxia	J.K. experiences trouble maintaining balance
Trigeminal sensitivity	Temperature and touch sensation of the facial skin were found preserved. No recurrent, painless eye infections, corneal opacities and ulcerated wounds on the facial skin and buccal mucosa were observed
Behavior, observed in the clinic	J.K. does not speak, disregards guardians and clinician addressing him, does not keep instructions and makes no eye contact. J.K. is restless, wanders around the room, from time to time grabs the newspapers from the table and rips them. J.K. occasionally displays aggression and self-injurious behavior

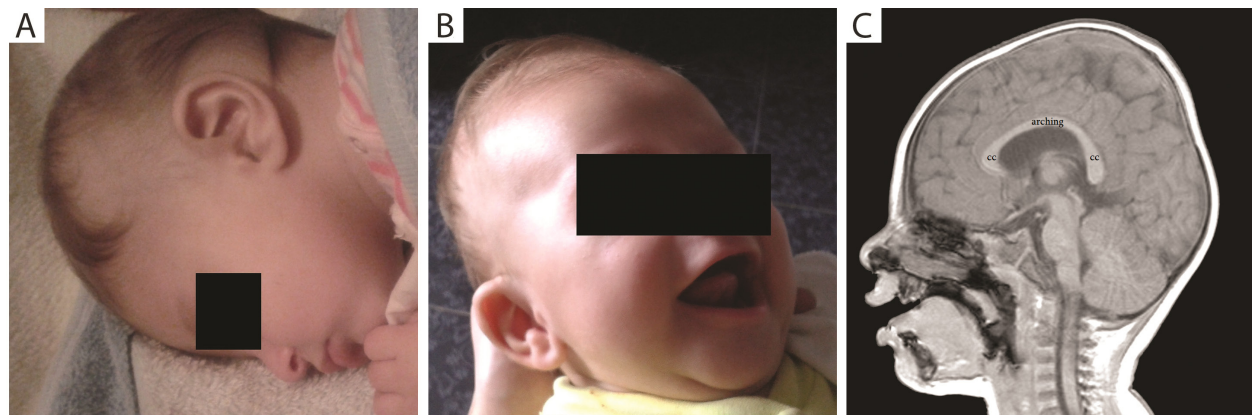

Figure 1. (A), The lack of hair (alopecia) in the left parieto-temporal area; (B), The lack of hair (alopecia) in the right parieto-temporal area, the head elongated in the vertical axis and the low-set ears; (C), The head elongated in the vertical axis and deformed corpus callosum - CC (MRI, sagittal plane). CC deformation is expressed in arching of the middle part of the CC.

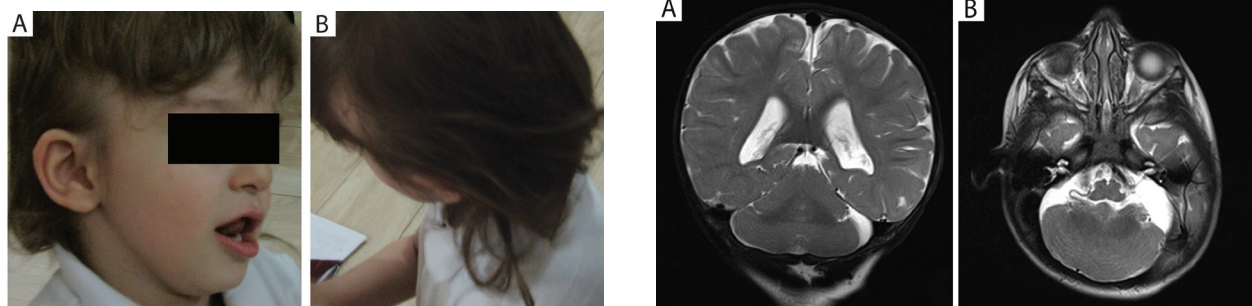


Figure 2. (A), The lack of hair (alopecia) in the right parieto-temporal area and low-set, posteriorly-retracted ears; (B), The lack of hair (alopecia) in the left parieto-temporal area.

Figure 3. Fusion of the cerebellar hemispheres and agenesis of the cerebellar vermis. (A), MRI, T2-weighted image, coronal plane; (B), MRI, T2-weighted image, axial plane.

Table 2. GLHS triad as it is described in the current study and in previous reports on GLHS

Symptoms observed	In the current study	References
Alopecia	observed	observed in 2-15
Rhombencephalosynapsis	observed	observed in 2-15
Trigeminal anesthesia	not observed	not observed in 3,5-7,15; observed in 2,4,7,9, 10,12,14-16.

Digits stand for the number of the manuscript, given in references

to GLHS (2,4,5,7,8,12), however this symptom is not observable in all cases of GLHS (for review see 7,9) and is considered minor craniofacial criteria for diagnosing GLHS (7). We did not observe ptosis in J.K., however it is described in the literature in a few cases of GLHS (5). Similar to the case of J.K., hypotonia and ataxia are mentioned in several reports of GHLS. For example, according to the earlier review of the literature (7) ataxia was described in 73% of patients with GHLS and hypotonia in 77% of GHLS sufferers, while according to a contemporary review (13) the percentage of reports on the presence of ataxia and hypotonia in GHLS patients is 82%.

Cognitive impairment is found in most previously reported patients with GLHS. However, in some cases, cognitive functions are found preserved (for review see 5). Motor restlessness of the GLHS sufferer under our examination is not a new finding since it is observed in other studies of GLHS (4,10). Authors report on psychiatric problems such as hyperactivity, depression, self-injurious behavior and bipolar disorder in patients with GLHS (3,10,15). Co-occurrence of schizophrenia with GLHS is reported as well (11). J.K. was diagnosed as having ASD. On the one hand, we did not find reports on the co-occurrence of ASD and GLHS in the available literature. On the other hand, there are some neurodevelopmental and genetic disorders, which GLHS and ASD may have in common. Cerebellar malformation deserves special attention in this respect. Neocerebellar vermal lobules VI and VII were found to be significantly smaller in patients with autism spectrum disorder (17,18) and atrophy of the vermis is observed in autism sufferers (20). Malformation of cerebellar structures is believed to play a role in intellectual impairment in autism sufferers (18,20,21). Autism was diagnosed in a patient with partial rhombencephalosynapsis (22). Chromosomal mutations in particular cases of rhombencephalosynapsis are associated with autism (23). Evidently, cerebellar malformation is responsible for autistic symptomatology. In our opinion, the current case study suggests rhombencephalosynapsis in GLHS is a structural reason for the development of Autistic Spectrum Disorder in Gomez-Lopez-Hernandez syndrome sufferers.

The genetic background for GHLS is not clear (for review see 4). Similar to some GLHS sufferers (3,4,13,15) and in contrast to some other GLHS patients (3,8,9), J.K. is born to nonconsanguineous parents. At the same time, his parents do not have genetic abnormalities and they do not have witness to a case of marriage between relatives in their ancestors. We hope that these facts may be helpful in further consideration of the role of inheritance in the development of GLHS.

4. Conclusion

Clinical and MRI examination of the patient, male, 36 months, born to non-consanguineous parents revealed

rhombencephalosynapsis, bilateral parieto-temporal alopecia and brachiturricephaly. The patient has no signs of trigeminal anesthesia. Based on the scientific literature we suggest a finding of brachiturricephaly in addition to rhombencephalosynapsis and bilateral alopecia sufficient for a diagnosis of GLHS. Concomitant symptoms are dilation of the lateral ventricles, low-set posteriorly retracted ears, strabismus, ataxia and hypotonia. Patient was diagnosed to have severe symptoms of ASD. Therefore, the current study describes a case of co-occurrence of GLHS and ASD.

References

1. Ishak GE, Dempsey JC, Shaw DWW, Tully H, Adam MP, Sanchez-Lara PA, Glass I, Rue TC, Millen KJ, Dobyns WB, Doherty D. Rhombencephalosynapsis: A hindbrain malformation associated with incomplete separation of midbrain and forebrain, hydrocephalus and a broad spectrum of severity. *Brain*. 2012; 135:1370-1386.
2. Schell-Apacik CC, Cohen M, Vojta S, Ertl-Wagner B, Klopocki E, Heinrich U, von Voss H. Gomez-Lopez-Hernandez syndrome (cerebello-trigeminal-dermal dysplasia): Description of an additional case and review of the literature. *Eur J Pediatr*. 2008; 167:123-126.
3. Gomy I, Heck B, Carlos Santos A, Figueiredo MSL, Martinelli CE, Nogueira Jr MPC, Pina-Neto JM. Two new Brazilian patients with Gómez-López-Hernández syndrome: Reviewing the expanded phenotype with molecular insights. *Am J Med Genet A*. 2008; 146A:649-657.
4. Fernández-Jaén A1, Fernández-Mayoralas DM, Calleja-Pérez B, Muñoz-Jareño N, Moreno N. Gomez-Lopez-Hernandez syndrome: Two new cases and review of the literature. *Pediatr Neurol*. 2009; 40:58-62.
5. Sukhudyay B, Jaladyan V, Melikyan G, Schlump JU, Boltshauser E, Poretti A. Gómez-López-Hernández syndrome: Reappraisal of the diagnostic criteria. *Eur J Pediatr*. 2010; 169:1523-1528
6. Abdel-Salam GMH, Abdel-Hadi S, Thomas MM, Eid OM, Ali MM, Afifi HH. Gómez-López-Hernández syndrome versus rhombencephalosynapsis spectrum: A rare co-occurrence with bipartite parietal bone. *Am J Med Genet A*. 2014; 164A:480-483.
7. Rush ET, Adam MP, Clark RD, Curry C, Hartmann JE, Dobyns WB, Olney AH. Four new patients with Gomez-Lopez-Hernandez syndrome and proposed diagnostic criteria. *Am J Med Genet A*. 2013; 161A:320-326.
8. de Mattos VF, Graziadio C, Machado R, Raphael F, Lenhardt R, Alves RP, Trevisan P, Paskulin GA, Zen P, Gazzola R. Gómez-López-Hernández Syndrome in a child born to consanguineous parents: New evidence for an autosomal-recessive pattern of inheritance? *Pediatr Neurol*. 2014; 50:612-615
9. Choudhary A, Minocha P, Sitaraman S. Gomez-Lopez-Hernández syndrome: First reported case from the Indian subcontinent. *Intractable Rare Dis Res*. 2017; 6:58-60.
10. Brocks D, Irons M, Sadeghi-Najad A, McCauley R, Wheeler P. Gomez-Lopez-Hernandez syndrome: Expansion of the phenotype. *Am J Med Genet*. 2000; 94:405-408.
11. Erzin G, Sücüllü Karadağ Y, Sözmen Cılız D, Yirun O, Cingi M, Çiğdem Aydemir M, Göka E, Ak F. Gómez-

- López-Hernández Syndrome: A case with schizophrenia. *Biol psychiatry*. 2016; 80:e25-e27.
12. Gomez MR. Cerebellotrigeminal and focal dermal dysplasia: A newly recognized neurocutaneous syndrome. *Brain Dev*. 1979; 1:253-256.
 13. Gálvez V C, Huete I, Hernández M. Congenital Hydrocephalus: Gómez-López-Hernández syndrome. An underdiagnosed Syndrome. A clinical case. *Rev Chil Pediatr*. 2018; 89:92-97
 14. López-Hernández A. Craniosynostosis, ataxia, trigeminal anesthesia and parietal alopecia with pons vermis fusion anomaly (atresia of the fourth ventricle). Report of two cases. *Neuropediatrics*. 1982; 13:99-102.
 15. Tan TY, McGillivray G, Goergen SK, White SM. Prenatal magnetic resonance imaging in Gomez-Lopez-Hernandez syndrome and review of the literature. *Am J Med Genet A*. 2005; 138:369-373.
 16. Balaban O, Tobias JD. Perioperative care of an infant with Gomez-Lopez-Hernandez syndrome. *Middle East J Anesthesiol*. 2016; 23:581-585.
 17. Courchesne E, Yeung-Courchesne R, Press GA, Hesselink JR, Jernigan TL. Hypoplasia of cerebellar vermal lobules VI and VII in autism. *N Engl J Med*. 1988; 318:1349-1354.
 18. Courchesne E, Townsend J, Saitoh O. The brain in infantile autism: Posterior fossa structures are abnormal. *Neurology*. 1994; 44:214-223.
 19. Verri A, Uggetti C, Alfonsi E, Ramponi A, Destefani V. Cognitive affective disorder associated with rhombencephalosynapsis. In: *Trends in Autism Research* (Ryaskin OT, ed.) Nova Science Publishers, Inc. 2004; pp.109-132
 20. Schmahmann JD, Weilburg JB, Sherman JC. The neuropsychiatry of the cerebellum—insights from the clinic. *Cerebellum*. 2007; 6:254-267.
 21. Hampson DR, Blatt GJ. Autism spectrum disorders and neuropathology of the cerebellum. *Front Neurosci*. 2015; 9:420.
 22. Ramocki MB, Scaglia F, Stankiewicz P, Belmont JW, Jones JY, Clark GD. Recurrent partial rhombencephalosynapsis and holoprosencephaly in siblings with a mutation of ZIC2. *Am J Med Genet A*. 2011; 155:1574-1580.
 23. Démurger F, Pasquier L, Dubourg C, *et al*. Array-CGH analysis suggests genetic heterogeneity in rhombencephalosynapsis. *Mol Syndromol*. 2013; 4:267-272.

(Received June 9, 2018; Revised July 28, 2018; Accepted August 5, 2018)

Esophageal arteriovenous malformation, a rare cause of significant upper gastrointestinal bleeding: Case report and review of literature

Pradeep Reddy Kathi^{1,*}, Maher Tama², Shankerdas Kundumadam¹, Dhiraj Gulati³, Murray N Ehrinpreis²

¹Department of Internal Medicine, Wayne state University School of Medicine, Detroit, Michigan, USA;

²Division of Gastroenterology, Department of Internal Medicine, Wayne state University School of Medicine, Detroit, MI, USA;

³Department of Gastroenterology, Rush Copley Medical Center, Aurora, IL, USA.

Summary

Gastrointestinal (GI) arteriovenous malformations (AVMs) are a well-known source of bleeding with colon being the most common site, but they can also occur in rare locations like the esophagus which may present with life threatening bleeding. We report the case of a 51-year-old male with end stage renal disease (ESRD) presenting with hematemesis and acute on chronic anemia. Further investigation showed an esophageal AVM which is an unusual location and it was successfully treated with an endoscopic clip instead of argon plasma coagulation (APC) due to its challenging location and esophageal wall motion from breathing. The patient continued to be asymptomatic without any upper and lower GI bleeding during his 20 months follow up period after the endoscopic management. Review of literature showed only 10 cases of AVMs involving esophagus and the average age of presentation was 52 years with a male predominance. We also provide an overview of those cases in the discussion section below.

Keywords: Arteriovenous malformation, esophagus, ESRD, upper GI bleeding

1. Introduction

AVMs of the GI tract were first visualized endoscopically in 1939 by Renshaw and in 1945 by Grossman (1). The overall prevalence of GI AVMs is unknown. They are more common in patients with certain risk factors like chronic kidney disease (CKD). AVMs are responsible for 2-5% of the cases of upper GI bleeding and 3% of lower GI bleeding (2,3). The colon is the most common location (4), where they are most often found in the cecum and ascending colon (5). The small intestine (jejunum > duodenum > ileum) and stomach are the next most common sites of AVMs in the GI tract (4), with esophagus being a rare location.

An analysis of 218 patients with arteriographically documented AVMs by Myers *et al.* reported only one case of esophageal AVM (0.5%) (4). Another study evaluating the distribution of GI angioectasias in a western population by Bollinger *et al.* reported that none of the patients in their study had AVMs in the esophagus (6). Even though only a handful of cases are available in the literature, it is important to consider esophageal AVMs in the differential diagnosis when a patient presents with an upper GI bleed. We describe a case of significant upper GI bleeding due to an isolated esophageal AVM and its challenges in the endoscopic management.

2. Case Report

A 51-year-old African American man presented to the emergency department (ED) in September of 2016 after having three episodes of gross hematemesis. He described the vomitus as large in quantity with fresh blood and clots. The patient had mild abdominal discomfort before the onset of hematemesis that was

Released online in J-STAGE as advance publication August 15, 2018.

*Address correspondence to:

Dr. Pradeep Reddy Kathi, Internal Medicine, Wayne state University School of Medicine, 4201 Saint Antoine street, UHC 2E, Detroit, Michigan 48201, USA.

E-mail: pkathi@med.wayne.edu

relieved by vomiting. He denied having melena or hematochezia. He had a history of gastroesophageal reflux disease (GERD), chronic hepatitis B without cirrhosis controlled with lamivudine, hypertension, and ESRD treated with peritoneal dialysis after having a kidney transplant rejection. He denied taking non-steroidal anti-inflammatory drugs (NSAIDs), anticoagulants or antiplatelet drugs. There was no prior history of hematemesis, peptic ulcer disease (PUD), or any known bleeding disorder. An esophagogastroduodenoscopy (EGD), done 7 years before the current admission, was unremarkable, and a colonoscopy, 2 years prior to admission, showed mild colonic diverticulosis.

On admission, the blood pressure was 162/70 mmHg, heart rate was 85 beats/minute, respiration rate was 16 breaths/min and temperature was 36.7°C. The abdominal examination was normal, and the digital rectal exam showed brown stool with a negative occult blood test. Hemoglobin (Hgb) 55 g/L with a mean corpuscular volume of 76 fL, white blood cell counts $9.5 \times 10^9/L$, and platelets $244 \times 10^9/L$. His baseline Hgb prior to this presentation was 9-10 g/dL due to anemia of chronic disease. The last Hgb value, two months before the current admission, was 10.3 gm/dL. Prothrombin time and activated partial thromboplastin time were within normal limits. The patient received 1 unit of packed red blood cells (pRBC) transfusion and was started on a continuous infusion of pantoprazole. Hematemesis resolved after the admission, but he required two more units of pRBC to maintain a Hgb > 70 g/L. On day two after admission, he had an esophagogastroduodenoscopy (EGD) performed by general surgery for the evaluation of hematemesis which revealed an AVM in the mid-esophagus that was not cauterized due to the location. They recommended the patient be seen by gastroenterology for therapeutic endoscopy. As a complication of the EGD, the patient developed aspiration pneumonia that was evident the day after the procedure, and he was started on antibiotics.

A second EGD procedure was done on day 4 by gastroenterology which revealed a 4 mm mid-esophageal AVM with a small central clean-based ulcer (Figure 1) without active bleeding. Further examination of gastroesophageal junction, gastric and duodenal mucosa was normal. No other source of bleeding was identified. Given the difficult location and esophageal wall motion from breathing, argon plasma coagulation (APC) was not considered to be feasible. A complete obliteration of the AVM was done with a single endoscopic clip. Post application, mucosal anchoring, and obliteration of the lesion was satisfactory (Figure 2). The patient was switched to an oral pantoprazole and was treated for two more days in the hospital for aspiration pneumonia. No further bleeding was reported, Hgb remained stable and he was discharged home on histamine H2-receptor antagonists for GERD and oral antibiotics continued for pneumonia. On

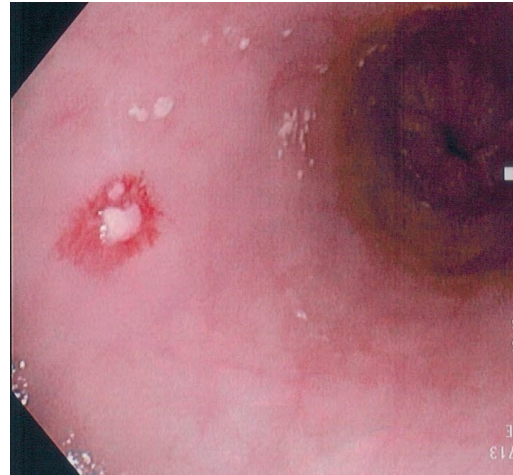

Figure 1. Mid esophageal AVM. A 4 mm mid esophageal arteriovenous malformation with a central clean based ulcer and no stigmata of bleeding at the time of EGD.

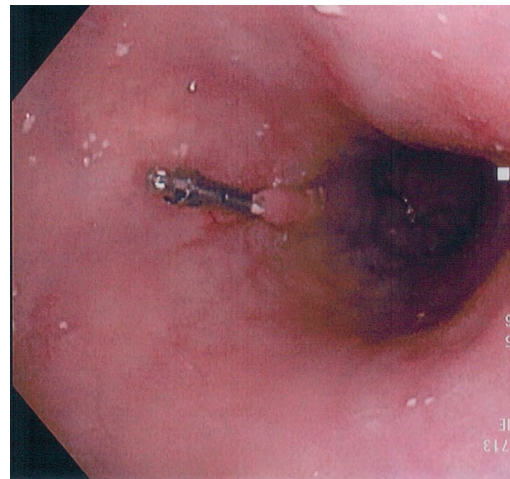

Figure 2. AVM after endoscopic clip placement. A complete obliteration of the mid esophageal arteriovenous malformation after successful application of an endoscopic hemoclip with satisfactory positioning.

further follow up at periodic intervals after discharge until May of 2018 the patient reported no further episodes of hematemesis, melena or hematochezia. His Hgb returned to his usual of 90-100 g/L.

3. Discussion

AVMs are associated with various conditions like CKD, aortic stenosis, Von Willebrand's disease, CREST (calcinosis, Raynaud phenomenon, esophageal dysmotility, sclerodactyly, and telangiectasia) syndrome, and rare conditions like hereditary hemorrhagic telangiectasia (HHT), and Fabry's disease (3,7). A study done by Zuckerman *et al.* evaluating the etiology of upper GI bleed (UGIB) showed AVM (53%) as the leading cause in CKD patients and PUD (51%) as the most common cause in patients without renal failure (8).

The underlying pathology of AVM formation is

Table 1. Summary of published case reports of patients with AVMs involving the esophagus

Author and year of publication	Patient's age	Sex (M/F)	Anatomical location	Clinical presentation	Treatment modality	Associated conditions	Clinical outcome
Kathi <i>et al.</i> (current case)	51	M	Isolated mid esophageal lesion	Hematemesis and anemia	Endoscopic clip	ESRD, GERD, Chronic hepatitis B infection	No recurrence of symptoms after 20 months of follow up
Khanna <i>et al.</i> (14) (2011)	76	M	Isolated Esophageal lesion	Symptomatic anemia	APC	Gastric Antral Vascular Ectasia (GAVE), Barrett's esophagus, Aortic valve replacement	Not documented
Okano <i>et al.</i> (7) (2001)	26	M	Esophagus, Angiokeratoma on skin	Hematemesis	Not treated	Fabry's disease	Not treated
Konstantiakos <i>et al.</i> (13) (1995)	69	M	Isolated Esophageal lesion	Dysphagia	Surgery	N/A	No recurrence of symptoms after 6 months of follow up
Kim <i>et al.</i> (16) (1992)	22	M	Gastroesophageal junction	Hematemesis	Died before treatment and esophageal AVM was found on autopsy	N/A	Death due to hematemesis
Sassaris <i>et al.</i> (15) (1980)	62	M	Isolated Esophageal lesion	Abdominal pain (antral ulcer noticed on EGD)	N/A	PUD, Chronic pancreatitis	Not documented regarding the treatment for AVM
Sassaris <i>et al.</i> (15) (1980)	56	F	Esophagus, Stomach	GI bleeding	Endoscopic coagulation attempted but it was unsuccessful	Multiple myeloma, Chronic renal failure	Patient died after massive GI bleed
Weaver <i>et al.</i> (17) (1979)	71	M	Esophagus, Stomach	Anemia and melena	Endoscopic coagulation	Aortic stenosis, Chronic lung disease, Diverticulosis	Not documented
Schaefer <i>et al.</i> (1) (1973)	46	M	Esophagus, Stomach	Hematemesis	N/A	HHT	Not documented
Christiansen <i>et al.</i> (18) (1970)	N/A	N/A	N/A	N/A	N/A	HHT	N/A
Reynolds <i>et al.</i> (19) (1970)	45	F	Esophagus, Palms, Lips and Tongue	Hematemesis	N/A	CREST syndrome, Primary Biliary Cirrhosis	Not documented

N/A not available.

not well understood. Various hypotheses have been proposed. One suggested possible vascular degeneration promoted by hypo-oxygenation of the mucosa due to atherosclerosis of the vessels (9). Other theories suggest increased pressure in the venous system could lead to the formation of the AVMs (10).

Clinical presentations of AVM include hematemesis, melena, bleeding per rectum, unexplained iron deficiency and anemia (4,11). Diagnosis is usually made by endoscopy, however, in some cases, angiography or surgery may be required to make the diagnosis. Endoscopic therapy with APC is the most successful method of treatment (12). Bipolar coagulation can also be used in the treatment of AVM. However, APC is more commonly used due to its ease of use, low cost, and the lower rate of complications. Hemostasis with clips can be used in cases where lesions are localized or APC is difficult to be performed as described in this case.

The PubMed literature search query returned a total of 10 cases of esophageal AVMs reported in combination with AVMs at other locations or as a part of a syndrome (1,7,13-19). A brief description of the patients' characteristics of the published case reports is mentioned above in Table 1. Details regarding one of the patients were not available. The most common presentation was hematemesis followed by anemia as it was in the current case. AVMs were seen predominantly in males (8/10) compared to females (2/10) with age ranging from 22-76 years and the average age of presentation was found to be 52. Out of ten patients, only 3 cases of isolated esophageal AVMs were reported (13-15), and to the best of our knowledge, the case described here will likely represent the 4th case in that group with its unique challenges in the management and successful hemostasis with an endoscopic clip.

4. Conclusion

Despite its rarity in clinical practice, the case described here provides evidence that esophageal AVMs can cause life threatening upper GI bleeding. They should be considered in the differential in a patient with upper GI bleeding especially in the background of risk factor such as ESRD, and timely intervention could be lifesaving.

References

1. Schaefer RA, Goldstein MJ. Gastric and esophageal telangiectasia: A case report. *Gastrointest Endosc.* 1973; 19:192-193.
2. Ghassemi KA, Jensen DM. Lower GI bleeding: Epidemiology and management. *Curr Gastroenterol Rep.* 2013; 15:333.
3. Acosta RD, Wong RK. Differential diagnosis of upper gastrointestinal bleeding proximal to the ligament of

- Trietz. *Gastrointest Endosc Clin N Am.* 2011; 21:555-566.
4. Meyer CT, Troncale FJ, Galloway S, Sheahan DG. Arteriovenous malformations of the bowel: An analysis of 22 cases and a review of the literature. *Medicine (Baltimore).* 1981; 60:36-48.
5. Höchter W, Weingart J, Kühner W, Frimberger E, Ottenjann R. Angiodysplasia in the colon and rectum. Endoscopic morphology, localisation and frequency. *Endoscopy.* 1985;17:182-185.
6. Bollinger E, Raines D, Saitta P. Distribution of bleeding gastrointestinal angioectasias in a Western population. *World J Gastroenterol.* 2012;18:6235-6239.
7. Okano H, Shiraki K, Tsunooka K, Tamai T, Nakazawa S, Masuoka H, Sugawa M, Yamakado T, Kosaka Y, Nakano T. Esophageal vascular ectasia associated with Fabry's disease. *Gastrointest Endosc.* 2001; 53:125-126.
8. Zuckerman GR, Cornette GL, Clouse RE, Harter HR. Upper gastrointestinal bleeding in patients with chronic renal failure. *Ann Intern Med.* 1985; 102:588-592.
9. Kaaroud H, Fatma LB, Beji S, Boubaker K, Hedri H, Hamida FB, El Younsi F, Abdallah TB, Maiz HB, Kheder A. Gastrointestinal angiodysplasia in chronic renal failure. *Saudi J Kidney Dis Transpl.* 2008; 19:809-812.
10. Boley SJ, DiBiase A, Brandt LJ, Sammartano RJ. Lower intestinal bleeding in the elderly. *Am J Surg.* 1979; 137:57-64.
11. Zajjari Y, Tamzaourte M, Montasser D, Hassani K, Aatif T, El Kabbaj D, Benyahya M. Gastrointestinal bleeding due to angiodysplasia in patients on hemodialysis: A single-center study. *Saudi J Kidney Dis Transpl.* 2016; 27:748-751.
12. Vargo JJ. Clinical applications of the argon plasma coagulator. *Gastrointest Endosc.* 2004; 59:81-88.
13. Konstantakos AK, Douglas WI, Abdul-Karim FW, Lee JH, Geha AS. Arteriovenous malformation of the esophagus disguised as a leiomyoma. *Ann Thorac Surg.* 1995; 60:1798-1800.
14. Khanna S, Arora AS, Topazian MD. Esophageal vascular ectasia. *Endoscopy.* 2011; 43 Suppl 2 UCTN E281.
15. Sarris M, Pang G, Hunter F. Telangiectasias of the upper gastrointestinal tract. Report of six cases and review. *Endoscopy.* 1983; 15:85-88.
16. Kim CJ, Kwak BH, Kim SD, Kim SP. Sudden death in angiodysplasia of the gastroesophageal junction. *Am J Forensic Med Pathol.* 1992;13:211-213.
17. Weaver GA, Alpern HD, Davis JS, Ramsey WH, Reichelderfer M. Gastrointestinal angiodysplasia associated with aortic valve disease: Part of a spectrum of angiodysplasia of the gut. *Gastroenterology.* 1979; 77:1-11.
18. Christiansen J, Funding J. Hereditary hemorrhagic telangiectasia (Osler's Disease) as the cause of gastrointestinal hemorrhage. *Acta Chir Scand.* 1970; 136:213-218.
19. Reynolds TB, Denison EK, Frankl HD, Lieberman FL, Peters RL. Primary biliary cirrhosis with scleroderma, Raynaud's phenomenon and telangiectasia. New syndrome. *Am J Med.* 1971; 50:302-312.

(Received July 5, 2018; Revised July 30, 2018; Accepted August 5, 2018)

Recurrent chyloous effusions and venous thrombosis: Uncommon presentation of a common condition

Manasvini Bhatt¹, Netto George¹, Manish Soneja^{1,*}, Prabhat Kumar¹, Surabhi Vyas², Ashutosh Biswas¹

¹Department of Medicine, All India Institute of Medical Sciences, New Delhi, India;

²Department of Radiodiagnosis, All India Institute of Medical Sciences, New Delhi, India.

Summary

Spontaneous bilateral chylothorax and chyloous ascites rarely develop in conjunction with systemic venous thrombosis, and the most common cause of non-traumatic chyloous effusion is a malignancy. A 23-year-old immunocompetent female presented with a fever of 5 months' duration associated with progressive shortness of breath and abdominal distension. Evaluation revealed bilateral chylothorax, chyloous ascites, and multiple venous thrombosis. Anti-tubercular drugs were initiated on the basis of a lymph node biopsy and computed tomography findings, but her symptoms worsened, and she developed massive bilateral pleural effusions with type 2 respiratory failure requiring invasive mechanical ventilation. She was managed with anti-tubercular drugs, chest tube drainage, octreotide, anticoagulants, and other supportive treatments. A multipronged approach to the management of chyloous effusions and addition of octreotide led to resolution of symptoms. The challenges faced in diagnosing and managing this case are discussed in this report.

Keywords: Chylothorax, chyloous ascites, tuberculosis, hypercoagulability, octreotide

1. Introduction

Chylothorax and chyloous ascites are characterized by accumulation of chyle in the pleural and peritoneal cavities produced by obstruction and disruption of the lymphatic channels. Chylothorax and chyloous ascites are commonly caused by direct injury to the thoracic duct after surgery or by infiltration of the lymphatic system secondary to a malignant disease (1,2). The reported incidence of the combined occurrence of chylothorax and chyloous ascites has varied from 9% to 55% in cases of chyloous effusions (3,4). Tuberculosis (TB) and its association with a hypercoagulable state are seldom recognized as causes of chylothorax and chyloous ascites. Presented here is the case of a young immunocompetent female with recurrent bilateral chylothorax and chyloous ascites and venous thrombosis in major central veins of

the body. These conditions were all attributed to TB, a common infection. The challenges faced in diagnosing and managing this case are discussed in this report.

2. Case Report

A 23-year-old female with no prior comorbidities presented with a low-grade fever (documented 100-101^oF) of 5 months' duration associated with loss of appetite and weight loss. She also complained of progressive shortness of breath and abdominal distension for 3 months prior. An examination at a local hospital revealed bilateral chylothorax and chyloous ascites. The woman was admitted there for the same complaints twice. There, she underwent multiple pleurocenteses, followed by bilateral intercostal tube insertion. A cervical lymph node was biopsied, revealing multiple well-defined caseating granulomas with necrosis. Contrast-enhanced computed tomography (CECT) of the chest and abdomen suggested a tubercular etiology, and category 1 anti-tubercular therapy was initiated. The woman was then discharged. Ten days later, her symptoms worsened, so she was referred to this Hospital. An interview indicated that she had a fever for 5 months with weight

Released online in J-STAGE as advance publication August 28, 2018.

*Address correspondence to:

Dr. Manish Soneja, Department of Medicine, All India Institute of Medical Sciences, New Delhi 110029, India.

E-mail: manishsoneja@gmail.com

loss, shortness of breath and abdominal distension for 3 months that worsened over the previous 10 days, and altered sensorium for 5 days. There was no history of coughing with expectoration, hemoptysis, or abnormal bowel movements.

Table 1. Routine hematological and biochemical profile

Items	At admission	At discharge
Hb (gm/dL)	10.9	9.6
Platelet count (/mm ³)	591 × 10 ⁶	587 × 10 ⁶
TLC (/mm ³)	10,300	10,000
Urea (mg/dL)	16	19
Creatinine (mg/dL)	0.2	0.4
Na (mEq/L)	139	136
K (mEq/L)	4.4	4.3
Total bilirubin (mg/dL)	1.0	1.1
Total protein (g/dL)	5.7	6.2
Albumin (g/dL)	2.5	2.8
Globulin (g/dL)	3.2	3.4
AST (IU/L)	38	20
ALT (IU/L)	18	8
ALP (IU/L)	245	204
ESR (mm/hr)	52	34

ALP, alkaline phosphatase; ALT, alanine aminotransferase; AST, aspartate aminotransferase; ESR, erythrocyte sedimentation rate; Hb, hemoglobin; TLC, total leucocyte count.

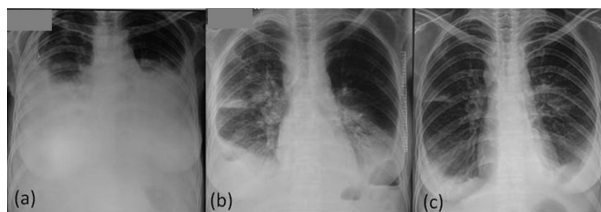


Figure 1. Serial chest radiographs. (A) At admission showing bilateral partially opaque hemithoraces and patchy opacities in bilateral lung fields; **(B)** Showing a reduction in bilateral lung field opacities with fluid along the bilateral costophrenic angles and right horizontal fissure; **(C)** Follow-up radiograph showing minimal residual opacities in the bilateral lower lung fields and costophrenic angles.

On examination, she was drowsy (10 on the Glasgow Coma Scale) and had stable vital signs. Pallor was present. A respiratory examination revealed a dull percussion note and absence of breath sounds in the bilateral inframammary, infra axillary, and infra scapular regions. There was no shifting dullness or organomegaly on abdominal examination. The rest of the general and systemic examination was normal.

A routine hematological and biochemical profile revealed normocytic normochromic anaemia, an elevated erythrocyte sedimentation rate (ESR), and reversal of the albumin:globulin ratio (Table 1). A chest radiograph revealed bilateral massive pleural effusions (Figure 1 A and 1B). An intercostal tube was placed on the right side, and it drained chylous fluid with an uninterrupted flow. As her condition progressively worsened, another intercostal tube was placed on the left side. She required intubation on day 2 of hospitalization due to worsening type 2 respiratory failure. A chest radiograph was repeated to rule out consolidation, and a two-dimensional (2D)-echocardiography was performed to rule out massive pulmonary embolism as a cause of the sudden worsening of the patient's condition that required mechanical ventilation. Chylous fluid was exudative in nature and predominantly consisted of lymphocytes. Triglycerides were elevated, and results of a microbiological (Gram staining, acid-fast bacilli staining/ GeneXpert/fungal staining) and a cytological evaluation were negative (Table 2). There was no evidence of ascites in an ultrasound of the abdomen. CECT of the chest and abdomen suggested bilateral pleural effusion with enlarged mediastinal and retroperitoneal lymph nodes and ileo-cecal thickening (Figure 2). CECT also revealed partial thrombosis of the right internal jugular vein, left brachiocephalic vein, and right iliac vein. Coagulation and autoimmune profiles were normal (Table 3). Since the patient was on mechanical ventilation, invasive sampling of the mediastinal lymph nodes was

Table 2. Analysis of pleural fluid at different time points

Items	Sample 1	Sample 2 (on octreotide)
TLC (/mm ³)	350	160
DLC	L60P40	L80P20
VLDL (mg/dL)	30	21
Triglycerides (mg/dL)	733	154
Cholesterol (mg/dL)	63	179
LDL/HDL	2.7	4.1
LDL (mg/dL)	24	127
Amylase (IU/L)	1.5	1.6
Albumin (g/dL)	1.2	1.8
Glucose (mg/dL)	55	60
Protein (g/dL)	2.3	2.9
Gram staining/bacterial culture	No organism/Negative	No organism/Negative
KOH staining/fungal culture	No organism/Negative	No organism/Negative
AFB staining	Negative	Negative
GeneXpert	Negative	Negative
Malignant cytology	Negative	Negative

AFB, acid-fast bacilli; DLC, differential leucocyte count; L, lymphocytes; LDL, low-density lipoprotein; P, polymorphs; TLC, total leucocyte count; VLDL, very-low-density lipoprotein.

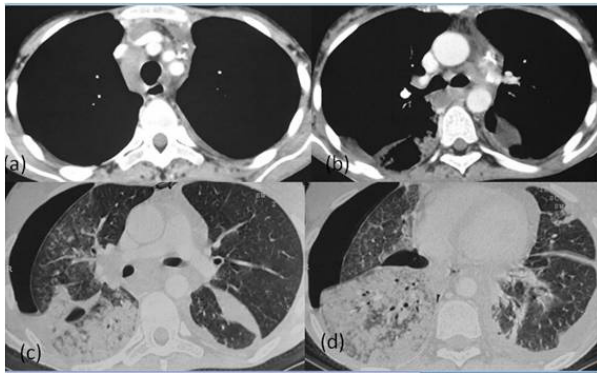


Figure 2. Axial CT images. Mediastinal windows (A, B) showing enlarged right paratracheal and aorto-pulmonary window lymph nodes with minimal bilateral pleural effusion. Lung window images (C, D) showing right-sided pneumothorax with areas of consolidation in the right lower lobe. There are centrilobular nodules with a tree-in-bud appearance in the right upper lobe.

Table 3. Results of a work-up for coagulation abnormalities

Parameter	Value
Prothrombin time (sec)	14.5
INR	1.5
aPTT (sec)	34
Anti-cardiolipin antibody	Negative
Lupus anticoagulant	Negative

aPTT, activated partial thromboplastin time; INR, international normalized ratio.

not attempted, and anti-tubercular therapy was continued. To rule out an underlying malignancy, 18F-fluoro-deoxy-glucose positron emission tomography with computed tomography (18F-FDG-PET/CT) was performed. PET/CT revealed an increased FDG uptake in bilateral pleural (mediastinal and retroperitoneal) lymph nodes. A CT-guided biopsy of the retroperitoneal lymph nodes was negative according to GeneXpert, and histopathology indicated predominant necrosis and few epithelioid cells. Lymphangiography was performed starting at the retroperitoneal lymph nodes and lymphoscintigraphy was performed to identify the source of lymphatic leakage, but those examinations revealed no leakage. In light of the patient's symptomatic recurrent chyloous effusions, she was started on intravenous octreotide 100 mcg three times a day. This was gradually reduced as the drain output decreased. The patient was gradually weaned off of the ventilator, and the intercostal tubes were removed. She was started on a medium-chain triglyceride-rich diet. Anticoagulation with heparin was started and coincided with warfarin as the patient's coagulation profile was monitored. The patient was hemodynamically stable, so she was discharged. Her condition was satisfactory at a follow-up 4 months after discharge (Figure 1C).

3. Discussion

The current patient presented with recurrent bilateral

chylothorax and chyloous ascites due to TB, that also caused a systemic hypercoagulable state. Chylothorax (chyloous effusion) is defined as accumulation of chyle in the pleural space due to disruption or obstruction of the thoracic duct (4). The hallmark of chyloous effusion is the presence of chylomicrons in the fluid. Objective diagnostic criteria include a pleural fluid triglyceride level > 110 mg/dL and a ratio of pleural fluid to serum triglyceride level of > 1.0. Both criteria were fulfilled in the current case.

The most common cause of non-traumatic chyloous effusion is a malignancy, such as lymphoma or metastatic carcinoma (5,6). Other causes of non-traumatic chyloous effusion include idiopathic chyloous effusion, a congenital anomaly, protein-losing enteropathy, and TB (6,7). The current patient denied any history of trauma, CT scans of the chest and abdomen revealed no evidence of a malignancy, and repeated cytologic examinations of pleural effusion revealed no malignant cells. A CT scan showed multiple necrotic lymph nodes in the abdominal cavity and centrilobular nodules with a tree-in-bud appearance in the right lung suggestive of TB, but a fluid examination was negative for acid-fast bacilli, negative according to GeneXpert, and fluid contained low levels of adenosine deaminase. Acid-fast staining and GeneXpert testing of pleural fluid have low levels of sensitivity, and their role in examining chyloous fluid has seldom been reported (8).

A possible mechanism for tuberculous lymphadenitis causing chylothorax is presumably enlarged mediastinal and hilar lymph nodes obstructing lymph flow, thereby facilitating lymphovenous communication between the thoracic duct and the azygos and intercostal veins by placing pressure on the thoracic duct and cisterna chyli (9-11). Methods used to find the site of a chyloous leak like lymphangiography are not viable due to difficulty in visualizing the entire length of the thoracic duct because of the poor mix of oily contrast medium and chyle. A detailed examination of the lymphatic system was accomplished *via* lymphoscintigraphy, which has a sensitivity of 88% and a specificity of 100% (12,13). However, it lacks sufficient spatial resolution to outline morphologic details. In the current case, lymphoscintigraphy was performed after the patient was stabilized, and it revealed no leaks. Non-contrast magnetic resonance lymphangiography allows detailed visualization of the entire thoracic duct, but its role has only been described in a few case series.

TB is associated with a systemic pro-coagulant state, as indicated by enhanced coagulation activation (increased plasma levels of thrombin-antithrombin complexes, D-dimer, and fibrinogen) along with impaired anticoagulant mechanisms like low plasma levels of antithrombin (14). Disease results in the production of pro-inflammatory cytokines that make the vascular endothelium more thrombogenic, in turn increasing the synthesis of coagulation proteins by the

liver. TB can cause thrombosis by various mechanisms such as local invasion, venous compression, or by producing a transitory hypercoagulable state (15-17). Although TB is widely prevalent in India, data on its association with a hypercoagulable state are limited. Whether anticoagulation is needed and its duration have yet to be standardized, so carefully conducted clinical trials need to be conducted to answer these questions. Moreover, oral anticoagulation must be carefully monitored because of hepatic enzyme induction by anti-TB drugs (10-12).

Treatment of chylothorax requires a multi-pronged approach. Conservative treatment involves supplementation of medium-chain triglycerides, total parenteral nutrition, and thoracentesis. Octreotide has been successfully used to treat chylothorax even though its dose and duration have not been clearly specified. In retrospective studies of the effectiveness of octreotide in treating chylothorax, the consensus view was that conservative treatment with octreotide should be instituted for 1 week before considering surgery (18,19). In the current case, treatment with octreotide and low-molecular-weight heparin was used and chylous drainage gradually subsided. The patient was weaned off of ventilatory support and chest drains were removed. Further imaging suggested resolution of the effusion, so she was discharged. The patient's condition was satisfactory at follow up after 4 months.

In conclusion, chylous effusions with venous thrombosis can be caused by TB, although traumatic injury and malignancy are more common etiologies. Treatment of chylous effusions requires a multipronged approach, and octreotide is a useful treatment for those effusions.

References

1. Cárdenas A, Chopra S. Chylous ascites. *Am J Gastroenterol.* 2002; 97:1896-1900.
2. Aalami OO, Allen DB, Organ CH Jr. Chylous ascites: A collective review. *Surgery.* 2000; 128:761-778.
3. Romero S, Martín C, Hernandez L, Verdu J, Trigo C, Perez-Mateo M, Alemany L. Chylothorax in cirrhosis of the liver: Analysis of its frequency and clinical characteristics. *Chest.* 1998; 114:154-159.
4. Maldonado F, Hawkins FJ, Daniels CE, Doerr CH, Decker PA, Ryu JH. Pleural fluid characteristics of chylothorax. *Mayo Clin Proc.* 2009; 84:129-133.
5. Expert Panel on Vascular Imaging and Interventional Radiology: Majdalany BS, Murrey DA Jr, Kapoor BS, Cain TR, Ganguli S, Kent MS, Maldonado F, McBride JJ, Minocha J, Reis SP, Lorenz JM, Kalva SP. ACR Appropriateness Criteria® Chylothorax Treatment Planning. *J Am Coll Radiol.* 2017; 14:S118-S126.
6. Hillerdal G. Chylothorax and pseudochylothorax. *Eur Respir J.* 1997; 10:1157-1162.
7. McGrath EE, Blades Z, Anderson PB. Chylothorax: Aetiology, diagnosis and therapeutic options. *Respir Med.* 2010; 104:1-8.
8. Sharma SK, Kohli M, Chaubey J, Yadav RN, Sharma R, Singh BK, Sreenivas V, Sharma A, Bhatia R, Jain D, Seenu V, Dhar A, Soneja M. Evaluation of Xpert MTB/RIF assay performance in diagnosing extrapulmonary tuberculosis among adults in a tertiary care centre in India. *Eur Respir J.* 2014; 44:1090-1093.
9. El Hammoumi MM, Drissi G, Achir A, Benchekroun A, Kabiri EH, Benosman A. Spontaneous bilateral chylothorax revealing a mediastinal and abdominal lymph node tuberculosis. *Rev Pneumol Clin.* 2014; 70:173-176. (in French)
10. Kutlu O, Demirbas S, Sakin A. Chylothorax due to tuberculosis lymphadenitis. *North Clin Istanb.* 2017; 3:225-228.
11. Rajagopala S, Kancherla R, Ramanathan RP. Tuberculosis-associated chylothorax: Case report and systematic review of the literature. *Respiration.* 2018; 95:260-268.
12. Kant S, Verma SK, Anand SC, Prasad R, Verma RK. Development of bilateral chylothorax in a younger female secondary to tuberculosis. *Lung India.* 2011; 28:56-59.
13. Weiss M, Schwarz F, Wallmichrath J, Baumeister R, Frick A, Bartenstein P, Rominger A. Chylothorax and chylous ascites. Clinical utility of planar scintigraphy and tomographic imaging with SPECT/CT. *Nuklearmedizin.* 2015; 54:231-240.
14. Notohamiprodjo M, Weiss M, Baumeister RG, Sommer WH, Helck A, Crispin A, Reiser MF, Herrmann KA. MR lymphangiography at 3.0 T: Correlation with lymphoscintigraphy. *Radiology.* 2012; 264:78-87.
15. Kager LM, Blok DC, Lede IO, *et al.* Pulmonary tuberculosis induces a systemic hypercoagulable state. *J Infect.* 2015; 70:324-334.
16. Goncalves IM, Alves DC, Carvalho A, do Ceu Brito M, Calvario F, Duarte R. Tuberculosis and venous thromboembolism: A case series. *Cases J.* 2009; 2:9333.
17. Gupta A, Mrigpuri P, Faye A, Bandyopadhyay D, Singla R. Pulmonary tuberculosis - An emerging risk factor for venous thromboembolism: A case series and review of literature. *Lung India.* 2017; 34:65-69.
18. Sharkey AJ, Rao JN. The successful use of octreotide in the treatment of traumatic chylothorax. *Tex Heart Inst J.* 2012; 39:428-430.
19. Ismail NA, Gordon J, Dunning J. The use of octreotide in the treatment of chylothorax following cardiothoracic surgery. *Interact Cardiovasc Thorac Surg.* 2015; 20:848-854.

(Received July 14, 2018; Revised August 17, 2018; Accepted August 19, 2018)

Successful treatment of acute-on-chronic liver failure and hemolytic anemia with hepato-protective drugs in combination with intravenous ozone without steroids: A case report

Zhaohui Bai^{1,2,§}, Hongyu Li^{1,§,*}, Xiaozhong Guo^{1,§}, Yanqin Liu³, Jiao Deng⁴, Chunhui Wang⁵, Yingying Li^{1,6}, Xingshun Qi^{1,*}

¹Department of Gastroenterology, General Hospital of Shenyang Military Area, Shenyang, China;

²Postgraduate College, Shenyang Pharmaceutical University, Shenyang, China;

³Department of Hematology, General Hospital of Shenyang Military Area, Shenyang, China;

⁴Department of Pharmacology, General Hospital of Shenyang Military Area, Shenyang, China;

⁵Department of Hepatobiliary Surgery, General Hospital of Shenyang Military Area, Shenyang, China;

⁶Postgraduate College, Jinzhou Medical University, Jinzhou, China.

Summary

Both acute-on-chronic liver failure (ACLF) and autoimmune hemolytic anemia (AIHA) are common causes of jaundice. A co-occurrence of ACLF and AIHA is rare in clinical practice. This report describes a male elderly patient who developed persistently increased levels of total bilirubin and ascites after endoscopic retrograde cholangiopancreatography for the successful treatment of common bile duct stones. Eventually, he was diagnosed with ACLF and AIHA according to current diagnostic criteria. The patient was given conventional hepato-protective drugs, human albumin, and diuretics in combination with immune ozone without steroids, and he responded well. The therapeutic role of immune ozone in this case is also discussed. When immune ozone was given, total bilirubin gradually decreased; however, no change in total bilirubin was observed after immune ozone was stopped. Notably, when immune ozone was re-initiated, total bilirubin decreased again.

Keywords: Acute-on-chronic liver failure, hemolytic anemia, liver cirrhosis, jaundice, immune ozone

1. Introduction

Acute-on-chronic liver failure (ACLF) is potentially life-threatening (1). According to the guidelines of the Asia Pacific Association of Liver Diseases (APASL), ACLF is diagnosed if a patient with previously diagnosed or undiagnosed chronic liver disease/cirrhosis has the following symptoms: jaundice (serum total

bilirubin (TBIL) > 5 mg/dL [85 umol/L]), coagulopathy (international standardization ratio (INR) > 1.5 or prothrombin activity < 40%), and development of ascites and/or encephalopathy within 4 weeks (1). Treatment of ACLF mainly includes comprehensive medical treatment, artificial extracorporeal liver support, and liver transplantation (2).

Autoimmune hemolytic anemia (AIHA) is an acquired heterogeneous autoimmune disease characterized by autoantibodies attacking antigens on autologous red blood cells (RBCs), resulting in destruction of RBCs (3). AIHA is a relatively rare disorder, with an estimated incidence of 1 to 3 cases in 100,000 persons per year (4). AIHA can occur at any age, but its risk increases with age, and particularly so after the age of 40 (5). Diagnostic criteria for AIHA include: *i*) anemia defined as a decreased hemoglobin level; *ii*) the presence of erythrocyte autoantibodies; and *iii*) at least one of the following conditions: a percentage

Released online in J-STAGE as advance publication August 28, 2018.

§These authors contributed equally to this work.

*Address correspondence to:

Dr. Xingshun Qi and Prof. Hongyu Li, Department of Gastroenterology, General Hospital of Shenyang Military Area, No. 83 Wenhua Road, Shenyang, 110840 Liaoning Province, China.

E-mail: xingshunqi@126.com (XQ); 13309887041@163.com (HL)

of reticulocytes $> 4\%$ or an absolute value $> 120 \times 10^9/L$, along with a globin level $< 100 \text{ mg/L}$, and TBIL $\geq 17.1 \text{ umol/L}$ (mainly an increase in indirect bilirubin [IBIL]) (6). Treatment of AIHA mainly includes blood transfusions, glucocorticoid therapy, splenectomy, administration of rituximab, and administration of cytotoxic immunosuppressive agents (6).

Immune ozone, also known as ozonated autologous blood therapy, has been used for nearly 40 years. Ozone therapy is widely used for cardiovascular, gastrointestinal, genitourinary, central nervous, head and neck, musculoskeletal, subcutaneous tissue, and peripheral vascular diseases (7). Ozone may be effective for the management of some vascular diseases (8). However, it has not been accepted as a standard therapeutic modality or by orthodox medicine (9). Bocci pointed out that ozonated blood can readily maintain the lifespan of RBCs in the circulatory system (10).

The current report describes an elderly male patient with ACLF and AIHA who responded well to hepatoprotective drugs combined with immune ozone.

2. Case Report

On February 2018, an 81-year-old male presented with abdominal pain and a fever and was treated with traditional Chinese medicine at a local hospital. On March 2018, he developed abdominal pain and a fever again. Abdominal computed tomography (CT) showed abnormal morphology of the pancreas (Figure 1). Magnetic resonance cholangiopancreatography (MRCP) showed choledocholithiasis (Figure 2). He received conservative treatment at a local hospital, and his symptoms abated.

On April 2, 2018, he developed abdominal pain and a fever after diarrhea with a yellowing of the skin and eyes and was admitted to the Emergency Department at this Hospital. Abdominal CT scans showed liver cirrhosis, abnormal morphology of the pancreas,

ascites, and choledocholithiasis (Figure 3). Laboratory results indicated that serum TBIL was 79.0 umol/L (reference range: $5.1\text{-}22.2 \text{ umol/L}$), direct bilirubin (DBIL) was 60.8 umol/L (reference range: $0\text{-}8.6 \text{ umol/L}$), serum amylase (AMY) was $1,840.00 \text{ U/L}$ (reference range: $30\text{-}110 \text{ U/L}$), and serum lipase (LIPA) was $> 6000 \text{ U/L}$ (reference range: $23\text{-}300 \text{ U/L}$).

On April 4, 2018, the patient underwent endoscopic retrograde cholangiopancreatography (ERCP) in Hepatobiliary Surgery at this Hospital. A stone $0.6 \times 0.5 \text{ cm}$ in size was removed from the common bile duct. Abdominal pain was greatly alleviated. However, jaundice worsened, and TBIL and DBIL levels continued to increase (Figure 4). In addition, gross ascites developed and gradually worsened. On April 8, 2018, the patient underwent a cholangiography *via* a naso-biliary drainage catheter that suggested the patency of the common bile duct. On April 13, 2018, the patient underwent laboratory tests for hepatitis A, hepatitis E, hepatitis B, hemolysis, immunity-related liver diseases, and tumor markers. Viral hepatitis and immunity-related liver diseases were ruled out. Hemolysis tests indicated that erythrocyte osmotic fragility (primary dissolution) was 0.35% (reference range: $0.40\text{-}0.45\%$), erythrocyte osmotic fragility (completely soluble) was 0.30% (reference range: $0.35\text{-}0.40\%$), and the Coombs test was positive.

On April 16, 2018, the patient was transferred to Gastroenterology at this Hospital. His disease history was reviewed in detail. He suffered from intractable insomnia in 1998 and took alprazolam tablets for more than 10 years. He had no history of hypertension. He had never smoked nor drunk alcohol. Laboratory results indicated that the RBC count was $2.58 \times 10^{12}/L$ (reference range: $4.0\text{-}5.5 \times 10^{12}/L$), hemoglobin (Hb) was 96 g/L (reference range: $110\text{-}150 \text{ g/L}$), the percentage of reticulocytes was 4.71% (reference range: $0.5\text{-}2.0\%$), the reticulocyte count was $0.122 \times 10^9/L$ (reference range: $0.015\text{-}0.1 \times 10^9/L$), TBIL

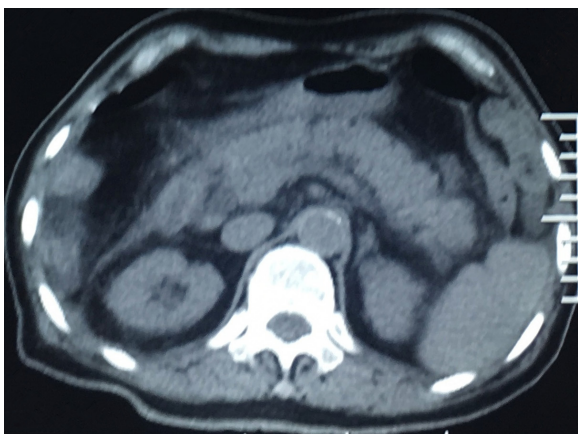

Figure 1. Abdominal CT was performed at a local hospital on March 2018 and showed abnormal morphology of the pancreas.

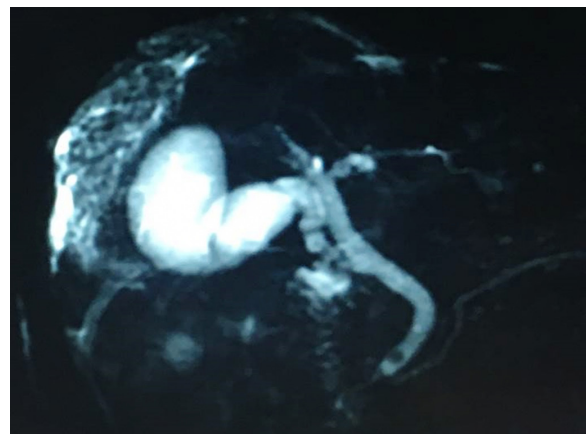


Figure 2. Magnetic resonance cholangiopancreatography was performed at a local hospital on March 2018 and showed an enlarged gallbladder and a stone at the end of the common bile duct.

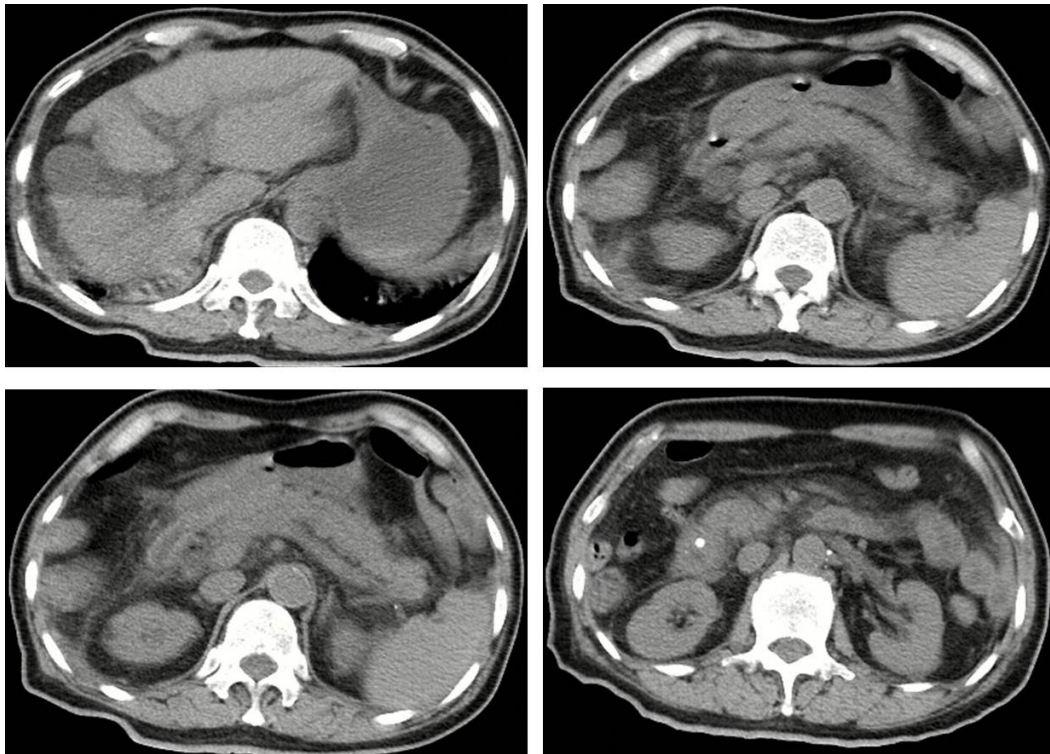


Figure 3. Abdominal CT scans at this Hospital on April 2, 2018 showing liver cirrhosis, abnormal morphology of the pancreas, ascites, and cholelithiasis.

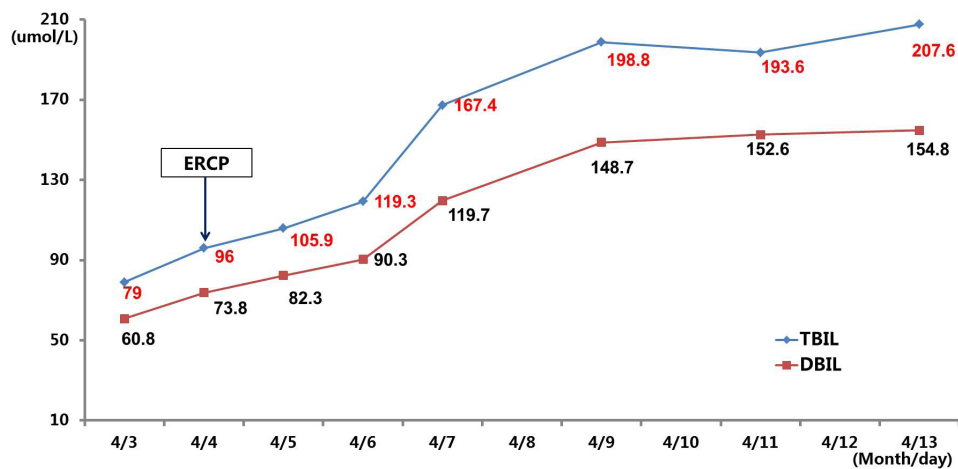


Figure 4. Changes in TBIL and DBIL after ERCP in Hepatobiliary Surgery at this Hospital.

was 186.5 umol/L, DBIL was 140.1 umol/L, alanine amino-transaminase (ALT) was 53.84 U/L (reference range: 9-50 U/L), aspartate amino-transaminase (AST) was 90.5 U/L (reference range: 15-40 U/L), alkaline phosphatase (AKP) was 161.78 U/L (reference range: 45-125 U/L), γ -glutamyl transpeptidase (GGT) was 106.49 U/L (reference range: 10-60 U/L), albumin (ALB) was 25.9 g/L (reference range: 40-55 g/L), prothrombin time (PT) was 21.5 s (reference range: 11.5-14.5 s), INR was 1.8, serum immunoglobulin (IgG) was 24.77 g/L (reference range: 6-16 g/L), and serum immunoglobulin (IgA) was 4.84 g/L (reference range: 0.71-3.35 g/L). He was diagnosed with liver cirrhosis and ACLF. His Child-Pugh score was 13 points. A

consultation with a hematologist also suggested a diagnosis of AIHA. Since the patient had a fever and a potential infection, steroids were ruled out. Adenosine methionine, glutathione, isoglycyrrhizinate, folate tablets, vitamin B12, furosemide, spironolactone, and human albumin were given. In addition, intravenous immune ozone was prescribed as an adjuvant therapy.

On April 24, 2018, laboratory results indicated that ALT was 53.67 U/L, AST was 91.09 U/L, GGT was 96.10 U/L, AKP was 154.58 U/L, TBIL was 121.2 umol/L, DBIL was 101.7 umol/L, ALB was 28.2 g/L, PT was 20.0 s, serum AMY was 82.00 U/L, and serum LIPA was 228.0 U/L. At this time, the patient refused intravenous immune ozone due to the potential

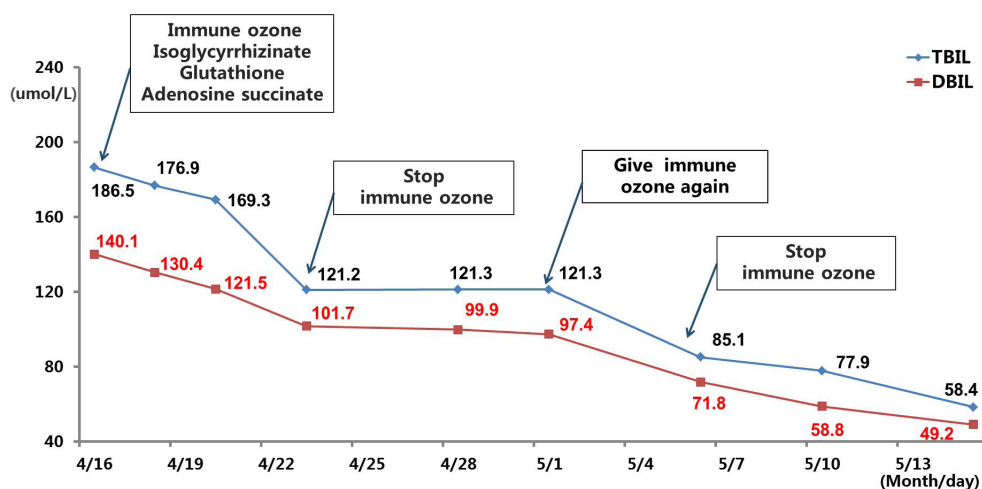


Figure 5. Changes in TBIL and DBIL in Gastroenterology at this Hospital.

invasiveness of the procedure.

On May 1, 2018, laboratory results indicated that ALT was 79.25 U/L, AST was 123.15 U/L, AKP was 154.68 U/L, GGT was 110.65 U/L, TBIL was 121.3 umol/L, DBIL was 97.4 umol/L, ALB was 34.3 g/L, PT was 17.3 s, serum AMY was 107.00 U/L, and serum LIPA was 222.0 U/L. Heeding the advice of his physician, the patient agreed to initiate immune ozone again.

On May 10, 2018, laboratory results indicated that ALT was 64.3 U/L, AST was 94.08 U/L, AKP was 139.03 U/L, GGT was 112.53 U/L, TBIL was 77.9 umol/L, DBIL was 58.8 umol/L, ALB was 34.1 g/L, PT was 16.1 s, serum AMY was 113.00 U/L, and serum LIPA was 244.0 U/L.

On May 16, 2018, laboratory results indicated that ALT was 59.64/L, AST was 92.55 U/L, AKP was 140.23 U/L, GGT was 106.15 U/L, TBIL was 58.4 umol/L, DBIL was 49.2 umol/L, and ALB was 32.5 g/L (Figure 5). Hemolysis tests were performed again. Erythrocyte osmotic fragility (primary dissolution) was 0.45%, erythrocyte osmotic fragility (completely soluble) was 0.40%, and the Coombs test was negative. Ascites was not evident on ultrasound. Thus, the patient was discharged. Oral polyene phosphatidylcholine capsules and silymarin tablets were prescribed.

On May 24, 2018, laboratory tests were performed again. The RBC count was $3.78 \times 10^{12}/L$, Hb was 129 g/L, TBIL was 54.2 umol/L, DBIL was 43.5 umol/L, ALT was 54.31 U/L, AST was 72.21 U/L, AKP was 124.73 U/L, GGT was 82.05 U/L, ALB was 35 g/L, PT was 15.9 s, and INR was 1.28.

On June 27, 2018, laboratory tests were performed again. The RBC count was $3.78 \times 10^{12}/L$, Hb was 138 g/L, TBIL was 29.8 umol/L, DBIL was 16.6 umol/L, ALT was 48.44 U/L, AST was 55.22 U/L, AKP was 138.35 U/L, GGT was 49.14 U/L, and ALB was 32 g/L. The patient is in satisfactory condition without any complaints.

3. Discussion

An interesting aspect of this case is that the TBIL level successively increased to more than 200 umol/L after a common bile duct obstruction was relieved following ERCP. Thus, the causes of jaundice needed to be examined. First, viral hepatitis, autoimmune hepatitis, and tumor markers were negative. Second, since the patient had a prior history of taking medication, drug-related liver injury was suspected. However, the patient had a RUCAM (11) score of 2 points. Thus, drug-induced liver injury was unlikely. Third, since the patient had a high serum IgG antibody titer, IgG4-related cholangitis was suspected. However, this possibility was ruled out based on the diagnostic criteria for IgG4-related cholangitis (12) and the IgG4 level. Fourth, the patient's WBC and GR% gradually increased after ERCP, indicating that the patient might have a biliary infection. Thus, the rise in TBIL and DBIL levels after ERCP might have been caused by a persistent biliary infection. Notably, the patient's inflammatory indices returned to normal after the administration of antibiotics, but his TBIL and DBIL levels continued to rise. Thus, the possibility that TBIL and DBIL increased due to biliary tract infection alone was ruled out. Fifth, CT scans performed at this Hospital suggested a diagnosis of liver cirrhosis. However, the etiology of liver cirrhosis in this patient was unclear. In China, the most common etiological factors are viral hepatitis and alcohol consumption. However, viral hepatitis and a history of alcohol consumption were not evident in this patient. Given his medical history, the possible causes of cirrhosis may have included schistosomiasis, chronic use of drugs, and long-term cholestasis. However, a liver biopsy was not performed, so a definite etiology of liver cirrhosis could not be determined. In addition, the patient said that his schistosomiasis had been cured and that he had stopped taking some drugs. In this patient, repeated episodes of cholestasis may have constituted

the true etiology of liver disease. Sixth, according to the diagnostic criteria for ACLF of the APASL, the patient was diagnosed with ACLF. Seventh, the patient had a gradually decreased level of Hb, an elevated percentage of reticulocytes, and a positive Coombs test, so he was also diagnosed with AIHA (6).

The treatment strategy in this case should also be examined. Intravenous ademetionine, glutathione, isoglycyrrhizinate, and albumin infusions were effective in treating ACLF. Blood transfusions are a potentially risky treatment for AIHA because the presence of autoantibodies may increase the difficulty of cross-matching and the risk of hemolytic transfusion reactions (6). Since the patient had only mild anemia, blood transfusions were not given. In addition, the use of steroids was initially considered in this case. At the time, however, the patient suddenly developed a fever. After balancing the risk and benefits of steroids, the patient and his family members decided to continue following a wait-and-see strategy and they refused steroids.

Another interesting finding is that immune ozone might have alleviated jaundice in this case. Ozone can be dissolved in the aqueous components of plasma, thereby triggering oxidative stress in the body and producing antioxidants, such as superoxide dismutase, glutathione peroxidase, and glutathione S-transferase, catalase, heme oxygenase-1, heat shock protein, and phase II drug-metabolizing enzymes, which are free radical scavengers (13). Treatment with ozone is effective in reducing the levels of anti-erythrocyte and anti-leukocyte antibodies and other antibodies (14). Notably, after discontinuing the immune ozone, the TBIL level plateaued for nearly a week. In contrast, once immune ozone was initiated again, the TBIL level began to decline again (Figure 5).

In conclusion, a patient with ACLF and AIHA responded well to hepato-protective drugs combined with immune ozone. Naturally, the effectiveness and safety of immune ozone in such patients should be further verified in large-scale randomized controlled trials.

References

1. Sarin SK, Kedarisetty CK, Abbas Z, *et al.* Acute-on-chronic liver failure: Consensus recommendations of the Asian Pacific Association for the Study of the Liver

- (APASL) 2014. *Hepatology*. 2014; 48:1765-1776.
2. Liver Failure and Artificial Extracorporeal Liver Support Group, Chinese Society of Infectious Diseases, Chinese Medical Association; Severe Liver Diseases and Artificial Extracorporeal Liver Support Group, Chinese Society of Hepatology, Chinese Medical Association. Diagnostic and treatment guidelines for liver failure (2012 ed.). *Zhonghua Gan Zang Bing Za Zhi*. 2013; 21:177-183. (in Chinese).
3. Liebman HA, Weitz IC. Autoimmune Hemolytic Anemia. *Med Clin North Am*. 2017; 101:351-359.
4. Böttiger LE, Westerholm B. Acquired haemolytic anaemia. I. Incidence and aetiology. *Acta Med Scand*. 1973; 193:223-226.
5. Hill QA. Autoimmune hemolytic anemia. *Hematology*. 2015; 20:553-554.
6. Red Blood Cell Disease (Anemia) Group of the Chinese Society of Hematology of the Chinese Medical Association. Chinese expert consensus on the diagnosis and treatment of autoimmune hemolytic anemia (2017). *Zhonghua Xue Ye Xue Za Zhi*. 2017; 38:265-267. (in Chinese)
7. Smith NL, Wilson AL, Gandhi J, Vatsia S, Khan SA. Ozone therapy: An overview of pharmacodynamics, current research, and clinical utility. *Med Gas Res*. 2017; 7:212-219.
8. Bocci V, Zanardi I, Travagli V. Ozone: A new therapeutic in vascular diseases. *Am J Cardiovasc Drugs*. 2011; 11:73-82.
9. Sagai M, Bocci V. Mechanisms of action involved in ozone therapy: Is healing induced *via* a mild oxidative stress? *Med Gas Res*. 2011; 1:29.
10. Bocci V, ed. *Ozone: A new medical drug*. 2 ed: Springer Netherlands; 2011.
11. Danan G, Teschke R. RUCAM in drug and herb induced liver injury: The update. *Int J Mol Sci*. 2015; 17:pii: E14.
12. Okazaki K, Uchida K, Koyabu M, Miyoshi H, Ikeura T, Takaoka M. IgG4 cholangiopathy: Current concept, diagnosis, and pathogenesis. *J Hepatol*. 2014; 61:690-695.
13. Inal M, Dokumacioglu A, Özcelik E, Ucar O. The effects of ozone therapy and coenzyme Q10 combination on oxidative stress markers in healthy subjects. *Ir J Med Sci*. 2011; 180:703-707.
14. Mandzhgaladze NR, Kharebava ER, Didia TsG, Ardzhevanishvili MD, Gudzhabidze MV, Chigiashvili Ts N. Influence of intravenous ozone treatment on the level of different specificity antibodies. *Georgian Med News*. 2006; 138:93-95.

(Received July 17, 2018; Revised August 11, 2018; Accepted August 17, 2018)

A catastrophic nightmare of the interventional cardiologist: Iatrogenic left main artery dissection and longitudinal stent deformation

Oguz Yıldırım, Murat Gul, Sinan Inci*, Halil Aktaş, Pınar Dogan, Abdulkadir Bozkır, İbrahim İzgü , Recep Karataş

Department of Cardiology, Aksaray Training and Research Hospital, Aksaray University, Aksaray, Turkey.

Summary

Iatrogenic left main coronary artery dissection is a rare but potentially life-threatening complication of invasive coronary procedures. The newer generation drug eluting stents have shown a greater safety and efficacy compared to first generation drug eluting stents. We report a 60-year-old woman with iatrogenic left main coronary artery dissection who failed bailout stenting and underwent coronary artery bypass grafting. The strategy for managing left main coronary artery dissection is variable and depends upon the mechanism, the comorbidities of the patient and degree of hemodynamic stability. Longitudinal stent deformation is a rarely encountered complication but can be seen in complex lesions such as ostial, bifurcation and left main coronary artery lesions. The interventionists must be aware of this complication.

Keywords: Left main coronary artery dissection, longitudinal stent deformation, drug eluting stents

1. Introduction

Iatrogenic left main coronary artery (LMCA) dissection is a rare but potentially life-threatening complication of invasive coronary procedures with a reported incidence of less than 0.1% (1). Timely recognition of the dissection and construction of a proper treatment plan based on the type of the dissection and the clinical status of the patient is needed to overcome this potentially fatal complication. Treatment consists of conservative therapy, salvage percutaneous coronary intervention (PCI) or urgent coronary artery bypass graft (CABG) surgery.

The newer generation drug eluting stents (DES) have shown greater safety and efficacy compared to first generation DES, because of thinner struts, nondurable polymers and coating with better anti-proliferative drugs (2,3). Though, the current stent design of thin struts and cobalt alloy has improved the technical performance

of various stents in terms of tractability, conformability and flexibility; and their poor longitudinal axial strength makes them susceptible to longitudinal stent deformation (LSD) (4). Herein we report a case of iatrogenic LMCA dissection that failed bailout stenting and underwent CABG.

2. Case Report

A 60-year-old female patient with a history of hyperlipidemia and smoking was referred to the cardiology clinic following complaints of chest pain and dyspnea for the last 24 hours. It was also noted that she had been suffering from a cough for the past one week as a result of an upper respiratory tract infection. Physical examination was unremarkable, with BP 136/88 mmHg and HR 95 beats per minute, regular. Electrocardiography revealed sinus rhythm with new T-wave inversions in leads V1-V4. The echocardiogram showed hypokinesia of the inferior, inferior-septal and lateral left ventricular walls with an ejection fraction of 40%. On cannulation of the left coronary artery ostium using a 6 French Judkins Left-4 diagnostic catheter, the left circumflex coronary artery (LCx) was found tortuous and totally occluded (Figure 1A). Therefore,

Released online in J-STAGE as advance publication August 28, 2018.

*Address correspondence to:

Dr. Sinan Inci, Department of Cardiology, Aksaray Training and Research Hospital, Aksaray University, Aksaray 06100, Turkey.

E-mail: doktorsinaninci@gmail.com

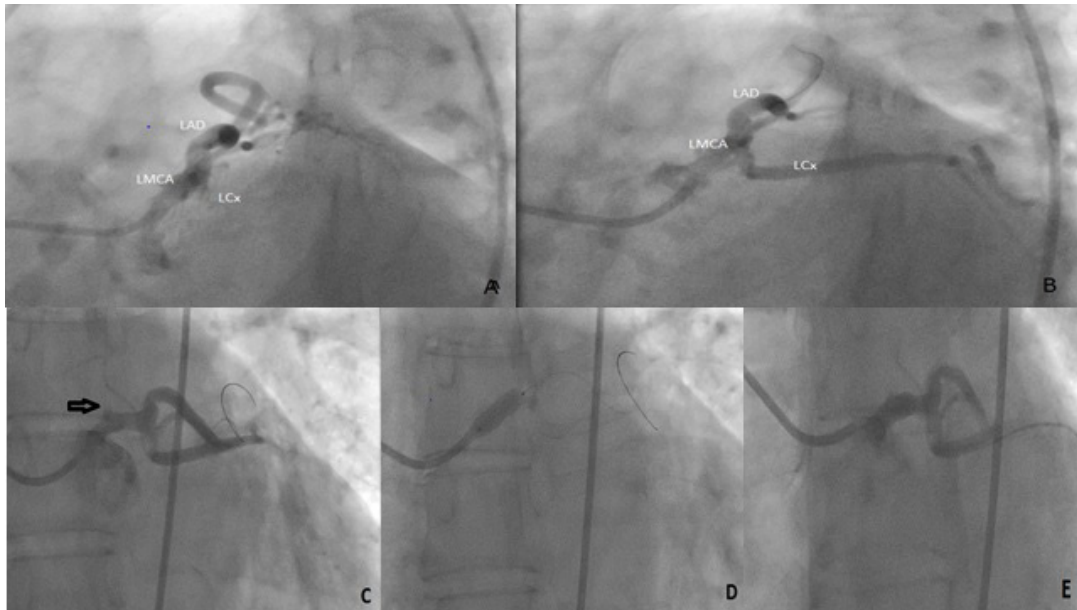


Figure 1. Coronary angiogram images of the lesions during the procedure. (A), Angiogram revealing a completely occluded left circumflex artery; **(B),** Angiogram showing restoration of thrombolysis in myocardial infarction (TIMI) grade 3 flow in the left circumflex artery after stenting; **(C),** Left main coronary Artery dissection (arrow), extending to LCx artery in the antero-posterior caudal view; **(D),** Deployment of a PROMUS 4.5×12 mm stent into left main coronary artery; **(E),** Normal angiographic appearance of the left main coronary artery following stent implantation in left anterior oblique caudal view.

we scheduled to perform PCI to the LCx artery. The LMCA was selectively cannulated without difficulty with a 7 French Judkin's Left-4 guiding catheter (Cordis J&J, Miami, FL). The lesion was crossed by a 0.014 inch soft-tip floppy wire (BMW, Abbott Vascular, Santa Clara, CA, USA) and predilated with 2.0×12 mm compliant balloon at 12 atm. After predilation, a 3.0×28 mm PROMUS (Boston Scientific Co., Natick, MA, USA) DES was uneventfully deployed across the lesion (Figure 1B). Because of stent under expansion at the site of the tight lesion we successfully performed post dilation with use of a 3.5×15 mm noncompliant balloon. Subsequent angiography revealed persistent contrast staining outside the coronary lumen at the site of the LMCA ostium, which was compatible with a type C coronary dissection that extended anterogradely to involve the LCx artery (Figure 1C). The patient was pain free and hemodynamically stable without electrocardiographic evidence of ischemia. A 4.5×12 mm PROMUS (Boston Scientific Co., Natick, MA, USA) DES was deployed at 14 atm into left main coronary artery (Figure 1D). Post dilation was carried out with a 5.0×10 mm noncompliant balloon and final angiography showed complete sealing of the LMCA dissection flap (Figure 1E), but residual dissection flap remained between LMCA and LCx artery. Within same day new intervention was established because of a persistent dissection segment (Figure 2). Left main cannulated with extra-support 7 Fr., 3.5 EBU coronary-guide catheter (Medtronic Inc., Minneapolis, Minnesota) and floppy guidewire was appropriately located in distal position of LCx artery. A decision was taken to attempt to balloon inflations and stent

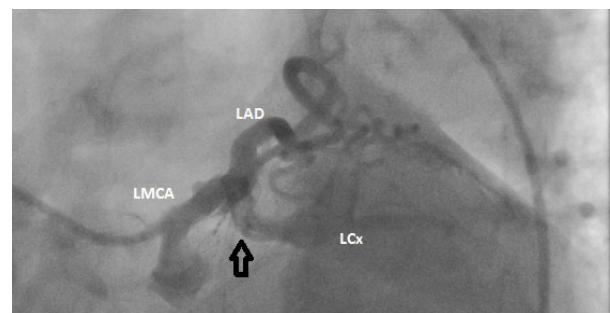


Figure 2. Dissection imaging. Residual dissection between LMCA and LCx viewed in an LAO caudal projection.

deployment at dissected segment, however, multiple attempts failed due to proximal tortuosity of LCx. Deep engagement of guiding catheter compressed the proximal stent struts and resulted in longitudinal stent deformation (Figure 3). Due to deteriorating coronary flow and enlargement of the dissected lumen it was decided to shift the patient for emergency surgical intervention. Successful surgery was performed and patient was discharged from ICU on the 5th postoperative day without any complications.

3. Discussion

Catheter-induced LMCA dissection is a rare but well-recognized life-threatening complication of coronary angiography and angioplasty. Unusual LMCA anatomy or location, presence of LMCA atherosclerosis, operator experience, vigorous hand injection of contrast medium, selection of catheter type (left Amplatz guiding catheters are associated with a higher risk of

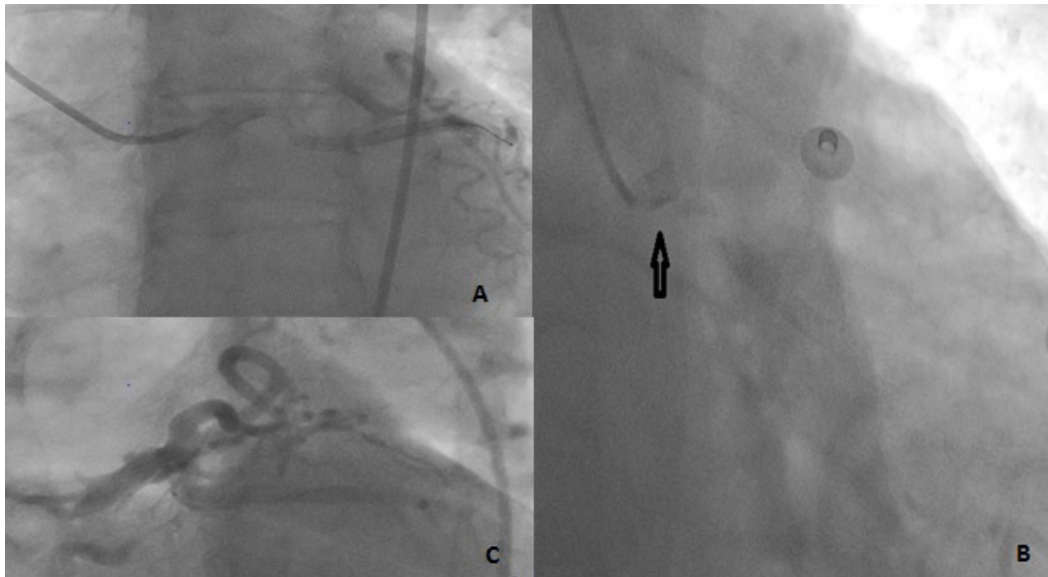


Figure 3. The progression of longitudinal deformation. (A), Noncontrast angiogram after LMCA stent deployment; (B), Longitudinal deformation and shortening of the LMCA stent (black arrow pointing at the proximal deformed edge of the stent); (C), Angiogram revealed progressive enlargement of the dissected lumen and deteriorating coronary flow.

dissection), inappropriate positioning of the catheter in co-axial alignment with LMCA and subintimal passage of the guidewire (especially stiffer and less manageable guide wires) have all been associated with an increased risk of iatrogenic LMCA dissection (5-7). Iatrogenic LMCA dissection is twice as likely to occur during coronary intervention compared to diagnostic angiography (8) and deep engagement of guiding catheters while the angioplasty balloon is withdrawn is often suggested to be responsible for iatrogenic LMCA dissection (1).

LSD has been described as longitudinal distortion or shortening of the stent in the longitudinal axis (4). The literature states that Promus Element stent has commonly been associated with LSD (9). LSD is more frequent in LMCA, ostial, bifurcation and complex lesions, in terms of procedural characteristics, LSD is related to the use of extra-support guiding catheters, extra-support guidewires, use of more than one stent and post-dilatation, and lower stent inflation pressure (10). The treatment of LSD includes dilatation of a deformed segment with appropriate sized non-compliant balloon and if required, another stent for optimal end results. Although rare, the LSD can lead to potential complications such as predisposing to stent thrombosis (4). In rare cases, percutaneous management of stent deformation might become difficult, such that, surgery becomes necessary in such situations.

The strategy for managing of LMCA dissection is variable and depends upon the mechanism, the comorbidities of the patient and degree of hemodynamic stability. Hemodynamically unstable patients are most likely to undergo percutaneous coronary intervention (PCI), because PCI (bailout stenting) of LMCA can be performed rapidly shortly after iatrogenic LMCA

dissection occurred and has high technical success. Coronary artery bypass grafting (CABG) is particularly valuable in a hemodynamically stable patient with extensive iatrogenic LMCA dissection (antegrade or retrograde extension into the aortic root) and multivessel disease.

In conclusion, we hereby report a case of iatrogenic LMCA dissection in which bailout stenting failed due to LSD. LSD is a rarely encountered complication but can be seen in complex lesions such as ostial, bifurcation and LMCA lesions. To prevent LSD, aggressive catheter manipulation and deep engagement of catheter during withdrawal of stent balloons, post-dilatation balloons or adjunctive imaging devices should be avoided. The interventionists must be aware of this complication and must recognize and manage it carefully.

References

1. Awadalla H, Sabet S, El Sebaie A, Rosales O, Smalling R. Catheter-induced left main dissection incidence, predisposition and therapeutic strategies experience from two sides of the hemisphere. *J Invasive Cardiol.* 2005; 17:233-236.
2. Kedhi E, Gomes ME, Lagerqvist B, Smith JG, Omerovic E, James S, Harnek J, Olivecrona GK. Clinical impact of second-generation everolimus-eluting stent compared with first-generation drug-eluting stents in diabetes mellitus patients: Insights from a nationwide coronary intervention register. *JACC Cardiovasc Interv.* 2012; 5:1141-1149.
3. Planer D, Smits PC, Kereiakes DJ, Kedhi E, Fahy M, Xu K, Serruys PW, Stone GW. Comparison of everolimus- and paclitaxel-eluting stents in patients with acute and stable coronary syndromes: Pooled results from the SPIRIT (a clinical evaluation of the XIENCE V everolimus eluting coronary stent system)

- and COMPARE (a trial of everolimus-eluting stents and paclitaxel-eluting stents for coronary revascularization in daily practice) trials. *JACC Cardiovasc Interv.* 2011; 4:1104-1115.
4. Hanratty CG, Walsh SJ. Longitudinal compression: A "new" complication with modern coronary stent platforms—time to think beyond deliverability? *EuroIntervention.* 2011; 7:872-877.
 5. Onsea K, Kayaert P, Desmet W, Dubois CL. Iatrogenic left main coronary artery dissection. *Neth Heart J.* 2011; 19:192-195.
 6. Kovac JD, de Bono DP. Cardiac catheter complications related to left main stem disease. *Heart.* 1996; 76:76-78.
 7. Slack JD, Pinkerton CA, VanTassel JW, Orr CM. Left main coronary artery dissection during percutaneous transluminal coronary angioplasty. *Cathet Cardiovasc Diagn.* 1986; 12:255-260.
 8. Eshtehardi P, Adorjan P, Togni M, Tevaearai H, Vogel R, Seiler C, Meier B, Windecker S, Carrel T, Wenaweser P, Cook S. Iatrogenic left main coronary artery dissection: Incidence, classification, management, and long-term follow-up. *Am Heart J.* 2010; 159:1147-1153.
 9. von Birgelen C, Sen H, Lam MK, *et al.* Third-generation zotarolimus-eluting and everolimus-eluting stents in all-comer patients requiring a percutaneous coronary intervention (DUTCH PEERS): A randomised, singleblind, multicentre, non-inferiority trial. *Lancet.* 2014; 383:413-423.
 10. Guler A, Guler Y, Acar E, Aung SM, Efe SC, Kilicgedik A, Karabay CY, Barutcu S, Tigen MK, Pala S, İzgi A, Esen AM, Kirma C. Clinical, angiographic and procedural characteristics of longitudinal stent deformation. *Int J Cardiovasc Imaging.* 2016; 32:1163-1170.

(Received August 1, 2018; Revised August 13, 2018; Accepted August 19, 2018)

Guide for Authors

1. Scope of Articles

Intractable & Rare Diseases Research is an international peer-reviewed journal. Intractable & Rare Diseases Research devotes to publishing the latest and most significant research in intractable and rare diseases. Articles cover all aspects of intractable and rare diseases research such as molecular biology, genetics, clinical diagnosis, prevention and treatment, epidemiology, health economics, health management, medical care system, and social science in order to encourage cooperation and exchange among scientists and clinical researchers.

2. Submission Types

Original Articles should be well-documented, novel, and significant to the field as a whole. An Original Article should be arranged into the following sections: Title page, Abstract, Introduction, Materials and Methods, Results, Discussion, Acknowledgments, and References. Original articles should not exceed 5,000 words in length (excluding references) and should be limited to a maximum of 50 references. Articles may contain a maximum of 10 figures and/or tables.

Brief Reports definitively documenting either experimental results or informative clinical observations will be considered for publication in this category. Brief Reports are not intended for publication of incomplete or preliminary findings. Brief Reports should not exceed 3,000 words in length (excluding references) and should be limited to a maximum of 4 figures and/or tables and 30 references. A Brief Report contains the same sections as an Original Article, but the Results and Discussion sections should be combined.

Reviews should present a full and up-to-date account of recent developments within an area of research. Normally, reviews should not exceed 8,000 words in length (excluding references) and should be limited to a maximum of 100 references. Mini reviews are also accepted.

Policy Forum articles discuss research and policy issues in areas related to life science such as public health, the medical care system, and social science and may address governmental issues at district, national, and international levels of discourse. Policy Forum articles should not exceed 2,000 words in length (excluding references).

Case Reports should be detailed reports of the symptoms, signs, diagnosis, treatment, and follow-up of an individual patient. Case reports may contain a demographic profile of the patient but usually describe an unusual

or novel occurrence. Unreported or unusual side effects or adverse interactions involving medications will also be considered. Case Reports should not exceed 3,000 words in length (excluding references).

News articles should report the latest events in health sciences and medical research from around the world. News should not exceed 500 words in length.

Letters should present considered opinions in response to articles published in Intractable & Rare Diseases Research in the last 6 months or issues of general interest. Letters should not exceed 800 words in length and may contain a maximum of 10 references.

3. Editorial Policies

Ethics: Intractable & Rare Diseases Research requires that authors of reports of investigations in humans or animals indicate that those studies were formally approved by a relevant ethics committee or review board.

Conflict of Interest: All authors are required to disclose any actual or potential conflict of interest including financial interests or relationships with other people or organizations that might raise questions of bias in the work reported. If no conflict of interest exists for each author, please state "There is no conflict of interest to disclose".

Submission Declaration: When a manuscript is considered for submission to Intractable & Rare Diseases Research, the authors should confirm that 1) no part of this manuscript is currently under consideration for publication elsewhere; 2) this manuscript does not contain the same information in whole or in part as manuscripts that have been published, accepted, or are under review elsewhere, except in the form of an abstract, a letter to the editor, or part of a published lecture or academic thesis; 3) authorization for publication has been obtained from the authors' employer or institution; and 4) all contributing authors have agreed to submit this manuscript.

Cover Letter: The manuscript must be accompanied by a cover letter signed by the corresponding author on behalf of all authors. The letter should indicate the basic findings of the work and their significance. The letter should also include a statement affirming that all authors concur with the submission and that the material submitted for publication has not been published previously or is not under consideration for publication elsewhere. The cover letter should be submitted in PDF format. For example of Cover Letter, please visit <http://www.irdrjournal.com/downcentre.php> (Download Centre).

Copyright: A signed JOURNAL PUBLISHING AGREEMENT (JPA) form must be provided by post, fax, or as a scanned file before acceptance of the article. Only forms with a hand-written signature are accepted. This copyright will ensure the widest possible dissemination of information.

A form facilitating transfer of copyright can be downloaded by clicking the appropriate link and can be returned to the e-mail address or fax number noted on the form (Please visit [Download Centre](#)). Please note that your manuscript will not proceed to the next step in publication until the JPA Form is received. In addition, if excerpts from other copyrighted works are included, the author(s) must obtain written permission from the copyright owners and credit the source(s) in the article.

Suggested Reviewers: A list of up to 3 reviewers who are qualified to assess the scientific merit of the study is welcomed. Reviewer information including names, affiliations, addresses, and e-mail should be provided at the same time the manuscript is submitted online. Please do not suggest reviewers with known conflicts of interest, including participants or anyone with a stake in the proposed research; anyone from the same institution; former students, advisors, or research collaborators (within the last three years); or close personal contacts. Please note that the Editor-in-Chief may accept one or more of the proposed reviewers or may request a review by other qualified persons.

Language Editing: Manuscripts prepared by authors whose native language is not English should have their work proofread by a native English speaker before submission. If not, this might delay the publication of your manuscript in Intractable & Rare Diseases Research.

The Editing Support Organization can provide English proofreading, Japanese-English translation, and Chinese-English translation services to authors who want to publish in Intractable & Rare Diseases Research and need assistance before submitting a manuscript. Authors can visit this organization directly at <http://www.iacmhr.com/iac-eso/support.php?lang=en>. IAC-ESO was established to facilitate manuscript preparation by researchers whose native language is not English and to help edit works intended for international academic journals.

4. Manuscript Preparation

Manuscripts should be written in clear, grammatically correct English and submitted as a Microsoft Word file in a single-column format. Manuscripts must be paginated and typed in 12-point Times New Roman font with 24-point line spacing. Please do not embed figures in the text. Abbreviations should be used as little as possible and should be explained at first mention unless the term is a well-known abbreviation (e.g. DNA). Single words should not be abbreviated.

Title page: The title page must include 1) the title of the paper (Please note the title should be short, informative, and contain the major key words); 2) full name(s) and affiliation(s) of the author(s), 3) abbreviated names of the author(s), 4) full name, mailing address, telephone/fax numbers, and e-mail address of the corresponding author; and 5) conflicts of interest (if you have an actual or potential conflict of interest to disclose, it must be included as a footnote on the title page of the

manuscript; if no conflict of interest exists for each author, please state "There is no conflict of interest to disclose"). Please visit [Download Centre](#) and refer to the title page of the manuscript sample.

Abstract: The abstract should briefly state the purpose of the study, methods, main findings, and conclusions. For article types including Original Article, Brief Report, Review, Policy Forum, and Case Report, a one-paragraph abstract consisting of no more than 250 words must be included in the manuscript. For News and Letters, a brief summary of main content in 150 words or fewer should be included in the manuscript. Abbreviations must be kept to a minimum and non-standard abbreviations explained in brackets at first mention. References should be avoided in the abstract. Key words or phrases that do not occur in the title should be included in the Abstract page.

Introduction: The introduction should be a concise statement of the basis for the study and its scientific context.

Materials and Methods: The description should be brief but with sufficient detail to enable others to reproduce the experiments. Procedures that have been published previously should not be described in detail but appropriate references should simply be cited. Only new and significant modifications of previously published procedures require complete description. Names of products and manufacturers with their locations (city and state/country) should be given and sources of animals and cell lines should always be indicated. All clinical investigations must have been conducted in accordance with Declaration of Helsinki principles. All human and animal studies must have been approved by the appropriate institutional review board(s) and a specific declaration of approval must be made within this section.

Results: The description of the experimental results should be succinct but in sufficient detail to allow the experiments to be analyzed and interpreted by an independent reader. If necessary, subheadings may be used for an orderly presentation. All figures and tables must be referred to in the text.

Discussion: The data should be interpreted concisely without repeating material already presented in the Results section. Speculation is permissible, but it must be well-founded, and discussion of the wider implications of the findings is encouraged. Conclusions derived from the study should be included in this section.

Acknowledgments: All funding sources should be credited in the Acknowledgments section. In addition, people who contributed to the work but who do not meet the criteria for authors should be listed along with their contributions.

References: References should be numbered in the order in which they appear in the text. Citing of unpublished results, personal

communications, conference abstracts, and theses in the reference list is not recommended but these sources may be mentioned in the text. In the reference list, cite the names of all authors when there are fifteen or fewer authors; if there are sixteen or more authors, list the first three followed by *et al.* Names of journals should be abbreviated in the style used in PubMed. Authors are responsible for the accuracy of the references. Examples are given below:

Example 1 (Sample journal reference):
Inagaki Y, Tang W, Zhang L, Du GH, Xu WF, Kokudo N. Novel aminopeptidase N (APN/CD13) inhibitor 24F can suppress invasion of hepatocellular carcinoma cells as well as angiogenesis. *Biosci Trends*. 2010; 4:56-60.

Example 2 (Sample journal reference with more than 15 authors):
Darby S, Hill D, Auvinen A, *et al.* Radon in homes and risk of lung cancer: Collaborative analysis of individual data from 13 European case-control studies. *BMJ*. 2005; 330:223.

Example 3 (Sample book reference):
Shalev AY. Post-traumatic stress disorder: Diagnosis, history and life course. In: *Post-traumatic Stress Disorder, Diagnosis, Management and Treatment* (Nutt DJ, Davidson JR, Zohar J, eds.). Martin Dunitz, London, UK, 2000; pp. 1-15.

Example 4 (Sample web page reference):
World Health Organization. The World Health Report 2008 – primary health care: Now more than ever. http://www.who.int/whr/2008/whr08_en.pdf (accessed September 23, 2010).

Tables: All tables should be prepared in Microsoft Word or Excel and should be arranged at the end of the manuscript after the References section. Please note that tables should not in image format. All tables should have a concise title and should be numbered consecutively with Arabic numerals. If necessary, additional information should be given below the table.

Figure Legend: The figure legend should be typed on a separate page of the main manuscript and should include a short title and explanation. The legend should be concise but comprehensive and should be understood without referring to the text. Symbols used in figures must be explained.

Figure Preparation: All figures should be clear and cited in numerical order in the text. Figures must fit a one- or two-column format on the journal page: 8.3 cm (3.3 in.) wide for a single column, 17.3 cm (6.8 in.) wide for a double column; maximum height: 24.0 cm (9.5 in.). Please make sure that artwork files are in an acceptable format (TIFF or JPEG) at minimum resolution (600 dpi for illustrations, graphs, and annotated artwork, and 300 dpi for micrographs and photographs). Please provide all figures as separate files. Please note that low-resolution images are one of the leading causes of article resubmission and schedule delays. All color figures will be reproduced in full color in the online edition of the journal at no cost to authors.

Units and Symbols: Units and symbols conforming to the International System of Units (SI) should be used for physicochemical quantities. Solidus notation (*e.g.* mg/kg, mg/mL, mol/mm²/min) should be used. Please refer to the SI Guide www.bipm.org/en/si/ for standard units.

Supplemental data: Supplemental data might be useful for supporting and enhancing your scientific research and Intractable & Rare Diseases Research accepts the submission of these materials which will be only published online alongside the electronic version of your article. Supplemental files (figures, tables, and other text materials) should be prepared according to the above guidelines, numbered in Arabic numerals (*e.g.*, Figure S1, Figure S2, and Table S1, Table S2) and referred to in the text. All figures and tables should have titles and legends. All figure legends, tables and supplemental text materials should be placed at the end of the paper. Please note all of these supplemental data should be provided at the time of initial submission and note that the editors reserve the right to limit the size and length of Supplemental Data.

5. Submission Checklist

The Submission Checklist will be useful during the final checking of a manuscript prior to sending it to Intractable & Rare Diseases Research for review. Please visit [Download Centre](#) and download the Submission Checklist file.

6. Online submission

Manuscripts should be submitted to Intractable & Rare Diseases Research online at <http://www.irdjournal.com>. The manuscript file should be smaller than 5 MB in size. If for any reason you are unable to submit a file online, please contact the Editorial Office by e-mail at office@irdjournal.com

7. Accepted manuscripts

Proofs: Galley proofs in PDF format will be sent to the corresponding author *via* e-mail. Corrections must be returned to the editor (office@irdjournal.com) within 3 working days.

Offprints: Authors will be provided with electronic offprints of their article. Paper offprints can be ordered at prices quoted on the order form that accompanies the proofs.

Page Charge: No page charges will be levied to author for the publication of their article except for reprints.

(As of February 2013)

Editorial and Head Office:

Pearl City Koishikawa 603
2-4-5 Kasuga, Bunkyo-ku
Tokyo 112-0003, Japan
Tel: +81-3-5840-9968
Fax: +81-3-5840-9969
E-mail: office@irdjournal.com

IRD R

Intractable & Rare Diseases Research



JOURNAL PUBLISHING AGREEMENT (JPA)

Manuscript No.:

Title:

Corresponding Author:

The International Advancement Center for Medicine & Health Research Co., Ltd. (IACMHR Co., Ltd.) is pleased to accept the above article for publication in Intractable & Rare Diseases Research. The International Research and Cooperation Association for Bio & Socio-Sciences Advancement (IRCA-BSSA) reserves all rights to the published article. Your written acceptance of this JOURNAL PUBLISHING AGREEMENT is required before the article can be published. Please read this form carefully and sign it if you agree to its terms. The signed JOURNAL PUBLISHING AGREEMENT should be sent to the Intractable & Rare Diseases Research office (Pearl City Koishikawa 603, 2-4-5 Kasuga, Bunkyo-ku, Tokyo 112-0003, Japan; E-mail: office@irdrjournal.com; Tel: +81-3-5840-9968; Fax: +81-3-5840-9969).

1. Authorship Criteria

As the corresponding author, I certify on behalf of all of the authors that:

- 1) The article is an original work and does not involve fraud, fabrication, or plagiarism.
- 2) The article has not been published previously and is not currently under consideration for publication elsewhere. If accepted by Intractable & Rare Diseases Research, the article will not be submitted for publication to any other journal.
- 3) The article contains no libelous or other unlawful statements and does not contain any materials that infringes upon individual privacy or proprietary rights or any statutory copyright.
- 4) I have obtained written permission from copyright owners for any excerpts from copyrighted works that are included and have credited the sources in my article.
- 5) All authors have made significant contributions to the study including the conception and design of this work, the analysis of the data, and the writing of the manuscript.
- 6) All authors have reviewed this manuscript and take responsibility for its content and approve its publication.
- 7) I have informed all of the authors of the terms of this publishing agreement and I am signing on their behalf as their agent.

2. Copyright Transfer Agreement

I hereby assign and transfer to IACMHR Co., Ltd. all exclusive rights of copyright ownership to the above work in the journal Intractable & Rare Diseases Research, including but not limited to the right 1) to publish, republish, derivate, distribute, transmit, sell, and otherwise use the work and other related material worldwide, in whole or in part, in all languages, in electronic, printed, or any other forms of media now known or hereafter developed and the right 2) to authorize or license third parties to do any of the above.

I understand that these exclusive rights will become the property of IACMHR Co., Ltd., from the date the article is accepted for publication in the journal Intractable & Rare Diseases Research. I also understand that IACMHR Co., Ltd. as a copyright owner has sole authority to license and permit reproductions of the article.

I understand that except for copyright, other proprietary rights related to the Work (e.g. patent or other rights to any process or procedure) shall be retained by the authors. To reproduce any text, figures, tables, or illustrations from this Work in future works of their own, the authors must obtain written permission from IACMHR Co., Ltd.; such permission cannot be unreasonably withheld by IACMHR Co., Ltd.

3. Conflict of Interest Disclosure

I confirm that all funding sources supporting the work and all institutions or people who contributed to the work but who do not meet the criteria for authors are acknowledged. I also confirm that all commercial affiliations, stock ownership, equity interests, or patent-licensing arrangements that could be considered to pose a financial conflict of interest in connection with the article have been disclosed.

Corresponding Author's Name (Signature):

Date:

Intractable & Rare Diseases Research (www.irdrjournal.com)

Pearl City Koishikawa 603, 2-4-5 Kasuga, Bunkyo-ku, Tokyo 112-0003, Japan; E-mail: office@irdrjournal.com; Tel: +81-3-5840-9968; Fax: +81-3-5840-9969

