

ISSN 2186-3644 Online ISSN 2186-361X

# IRDR

## Intractable & Rare Diseases Research

Volume 8, Number 1  
February, 2019



[www.irdrjournal.com](http://www.irdrjournal.com)



# IRDR

## Intractable & Rare Diseases Research



ISSN: 2186-3644  
Online ISSN: 2186-361X  
CODEN: IRDRA3  
Issues/Year: 4  
Language: English  
Publisher: IACMHR Co., Ltd.

**Intractable & Rare Diseases Research** is one of a series of peer-reviewed journals of the International Research and Cooperation Association for Bio & Socio-Sciences Advancement (IRCA-BSSA) Group and is published quarterly by the International Advancement Center for Medicine & Health Research Co., Ltd. (IACMHR Co., Ltd.) and supported by the IRCA-BSSA, Shandong Academy of Medical Sciences, and Shandong Rare Disease Association.


**Intractable & Rare Diseases Research** devotes to publishing the latest and most significant research in intractable and rare diseases. Articles cover all aspects of intractable and rare diseases research such as molecular biology, genetics, clinical diagnosis, prevention and treatment, epidemiology, health economics, health management, medical care system, and social science in order to encourage cooperation and exchange among scientists and clinical researchers.

**Intractable & Rare Diseases Research** publishes Original Articles, Brief Reports, Reviews, Policy Forum articles, Case Reports, News, and Letters on all aspects of the field of intractable and rare diseases research. All contributions should seek to promote international collaboration.


### IRCA-BSSA Group Journals



ISSN: 1881-7815  
Online ISSN: 1881-7823  
CODEN: BTIRCZ  
Issues/Year: 6  
Language: English  
Publisher: IACMHR Co., Ltd.  
[www.biosciencetrends.com](http://www.biosciencetrends.com)



ISSN: 1881-7831  
Online ISSN: 1881-784X  
CODEN: DDTRBX  
Issues/Year: 6  
Language: English  
Publisher: IACMHR Co., Ltd.  
[www.ddtjournal.com](http://www.ddtjournal.com)



ISSN: 2186-3644  
Online ISSN: 2186-361X  
CODEN: IRDRA3  
Issues/Year: 4  
Language: English  
Publisher: IACMHR Co., Ltd.  
[www.irdrjournal.com](http://www.irdrjournal.com)

# Intractable & Rare Diseases Research

## Editorial and Head Office

Pearl City Koishikawa 603, 2-4-5 Kasuga, Bunkyo-ku,  
Tokyo 112-0003, Japan

Tel: +81-3-5840-9968, Fax: +81-3-5840-9969

E-mail: office@irdrjournal.com

URL: www.irdrjournal.com

## Editorial Board

### Editor-in-Chief:

Takashi KARAKO  
*National Center for Global Health and Medicine, Tokyo, Japan*

### Executive Editor:

Peipei SONG  
*Nihon University School of Medicine, Tokyo, Japan*

### Co-Editors-in-Chief:

Jinxiang HAN  
*Shandong Academy of Medical Sciences, Jinan, China*

Jose-Alain SAHEL  
*Pierre and Marie Curie University, Paris, France*

### Editorial Board Members

Tetsuya ASAKAWA <i>(Hamamatsu, Japan)</i>	Guosheng JIANG <i>(Jinan, China)</i>	Phillips ROBBINS <i>(Boston, MA, USA)</i>	Xianqin ZHANG <i>(Wuhan, China)</i>
Karen BRØNDUM-NIELSEN <i>(Glostrup, Denmark)</i>	Si JIN <i>(Wuhan, China)</i>	Hironobu SASANO <i>(Sendai, Japan)</i>	Yanjun ZHANG <i>(Cincinnati, OH, USA)</i>
Yazhou CUI <i>(Jinan, China)</i>	Yasuhiro KANATANI <i>(Saitama, Japan)</i>	Shinichi SATO <i>(Tokyo, Japan)</i>	Yumin ZHANG <i>(Bethesda, MD, USA)</i>
John DART <i>(Crowthorne, UK)</i>	Mureo KASAHARA <i>(Tokyo, Japan)</i>	Yasuyuki SETO <i>(Tokyo, Japan)</i>	Yuesi ZHONG <i>(Guangzhou, China)</i>
Masahito EBINA <i>(Sendai, Japan)</i>	Jun-ichi KIRA <i>(Fukuoka, Japan)</i>	Jian SUN <i>(Guangzhou, China)</i>	Jiayi ZHOU <i>(Boston, MA, USA)</i>
Clodoveo FERRI <i>(Modena, Italy)</i>	Toshiro KONISHI <i>(Tokyo, Japan)</i>	Qingfang SUN <i>(Shanghai, China)</i>	Wenxia ZHOU <i>(Beijing, China)</i>
Toshiyuki FUKAO <i>(Gifu, Japan)</i>	Masato KUSUNOKI <i>(Mie, Japan)</i>	ZhiPeng SUN <i>(Beijing, China)</i>	<b>Web Editor:</b>
Ruoyan GAI <i>(Jinan, China)</i>	Shixiu LIAO <i>(Zhengzhou, China)</i>	Samia TEMTAMY <i>(Cairo, Egypt)</i>	Yu CHEN <i>(Tokyo, Japan)</i>
Shiwei GONG <i>(Wuhan, China)</i>	Zhibin LIN <i>(Beijing, China)</i>	Yisha TONG <i>(Heidelberg, Australia)</i>	<b>Proofreaders:</b>
Jeff GUO <i>(Cincinnati, OH, USA)</i>	Reymundo LOZANO <i>(New York, NY, USA)</i>	Hisanori UMEHARA <i>(Ishikawa, Japan)</i>	Curtis BENTLEY <i>(Roswell, GA, USA)</i>
Toshiro HARA <i>(Fukuoka, Japan)</i>	Kuansheng MA <i>(Chongqing, China)</i>	Chenglin WANG <i>(Shenzhen, China)</i>	Thomas R. LEBON <i>(Los Angeles, CA, USA)</i>
Lihui HUANG <i>(Beijing, China)</i>	Katia MARAZOVA <i>(Paris, France)</i>	Haibo WANG <i>(Hong Kong, China)</i>	<b>Editorial and Head Office:</b>
Reiko HORIKAWA <i>(Tokyo, Japan)</i>	Chikao MORIMOTO <i>(Tokyo, Japan)</i>	Huijun WANG <i>(Shanghai, China)</i>	Pearl City Koishikawa 603
Takahiko HORIUCHI <i>(Fukuoka, Japan)</i>	Noboru MOTOMURA <i>(Tokyo, Japan)</i>	Qinghe XING <i>(Shanghai, China)</i>	2-4-5 Kasuga, Bunkyo-ku
Yoshinori INAGAKI <i>(Tokyo, Japan)</i>	Masanori NAKAGAWA <i>(Kyoto, Japan)</i>	Zhenggang XIONG <i>(New Orleans, LA, USA)</i>	Tokyo 112-0003, Japan
Masaru IWASAKI <i>(Yamanashi, Japan)</i>	Jun NAKAJIMA <i>(Tokyo, Japan)</i>	Toshiyuki YAMAMOTO <i>(Tokyo, Japan)</i>	Tel: +81-3-5840-9968
Baoan JI <i>(Houston, TX, USA)</i>	Takashi NAKAJIMA <i>(Kashiwazaki, Japan)</i>	Huijun YUAN <i>(Beijing, China)</i>	Fax: +81-3-5840-9969
Xunming JI <i>(Beijing, China)</i>	Ming QIU <i>(Shanghai, China)</i>	Wenhong ZHANG <i>(Shanghai, China)</i>	E-mail: office@irdrjournal.com

*(As of February 2019)*

**Review**

---

- 1 - 8      **Nipah virus disease: A rare and intractable disease.**  
*Sayantan Banerjee, Nitin Gupta, Parul Kodan, Ankit Mittal, Yogiraj Ray, Neeraj Nischal, Manish Soneja, Ashutosh Biswas, Naveet Wig*
- 9 - 13      **Management strategies in facioscapulohumeral muscular dystrophy.**  
*Junren Lu, Zhenjun Yao, Yi Yang, Chi Zhang, Jian Zhang, Ying Zhang*

**Brief Report**

---

- 14 - 19      **Novel missense mutation affecting the LIM-A domain of LMX1B in a family with Nail-Patella syndrome.**  
*Felix Claverie-Martin, Amelia Trindade, Noriela C. Garcia-Gonzalez, Alicia Callejon Callejon*
- 20 - 23      **The expression of EpCAM in extramammary Paget's disease.**  
*Saori Yamada-Kanazawa, Yukino Tasaki, Ikko Kajihara, Ryoko Sakamoto, Saki Maeda-Otsuka, Hironobu Ihn*
- 24 - 28      **Propranolol and ascorbic acid in control of fibrodysplasia ossificans progressiva flare-ups due to accidental falls.**  
*Durval Batista Palhares, Deborah Ribeiro Nascimento, Marilene Garcia Palhares, Suzana Lopes Bomfim Balaniuc, Liane de Rosso Giuliani, Paula Cristhina Niz Xavier, José Mauro Goulart Brum, Fabiana Alves, Francisco Oliveira Vieira, Elaine Maria Souza-Fagundes, Adam Underwood, Amy Milsted, Robson Augusto Souza Santos, Almir Sousa Martins*

**Case Report**

---

- 29 - 35      **Retroperitoneal fibrosis associated with orbital pseudotumor without evidence of IgG4: A case report with review of literature.**  
*María-Teresa Pérez-Sanz, Eva Cervilla-Muñoz, Jaime Alonso-Muñoz, Almudena Marcelo-Ayala, María-Dolores Pulfer, Francisco Galeano-Valle*
- 36 - 42      **Hydatid cyst of gall bladder masquerading as carcinoma: A rare case report with review of literature**  
*Garima Jain, Chandan Kumar, Pankaj Meena, Angel Rajan Singh, Virendra Kumar, Sunil Kumar, Pranay Tanwar*
- 43 - 47      **Guillain-Barré syndrome in a patient of acute Hepatitis E virus infection associated with genotype 1: Case report and literature review.**  
*Manish Chandra Choudhary, Vijeta Bajpai, Lovkesh Anand, Ekta Gupta*

- 48 - 51**      **West Nile virus encephalitis in a young immunocompetent female in Omaha Nebraska.**  
*Azka Latif, Vikas Kapoor, Erin Simmons, Jai Parekh, Venkata Andukuri*
- 52 - 55**      **Leber's hereditary optic neuropathy: Severe vascular pathology in a severe primary mutation.**  
*Samuel Asanad, Elana Meer, Jack J. Tian, Michele Fantini, Marco Nassisi, Alfredo A. Sadun*
- 56 - 59**      **Anesthesia management of arthroscopic ankle arthrodesis for a hemophilia patient after living-donor liver transplantation.**  
*Reiko Shibata, Ryo Orii, Rie Ako*
- 60 - 66**      **Budd-Chiari Syndrome in Behçet's Disease successfully managed with immunosuppressive and anticoagulant therapy: A case report and literature review.**  
*Christian Mario Amodeo Oblitas, Francisco Galeano-Valle, Neera Toledo-Samaniego, Blanca Pinilla-Llorente, Jorge Del Toro-Cervera, Arturo Álvarez-Luque, Alejandra García-García, Pablo Demelo-Rodriguez*
- 67 - 71**      **A novel mutation in CACNA1A gene in a Saudi female with episodic ataxia type 2 with no response to acetazolamide or 4-aminopyridine.**  
*Hussein Algahtani, Bader Shirah, Raghad Algahtani, Mohammad H. Al-Qahtani, Angham Abdulrahman Abdulkareem, Muhammad Imran Naseer*
- 72 - 77**      **Partial trisomy 9 (9pter->9q22.1) and partial monosomy 14 (14pter->14q11.2) due to paternal translocation t(9;14)(q22.1;q11.2) in a case of Dysmorphic features.**  
*Somprakash Dhangar, Seema Korgaonkar, Babu Rao Vundinti*

## **Letter**

---

- 78 - 79**      **Network established to collaborate on diagnosis and treatment of rare diseases in China: A strategic alliance backed by tiered healthcare is the key to the future**  
*Qianli Ren, Jianbin Wang*

## **Guide for Authors**

---

## **Copyright**

---

## Nipah virus disease: A rare and intractable disease

Sayantana Banerjee, Nitin Gupta, Parul Kodan, Ankit Mittal, Yogiraj Ray, Neeraj Nischal, Manish Soneja\*, Ashutosh Biswas, Naveet Wig

Department of Medicine, All India Institute of Medical Sciences, New Delhi, India.

### Summary

**Nipah virus, an enveloped ribonucleic acid virus, has been a major cause of encephalitis outbreaks with high mortality, primarily in the Indo-Bangladesh regions. Except for the first outbreak in Malaysia-Singapore, which was related to contact with pigs and the outbreak in Philippines associated with horse slaughter, most other outbreaks have affected the Indo-Bangladesh regions. The Indo-Bangladesh outbreaks were associated with consumption of raw date palm sap contaminated by fruit bats and had a very high secondary attack rate. The patient usually presents with fever, encephalitis and/or respiratory involvement with or without thrombocytopenia, leukopenia and transaminitis. Diagnosis can be confirmed by isolation and nucleic acid amplification in the acute phase or antibody detection during the convalescent phase. Treatment is mostly limited to supportive care and syndromic management of acute encephalitis syndrome. Ribavirin, m102.4 monoclonal antibody and favipiravir are the only anti-virals with some activity against Nipah virus. Standard precautions, hand hygiene and personal protective equipments are the cornerstone of comprehensive infection prevention and control strategy. With the recent outbreaks affecting newer geographical areas, there is a need for physicians to be aware of this disease and keep abreast of its current detection and management strategies.**

**Keywords:** Henipavirus, encephalitis, India, Bangladesh

### 1. Introduction

The name 'Nipah' comes from a Malaysian village, where the first outbreak was reported in 1998-1999 (1,2). The outbreak of Nipah virus (NiV) disease in Malaysia involved more than 250 cases of febrile encephalitis in farm and abattoir workers. This outbreak caused widespread panic and considerable socio-economic disruption. Although, no further outbreaks were reported from Malaysia the virus has been responsible for outbreaks in other parts of the world, mainly in Bangladesh and India (2). Recent outbreak of Nipah virus in Kerala in May 2018 brought this emerging-re-emerging virus into the spotlight again.

The high mortality rate, broad species tropism, multiple plausible modes of transmission, risk of

person-person transmission and documented cases of health care workers being affected during outbreaks has left the medical community perplexed. While a lot remains to be deciphered about the virus and many efforts to unravel its mysteries are ongoing, this article has tried to review and synthesize the available information about this virus and its clinical aspects. The clinical information presented in this article can be used as a guiding tool for physicians in an outbreak setting.

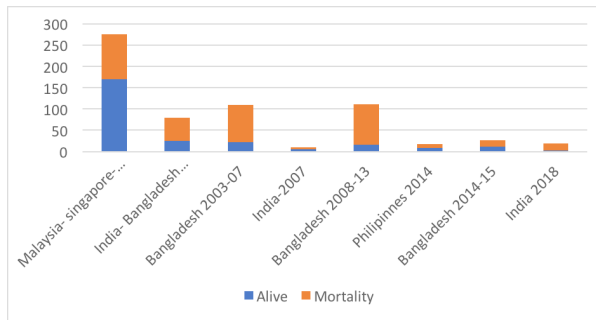
### 2. The virus

Nipah virus is an enveloped paramyxovirus with negative-stranded polarity and a non-segmented RNA genome consisting of helical nucleocapsids. NiV has subtle differences in its makeup when compared to a typical paramyxovirus. It has reticular cytoplasmic inclusions close to the endoplasmic reticulum unlike other paramyxoviruses. Also, NiV is on average larger than typical paramyxoviruses. There are only minor ultrastructural differences between Hendra virus (HeV) and NiV and they have significant cross reactivity on serological tests, and are therefore

Released online in J-STAGE as advance publication January 31, 2019.

\*Address correspondence to:

Dr. Manish Soneja, Department of Medicine, All India Institute of Medical Sciences, New Delhi 11029, India.  
E-mail: manishsoneja@gmail.com



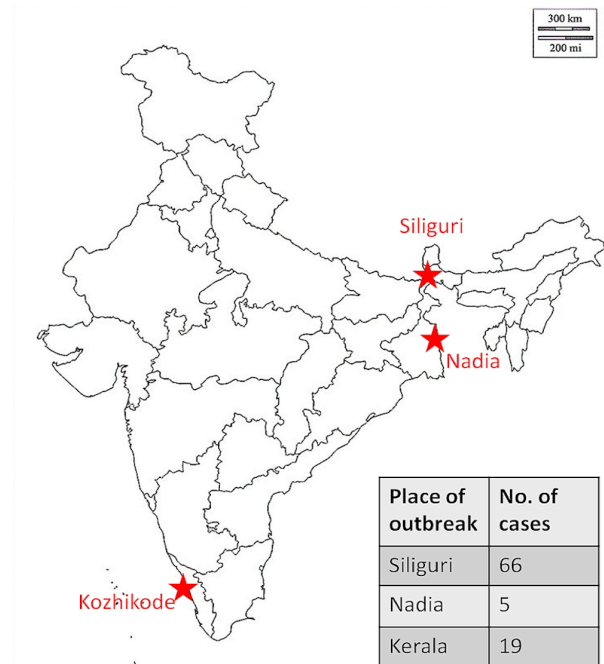
**Figure 1. Timeline of Nipah Virus outbreaks across the world with total number of cases reported in each outbreak.**

grouped as *Henipavirus* (3). Within NiV, two different strains have been identified, the Malaysian (MY) and the Bangladesh (BD) strains. The two strains are approximately 92% identical on sequencing but appear to be significantly different in their pathogenicity and transmissibility (4-7).

### 3. Epidemiology

The first outbreak of Nipah virus in Malaysia-Singapore (1998-1999) was initially thought to be Japanese encephalitis (JE), however on further investigation, it was later identified as Nipah virus (Figure 1) (3,8,9). The second outbreak of this disease was in a geographically non-contiguous location, in the Meherpur district of Bangladesh and Siliguri city of West Bengal, India in 2001 (Figures 1 and 2). The Indo-Bangladesh outbreaks were significantly different from the previous outbreak in Malaysia in terms of modes of transmission, clinical features and case fatality rates. Human to human transmission and nosocomial infections (*via* droplets and/or fomites) were a prominent feature in this outbreak. Also, the secondary attack rates were higher and the disease was more severe and rapidly progressive compared to the Malaysian outbreak. Apart from the neurological manifestations, acute respiratory distress syndrome (ARDS) and respiratory failure with multi organ dysfunction syndrome (MODS) were probably the major reason for higher mortality. Since then, there has been an outbreak in Bangladesh almost every year and a total of 17 outbreaks have been reported until 2015. There was another small outbreak in 2007 in the Nadia district of West Bengal, India (Figures 1 and 2). In the outbreak in the Philippines in March-May, 2014, both horses and humans were affected with fruit bats being the possible source of infection. Interestingly, this outbreak was significantly associated with horse slaughter and horse meat consumption (Figures 1 and 2) (10). The Indian outbreak of 2018 affected primarily the Kozhikode district and nearby area of Kerala (Figures 1 and 2) (11).

The Malaysian outbreak was primarily due to close contact with affected pigs. No human to human



**Figure 2. Nipah virus outbreaks in India.**

transmission was reported (8,12,13). The Indo-Bangladesh outbreaks, including the recent Kerala outbreak, was remarkable in various aspects, mode of transmission being one of them. A significant association of NiV disease and consumption of raw date palm sap contaminated by fruit bats was found by Luby *et al.* (14) Another study by Rahman *et al.* also concluded with similar results (15). In date palm sap the virus remains stable for at least 7 days at 22°C and is extremely tolerant to a wide range of pH (from 3 to 11) (16). Human to human and nosocomial transmission was also documented in the Indo-Bangladesh outbreaks. In the Siliguri outbreak of 2001, a single patient admitted to a private hospital infected 23 hospital staff and 8 visitors (17). Poor adherence to standard precautions was probably the major reason for this. Also, the difference in strains (BD vs. MY) contributed to the difference in the transmission rates. A study by Clayton *et al.* showed that ferrets infected with the BD strain had higher RNA levels in the blood as well as increased shedding of the virus in oral secretions, possibly explaining the higher secondary attack rates as well as more severe infection in the Indo-Bangladesh outbreak. It is noteworthy that viral shedding was seen even in the incubation period (18). The major research findings in different studies are tabulated in Table 1.

### 4. Clinical features

Clinical Features of Nipah typically includes fever with encephalitis and or respiratory involvement (Figure 3) (17,19-23). Asymptomatic infection was reported in 8% of patients with laboratory-confirmed cases in Malaysia. No such data of asymptomatic NiV infection



**Table 1. Summary of major research findings**

Author and year of publication (ref.)	Major finding related to epidemiology and transmission	Major finding related to clinical features and Diagnosis	Major finding related to therapeutic options
CDC, 1999 (8,9)	First outbreak report of Nipah. Transmission to pig abattoir workers.	Serology is cross reactive to Hendra.	--
Reynes <i>et al</i> , 2005 (4); Wacharapluesadee <i>et al</i> . 2005 (5)	Presence of NiV in bats.	--	--
Mounts <i>et al</i> , 2001 (13)	No human to human and nosocomial transmission for the Malaysian strain of NiV causing Malaysia-Singapore outbreaks.	--	--
Goh <i>et al</i> , 2000 (19)	--	Predominantly neurological symptoms and no significant respiratory symptoms in Malaysian strain of NiV.	--
Chadha <i>et al</i> , 2006 (17); Arunkumar <i>et al</i> , 2018 (53)	Strong evidence of human to human transmission for the Bangladesh strain of NiV causing Bangladeshi and Indian outbreaks.	Significant respiratory involvement leading to ARDS in Bangladesh strain of NiV.	--
Luby <i>et al</i> , 2006 (14); Rahaman <i>et al</i> , 2012 (15)	Date palm sap consumption contaminated by bat excreta and saliva is a significant risk factor for transmission.	--	--
Chong <i>et al</i> , 2001 (33)	--	Serology is cross reactive to Hendra.	Ribavirin can substantially reduce mortality (36%) without any significant adverse reactions.
Wright <i>et al</i> , 2005 (29); Aljofan <i>et al</i> , 2009 (30)	--	--	In vitro activity of ribavirin on halting the replication of NiV in cell cultures.
Bossart <i>et al</i> , 2009 (38); Bossart <i>et al</i> , 2011 (39)	--	--	Role of monoclonal antibody m102.4 in preventing transmission and halting disease progression among animal model of ferrets and African green monkey.
Dawes <i>et al</i> , 2018 (40)	--	Respiratory involvement and higher mortality in Bangladesh strain, compared to Malaysia strain.	Promising role of favipiravir in protecting NiV infected animals (hamster model).

is available from Bangladesh and Indian outbreaks. However, cases with mild and nonspecific features were identified. Fever, headache, dizziness, myalgia, vomiting and loose stools have been documented as non-specific prodromal symptoms in various outbreaks of Nipah. The Malaysian outbreak documented that 55 percent of patients had a reduced level of consciousness and prominent brain-stem dysfunction (10). Distinctive clinical signs included segmental myoclonus (32%), areflexia, hypotonia, hypertension, and tachycardia and thus suggests the involvement of the brain stem and upper cervical spinal cord. Brain stem dysfunction and neurological clinical signs include abnormal doll's eye reflex, reflexes, vasomotor changes, and myoclonic jerks. Cerebellar dysfunction was seen in eight patients in the Malaysian outbreak. In Siliguri outbreak (2001) in India, fever followed by altered sensorium (97%) developing over the next 3 to 4 days was the presenting complaint. 34 percent of the cases had convulsions (20). Similarly, in Bangladesh outbreaks, fever with altered

sensorium was the most common presentation. A case series of four outbreaks from Bangladesh shows altered mental status (90%), headache (73%), severe weakness (67%) and seizures (23%) as common neurological manifestation (17). Nipah encephalitis may present with relapse or residual deficits in survivors. Relapse of encephalitis has been demonstrated with a time range of months to years after recovery from acute infection. Psychiatric and neurological complications (depression, personality changes, deficits in attention, verbal, and/or visual memory) after recovery are also well known. Goh *et al*. reports from their Malaysian outbreak experience that 15 percent of their patients (14 patients) had residual deficits out of which five remained in a vegetative state (19). Respiratory involvement is well documented in severe cases. ARDS (50% to 66% cases) was documented in Malaysian outbreak. Siliguri outbreak witnessed 54 percent cases had associated respiratory symptoms particularly in the later stage of illness.

## 5. Diagnosis

Common hematologic abnormalities in NiV infection include thrombocytopenia (30%) and leukopenia (11%) (Table 2). Elevated liver enzymes have been seen in 40% of patients, and hyponatraemia is sometimes found. Hemoglobin, renal indices and electrolytes other than sodium are usually normal. Lymphocytic pleocytosis with raised proteins similar to any other viral meningitis may be seen in cerebrospinal fluid.

NiV is a biosafety level (BSL) 4 agent, however, BSL 2 laboratory facilities are sufficient for routine diagnosis if the virus is inactivated during specimen collection and isolation is not attempted. Laboratory diagnosis of a patient with a clinical history of NiV can be made during the acute and convalescent phases of the disease by using a combination of tests. Samples should be transported at 4°C and processed as early as possible. During the early stage of illness – virus isolation and reverse transcriptase polymerase chain reaction assay (RT PCR) from throat and nasal swabs, cerebrospinal fluid (CSF), urine, and blood is recommended (24). During the

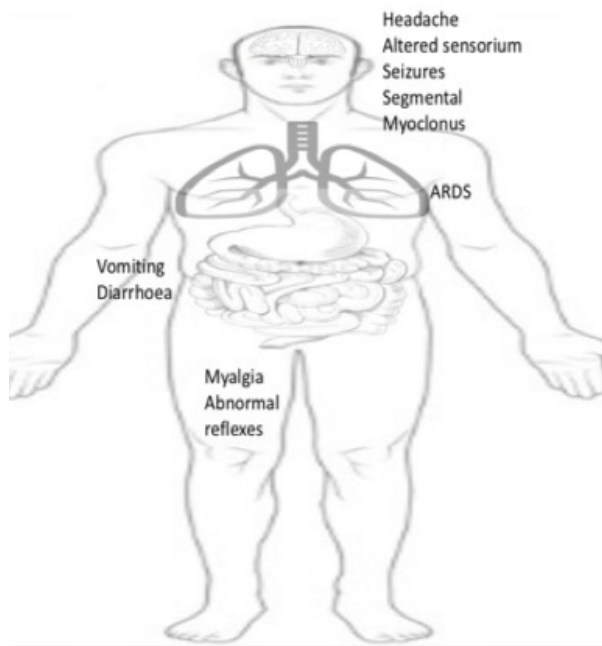


Figure 3. Clinical features of Nipah Virus disease.

convalescent phase, antibody detection by enzyme linked immunosorbent assay (ELISA-IgG and IgM) from serum or CSF may be used.

Advanced diffusion weighted (DW) magnetic resonance imaging (MRI) of the brain can give useful radiological evidence of Nipah encephalitis. Lim *et al.* suggested that MRI pattern may be useful in differentiating Nipah from its closely differential related Japanese encephalitis/other encephalitis in most cases (25). It can also help to diagnose exposed individuals, particularly at the height of an epidemic even before serologic confirmation is available (19). This finding derived from Malaysian experience during Nipah outbreak needs validation from other occurrences. More experience is required for its validation but this can be a potentially crucial finding to diagnose Nipah encephalitis and decide treatment and post exposure prophylaxis. MRI in acute Nipah encephalitis shows multifocal discrete lesions probably due to areas of micro-infarction. These discrete high-signal-intensity lesions usually measure about 2-7 mm and are disseminated throughout the brain, mainly in the subcortical and deep white matter of the cerebral hemispheres. Mass effect or edema is not usually seen. In relapse or late onset Nipah encephalitis, MRI characteristically shows multiple areas of patchy and confluent cortical involvement (26,27).

## 6. Differential diagnosis

Nipah is an important differential diagnosis in patients with fever and encephalitis and/or ARDS in context of relevant epidemiology with an ongoing outbreak in the area or relevant travel history to affected areas. But any fever or encephalitis may mimic disease and differentials need to be seen in correct perspective. The following differentials should be considered in patients with suspected Nipah infection: a) Japanese encephalitis (JE), b) Measles, c) Rabies, d) Dengue encephalitis, e) Cerebral malaria, f) Scrub typhus, g) Leptospirosis, h) Herpes encephalitis and i) Bacterial meningitis (Table 3).

## 7. Treatment and post exposure prophylaxis

Treatment of NiV disease is mostly limited to supportive

Table 2. Laboratory and Radiological diagnosis of Nipah Virus disease

Routine haematological tests	<ul style="list-style-type: none"> <li>• Thrombocytopenia</li> <li>• Leucopenia</li> <li>• Raised liver enzymes</li> <li>• Hyponatremia</li> </ul>
Cerebrospinal fluid analysis	<ul style="list-style-type: none"> <li>• Lymphocytic pleocytosis</li> <li>• Raised proteins</li> <li>• Normal glucose levels</li> </ul>
Imaging	<ul style="list-style-type: none"> <li>• 2-7mm multifocal discrete lesions in the subcortical and deep white matter</li> </ul>
NiV specific tests	<ul style="list-style-type: none"> <li>• ELISA for detection of antibodies</li> <li>• Polymerase Chain Reaction</li> <li>• Virus isolation</li> </ul>

**Table 3. Differential diagnosis of Nipah Virus disease**

Differential diagnoses	Differentiating features
1) Cerebral Malaria	<ul style="list-style-type: none"> <li>• High grade fever associated with chills and rigors</li> <li>• thrombocytopenia, hepato-renal dysfunction, hypoglycemia</li> <li>• Diagnosis by rapid antigen detection kits/peripheral smear/quantitative buffy coat examination/nucleic acid amplification</li> </ul>
2) Scrub typhus	<ul style="list-style-type: none"> <li>• Presence of eschar</li> <li>• Leucocytosis, thrombocytopenia, hepato-renal dysfunction</li> <li>• Post-monsoon (seasonal predilection)</li> <li>• Immunofluorescence assay for diagnosis</li> </ul>
3) Leptospirosis	<ul style="list-style-type: none"> <li>• Hepatitis more common</li> <li>• Post-monsoon (seasonal predilection)</li> <li>• Diagnosis by blood culture/nucleic acid amplification/serology</li> </ul>
4) Dengue encephalitis	<ul style="list-style-type: none"> <li>• Serositis and thrombocytopenia</li> <li>• Generalised erythematous blanching rash</li> <li>• Seasonal predilection</li> <li>• Diagnosis by NS1 antigen/nucleic acid amplification in first 5 days and IgM ELISA after 5 days</li> </ul>
5) Herpes meningoencephalitis	<ul style="list-style-type: none"> <li>• Fronto-temporal lobe involvement</li> <li>• Diagnosis by nucleic acid amplification</li> </ul>
6) Bacterial meningitis	<ul style="list-style-type: none"> <li>• CSF pleocytosis with neutrophilic predominance and raised proteins with low sugar</li> <li>• Diagnosis by blood and CSF culture and latex agglutination or nucleic acid amplification in CSF</li> </ul>
7) Japanese encephalitis	<ul style="list-style-type: none"> <li>• Pigs (amplifying hosts) are healthy</li> <li>• Low secondary attack rates</li> <li>• Children are affected more than adults</li> <li>• Basal ganglia involvement on imaging</li> </ul>
8) Measles	<ul style="list-style-type: none"> <li>• More in children</li> <li>• Cough, coryza, conjunctivitis</li> <li>• Maculopapular rash on face and head</li> </ul>
9) Rabies	<ul style="list-style-type: none"> <li>• Diagnosis is clinical and by serology</li> <li>• History of dog bite/bat exposure</li> <li>• Hydrophobia/aerophobia</li> <li>• Diagnosis by immunofluorescence staining for viral antigen on the biopsy from the nape of the neck</li> </ul>

care and syndromic management of acute encephalitis syndrome (28). Under the current circumstances, specific pharmacological options should not be treated as alternatives to infection control measures. More evidence needs to be generated for considering post-exposure prophylaxis in individuals who were in close contact with confirmed Nipah cases. However, three pharmacological options have been explored for the possible treatment and post-exposure prophylaxis of NiV infection: Ribavirin, m102.4 monoclonal antibody and Favipiravir.

### 7.1. Ribavirin

*In vitro* studies and animal studies have shown conflicting results in the efficacy of ribavirin against NiV and Hendra, with some studies showing effective inhibition of viral replication in cell lines (29,30), whereas some studies in animal models showed that ribavirin treatment only delayed but did not prevent death after Nipah or Hendra virus infection (31,32). Only one *in-vivo* human study by Chong *et al.* has evaluated the role of ribavirin during the Malaysia outbreak of NiV, between 1998 and 1999 (33). In this study, patients who were managed prior to the availability of ribavirin during the outbreak or who

refused ribavirin were taken as controls, and all patients who were still in the acute phase of the illness were offered ribavirin, either oral or intravenous, based on availability. A total of 140 patients treated with ribavirin were retrospectively compared with 52 control NiV patients who did not receive ribavirin due to unavailability and 2 patients who didn't consent. There was no significant difference in the incidence of adverse reactions in the treatment group as compared to controls. The study showed 45 deaths in the treated group (32%) and 29 in the controls (54%), with a total of 36% reduction in mortality. However, as treatment allocation was not randomized, it is possible that treated patients had better clinical outcomes because they received better general medical care than the untreated patients.

The dosage of ribavirin in Nipah virus has not been defined but treatment can be initiated in the lines of that suggested by WHO for Lassa fever with a loading dose of 30 mg/kg for children and 2,000 mg/kg for adults, followed by 10 days of therapy (4 g in divided doses for first four days and 2 g in divided doses for next six days). Oral bioavailability of ribavirin is reported to be between 32.6% and 52%, with evidence of first-pass metabolism. Ribavirin is not bound to plasma proteins (34). Ribavirin was found to cross the blood-brain barrier

following oral administration with a mean CSF/plasma ratio of 0.7 (35). The serious adverse drug reactions with ribavirin are: Neutropenia (8% to 40%), anemia (11% to 35%; children & adolescents: 11%), lymphocytopenia (12% to 14%) and suicidal ideations (36). Most of the side-effects with ribavirin have been noticed with long term administration. Ribavirin has been found to be teratogenic in animal studies on rodents and rabbits, but no human teratogenic studies are available. Due to the long terminal half-life of elimination of the drug, the minimum interval following treatment with ribavirin before pregnancy can be safely initiated is estimated to be 7 months (36).

The Infectious Diseases Society of America has recommended in 2008 the use of ribavirin in cases of NiV infections (37). Owing to the positive *in-vivo* and *in-vitro* results and a considerable safety profile for short term courses, a strong case can be made favoring short course high dose ribavirin for therapy. However, a controlled trial is lacking to resolve the status, for which a pre-approval should be taken from the appropriate authority, so that the trial may be immediately started with the onset of a future outbreak.

### 7.2. Monoclonal Antibody m102.4

The experimental monoclonal antibody, m102.4, which targets the ephrin-B2 and ephrin-B3 receptor binding domain of the Henipavirus G envelope glycoprotein is a potent cross-reactive neutralizing antibody *in vitro*. It was effective in protecting ferrets from lethal NiV challenge (38). In May 2010, in Queensland, Australia, m102.4 was offered as a trial on compassionate grounds to a mother and daughter who were exposed to Hendra virus from their infected horse. Both of them did not develop Hendra virus infection, although it is still not known whether treatment was effective or whether the patients did not get infected. In an animal study comprised of 14 African green monkey (AGM) subjects, m102.4 prevented infection and death after injection of a lethal dose of NiV in 12 AGM subjects. Both the control AGM subjects contracted severe infection and developed encephalitis as well as ARDS (39).

### 7.3. Favipiravir

The viral RNA-dependent RNA polymerase inhibitor favipiravir was developed by Toyama Chemical Company as an antiviral for use against influenza. In a Syrian hamster model for Nipah virus infection, favipiravir was successfully used in lethally challenged hamsters (40).

## 8. Prognosis

Case fatality rates ranges from 40% to 100%. Poor prognostic factors from the Malaysian outbreak included

old age, more severe brain-stem involvement presenting as a reduced level of consciousness, vomiting, abnormal doll's-eye reflex, abnormal pupils, hypertension, and tachycardia during the course of the illness (19).

## 9. Disease prevention

The morbidity and mortality of healthcare workers involved in care of patients with NiV is a major concern (13,17,41-44). Although, there is still a lot of confusion about transmission and spread of this paramyxovirus, there is a need to lay guidelines for protection of the healthcare workforce based on present evidence and resources available. A leaf can be drawn from the successful containment of Ebola and severe acute respiratory syndrome (SARS) outbreaks, which affected health care workers (HCWs) (45). Standard precautions, hand hygiene and personal protective equipment (PPE) remain as pillars of comprehensive infection prevention and control strategy (46,47).

All hospitals should adhere to standard infection control precautions for all patient-care activities and aerosol-generating procedures. In case of NiV infection in health-care settings, additional measures, such as droplet, contact and airborne precautions should be applied. Droplet precautions rely on isolation (one-patient isolation rooms or cohorting [*i.e.*, grouping patients infected with the same infectious agents together to confine their care to one area and prevent contact with susceptible patients]) and keeping the patient with an existing roommate. A patient that meets the criteria for a suspect Nipah case should immediately be isolated and infection control precautions instituted. In general, hospitals in at-risk areas need to be prepared for the management of Nipah cases *via* hospital screening, admission procedures and triage, and the management of visitor access and movement should be in place to minimize potential exposure. Standard precautions should be applied while handling patients, handling the deceased, handling the specimens, cleaning and waste disposal.

Hand hygiene: Handwashing with soap and water or alcohol-based hand rub before and after patient contact. Evidence from Bangladesh suggested that Nipah virus can survive on surfaces and be a potential source of spread of infection to caregivers (44). Lack of hand hygiene practices and scarcity of water in the setting was possibly responsible for HCWs being affected in the outbreak (44). The importance of hand hygiene cannot be over emphasized and it remains the crucial cornerstone for preventing spread of infection (44,46,48).

Wearing of PPE when performing an aerosol generating procedure or a patient examination. Highest level of protection (Level B/A OSHA) is recommended for Nipah. Infections in HCWs with SARS or Ebola during the respective outbreaks were very commonly attributed to improper PPE removal or doffing (49-52).

## 10. Conclusion

Nipah virus outbreak should be suspected in relevant epidemiological settings (*e.g.* history of travel or residence in known geographical areas with Nipah transmission or contact with pigs or bats) in clusters of patients presenting with acute encephalitis with or without ARDS, high secondary attack rate and very high mortality. These patients should be managed with appropriate infection control measures. Until the time when newer drugs are developed for its effective treatment, the role of drugs like ribavirin has to be clearly established with the help of properly designed trials. Effective control measures in the community to prevent its transmission from animals (bats/pigs) to humans in disease prone areas have to be instituted. In the battle of virus vs. man, hopefully the latter will turn out to be victorious in the long run.

## References

- Chua KB. Nipah virus outbreak in Malaysia. *J Clin Virol.* 2003; 26:265-275.
- Kulkarni DD, Tosh C, Venkatesh G, Senthil Kumar D. Nipah virus infection: Current scenario. *Indian J Virol.* 2013; 24:398-408.
- Ksiazek TG, Rota PA, Rollin PE. A review of Nipah and Hendra viruses with an historical aside. *Virus Res.* 2011; 162:173-183.
- Reynes JM, Counor D, Ong S, Faure C, Seng V, Molia S, Walston J, Georges-Courbot MC, Deubel V, Sarthou JL. Nipah virus in Lyle's flying foxes, Cambodia. *Emerg Infect Dis.* 2005; 11:1042-1047.
- Wacharapluesadee S, Lumlertdacha B, Boongird K, Wanghongsa S, Chanhom L, Rollin P, Stockton P, Rupprecht CE, Ksiazek TG, Hemachudha T. Bat Nipah virus, Thailand. *Emerg Infect Dis.* 2005; 11:1949-1951.
- Daszak P, Plowright R, Epstein JH, Pulliam J, Abdul Rahman S, Field HE, Smith CS, Olival KJ, Luby S, Halpin K. The emergence of Nipah and Hendra virus: pathogen dynamics across a wildlife-livestock-human continuum. *Disease Ecology: Community structure and pathogen dynamics.* 2006; 186-201.
- Hayman DT, Suu-Ire R, Breed AC, McEachern JA, Wang L, Wood JL, Cunningham AA. Evidence of henipavirus infection in West African fruit bats. *PloS One.* 2008; 3:e2739.
- Centers for Disease Control and Prevention (CDC). Outbreak of Hendra-like virus--Malaysia and Singapore, 1998-1999. *MMWR Morb Mortal Wkly Rep.* 1999; 48:265-269.
- Centers for Disease Control and Prevention (CDC). Update: Outbreak of Nipah virus - Malaysia and Singapore, 1999. *MMWR Morb Mortal Wkly Rep.* 1999; 48:335-337.
- Ching PK, de Los Reyes VC, Sucaldito MN, *et al.* Outbreak of henipavirus infection, Philippines, 2014. *Emerg Infect Dis.* 2015; 21:328-331.
- Ajith Kumar AK, Anoop Kumar AS. Deadly Nipah outbreak in Kerala: Lessons learned for the future. *Indian J Crit Care Med.* 2018; 22:475-476.
- Parashar UD, Sunn LM, Ong F, *et al.* Case-control study of risk factors for human infection with a new zoonotic paramyxovirus, Nipah virus, during a 1998-1999 outbreak of severe encephalitis in Malaysia. *J Infect Dis.* 2000; 181:1755-1759.
- Mounts AW, Kaur H, Parashar UD, Ksiazek TG, Cannon D, Arokiasamy JT, Anderson LJ, Lye MS; Nipah Virus Nosocomial Study Group. A cohort study of health care workers to assess nosocomial transmissibility of Nipah virus, Malaysia, 1999. *J Infect Dis.* 2001; 183:810-813.
- Luby SP, Rahman M, Hossain MJ, Blum LS, Husain MM, Gurley E, Khan R, Ahmed BN, Rahman S, Nahar N, Kenah E, Comer JA, Ksiazek TG. Foodborne transmission of Nipah virus, Bangladesh. *Emerg Infect Dis.* 2006; 12:1888-1894.
- Rahman MA, Hossain MJ, Sultana S, *et al.* Date palm sap linked to Nipah virus outbreak in Bangladesh, 2008. *Vector Borne Zoonotic Dis.* 2012; 12:65-72.
- Fogarty R, Halpin K, Hyatt AD, Daszak P, Mungall BA. Henipavirus susceptibility to environmental variables. *Virus Res.* 2008; 132:140-144.
- Chadha MS, Comer JA, Lowe L, Rota PA, Rollin PE, Bellini WJ, Ksiazek TG, Mishra A. Nipah virus-associated encephalitis outbreak, Siliguri, India. *Emerg Infect Dis.* 2006; 12:235-240.
- Clayton BA, Middleton D, Bergfeld J, Haining J, Arkinstall R, Wang L, Marsh GA. Transmission routes for Nipah virus from Malaysia and Bangladesh. *Emerg Infect Dis.* 2012; 18:1983-1993.
- Goh KJ, Tan CT, Chew NK, Tan PS, Kamarulzaman A, Sarji SA, Wong KT, Abdullah BJ, Chua KB, Lam SK. Clinical features of Nipah virus encephalitis among pig farmers in Malaysia. *N Engl J Med.* 2000; 342:1229-1235.
- Harit AK, Ichhpujani RL, Gupta S, Gill KS, Lal S, Ganguly NK, Agarwal SP. Nipah/Hendra virus outbreak in Siliguri, West Bengal, India in 2001. *Indian J Med Res.* 2006; 123:553-560.
- Hossain MJ, Gurley ES, Montgomery JM, *et al.* Clinical presentation of Nipah virus infection in Bangladesh. *Clin Infect Dis.* 2008; 46:977-984.
- Clayton BA. Nipah virus: Transmission of a zoonotic paramyxovirus. *Curr Opin Virol.* 2017; 22:97-104.
- Paton NI, Leo YS, Zaki SR, Auchus AP, Lee KE, Ling AE, Chew SK, Ang B, Rollin PE, Umaphathi T, Sng I, Lee CC, Lim E, Ksiazek TG. Outbreak of Nipah-virus infection among abattoir workers in Singapore. *Lancet.* 1999; 354:1253-1256.
- Daniels P, Ksiazek T, Eaton BT. Laboratory diagnosis of Nipah and Hendra virus infections. *Microbes Infect.* 2001; 3:289-295.
- Lim CT. MR imaging in Nipah virus infection. *Neurology Asia.* 2009; 14:49-52.
- Sarji SA, Abdullah BJ, Goh KJ, Tan CT, Wong KT. MR imaging features of Nipah encephalitis. *AJR Am J Roentgenol.* 2000; 175:437-442.
- Lee KE, Umaphathi T, Tan CB, Tjia HT, Chua TS, Oh HM, Fock KM, Kurup A, Das A, Tan AK, Lee WL. The neurological manifestations of Nipah virus encephalitis, a novel paramyxovirus. *Ann Neurol.* 1999; 46:428-432.
- Centers for Disease Control and Prevention. Treatment. Nipah Virus (NiV). <https://www.cdc.gov/vhf/nipah/treatment/index.html> (accessed on May 22, 2018)
- Wright PJ, Cramer G, Eaton BT. RNA synthesis during infection by Hendra virus: an examination by quantitative real-time PCR of RNA accumulation, the effect of

- ribavirin and the attenuation of transcription. *Arch Virol.* 2005; 150:521-532.
30. Aljofan M, Saubern S, Meyer AG, Marsh G, Meers J, Mungall BA. Characteristics of Nipah virus and Hendra virus replication in different cell lines and their suitability for antiviral screening. *Virus Res.* 2009; 142:92-99.
  31. Georges-Courbot MC, Contamin H, Faure C, Loth P, Baize S, Leyssen P, Neyts J, Deubel V. Poly (I)-poly (C12U) but not ribavirin prevents death in a hamster model of Nipah virus infection. *Antimicrob Agents Chemother.* 2006; 50:1768-1772.
  32. Freiberg AN, Worthy MN, Lee B, Holbrook MR. Combined chloroquine and ribavirin treatment does not prevent death in a hamster model of Nipah and Hendra virus infection. *J Gen Virol.* 2010; 91:765-772.
  33. Chong HT, Kamarulzaman A, Tan CT, Goh KJ, Thayaparan T, Kunjapan SR, Chew NK, Chua KB, Lam SK. Treatment of acute Nipah encephalitis with ribavirin. *Ann Neurol.* 2001; 49:810-813.
  34. Laskin OL, Longstreth JA, Hart CC, Scavuzzo D, Kalman CM, Connor JD, Roberts RB. Ribavirin disposition in high risk patients for acquired immunodeficiency syndrome. *Clin Pharmacol Ther.* 1987; 41:546-555.
  35. Connor E, Morrison S, Lane J, Oleske J, Sonke RL, Connor J. Safety, tolerance, and pharmacokinetics of systemic ribavirin in children with human immunodeficiency virus infection. *Antimicrob Agents Chemother.* 1993; 37:532-539.
  36. Grayson ML, Cosgrove SE, Crowe S, Hope W, McCarthy JS, Mills J, Mouton JW, Paterson DL. Kucers' The use of antibiotics: A clinical review of antibacterial, antifungal, antiparasitic, and antiviral drugs, -Three volume set. CRC Press, FL, USA. 2017.
  37. Tunkel AR, Glaser CA, Bloch KC, Sejvar JJ, Marra CM, Roos KL, Hartman BJ, Kaplan SL, Scheld WM, Whitley RJ; Infectious Diseases Society of America. The management of encephalitis: Clinical practice guidelines by the Infectious Diseases Society of America. *Clin Infect Dis.* 2008; 47:303-327.
  38. Bossart KN, Zhu Z, Middleton D, Klippel J, Cramer G, Bingham J, McEachern JA, Green D, Hancock TJ, Chan YP, Hickey AC, Dimitrov DS, Wang LF, Broder CC. A neutralizing human monoclonal antibody protects against lethal disease in a new ferret model of acute nipah virus infection. *PLoS Pathog.* 2009; 5:e1000642.
  39. Bossart KN, Geisbert TW, Feldmann H, Zhu Z, Feldmann F, Geisbert JB, Yan L, Feng YR, Brining D, Scott D, Wang Y, Dimitrov AS, Callison J, Chan YP, Hickey AC, Dimitrov DS, Broder CC, Rockx B. A neutralizing human monoclonal antibody protects african green monkeys from hendra virus challenge. *Sci Transl Med.* 2011; 3:105ra103.
  40. Dawes BE, Kalveram B, Ikegami T, Juelich T, Smith JK, Zhang L, Park A, Lee B, Komeno T, Furuta Y, Freiberg AN. Favipiravir (T-705) protects against Nipah virus infection in the hamster model. *Sci Rep.* 2018; 8:7604.
  41. Gurley ES, Montgomery JM, Hossain MJ, Islam MR, Molla MA, Shamsuzzaman SM, Akram K, Zaman K, Asgari N, Comer JA, Azad AK, Rollin PE, Ksiazek TG, Breiman RF. Risk of nosocomial transmission of Nipah virus in a Bangladesh hospital. *Infect Control Hosp Epidemiol.* 2007; 28:740-742.
  42. Stone R. Epidemiology. Breaking the Chain in Bangladesh. *Science.* 2011; 331:1128-1131.
  43. Luby SP, Gurley ES, Hossain MJ. Transmission of human infection with Nipah Virus. *Clin Infect Dis.* 2009; 49:1743-1748.
  44. Gurley ES, Montgomery JM, Hossain MJ, *et al.* Person-to-person transmission of Nipah virus in a Bangladeshi community. *Emerg Infect Dis.* 2007; 13:1031-1037.
  45. Personal protective equipment for use in a filovirus disease outbreak: Rapid advice guideline. Geneva: World Health Organization; 2016. <http://www.ncbi.nlm.nih.gov/books/NBK401170/> (accessed on August 17, 2018).
  46. Siegel JD, Rhinehart E, Jackson M, Chiarello L. Health Care Infection Control Practices Advisory Committee. 2007 guideline for isolation precautions: Preventing transmission of infectious agents in health care settings. *Am J Infect Control.* 2007; 35:S65-S164.
  47. Garner JS. Guideline for isolation precautions in hospitals. The Hospital Infection Control Practices Advisory Committee. *Infect Control Hosp Epidemiol.* 1996; 17:53-80.
  48. Boyce JM, Pittet D; Healthcare Infection Control Practices Advisory Committee; HICPAC/SHEA/APIC/IDSA Hand Hygiene Task Force. Guideline for Hand Hygiene in Health-Care Settings. Recommendations of the Healthcare Infection Control Practices Advisory Committee and the HICPAC/SHEA/APIC/IDSA Hand Hygiene Task Force. Society for Healthcare Epidemiology of America/Association for Professionals in Infection Control/Infectious Diseases Society of America. *MMWR Recomm Rep.* 2002; 51:1-45, quiz CE1-4.
  49. Weber DJ, Rutala WA, Schaffner W. Lessons learned: Protection of healthcare workers from infectious disease risks. *Crit Care Med.* 2010; 38:S306-S314.
  50. Centers for Disease Control and Prevention (CDC). Cluster of severe acute respiratory syndrome cases among protected health-care workers--Toronto, Canada, April 2003. *MMWR Morb Mortal Wkly Rep.* 2003; 52:433-436.
  51. Zamora JE, Murdoch J, Simchison B, Day AG. Contamination: A comparison of 2 personal protective systems. *CMAJ.* 2006; 175:249-254.
  52. Kreuels B, Addo MM, Schmiedel S. Severe Ebola virus infection complicated by gram-negative septicemia. *N Engl J Med.* 2015; 372:1377.
  53. Arunkumar G, Chandni R, Chandni R, Mourya DT, Singh SK, Sadanandan R, Sudan P, Bhargava B; NIPAH: Nipah Investigators People And Health. Outbreak Investigation of Nipah Virus Disease in Kerala, India, 2018. *J Infect Dis.* 2018; doi: 10.1093/infdis/jiy612

(Received December 4, 2018; Revised January 6, 2019; Accepted January 15, 2019)

# Management strategies in facioscapulohumeral muscular dystrophy

Junren Lu<sup>1,§</sup>, Zhenjun Yao<sup>1,§</sup>, Yi Yang<sup>1</sup>, Chi Zhang<sup>1,\*</sup>, Jian Zhang<sup>1,\*</sup>, Ying Zhang<sup>2</sup>

<sup>1</sup>Department of Orthopedic Surgery, Zhongshan Hospital affiliated with Fudan University, Shanghai, China;

<sup>2</sup>Department of Nursing, Zhongshan Hospital affiliated with Fudan University, Shanghai, China.

## Summary

**Facioscapulohumeral muscular dystrophy (FSHD) also known as Landouzy-Dejerine disease, is an autosomal-dominant disorder of the skeletal muscles with the name according to the various muscle groups it affects: the face, shoulders and upper arms. It is the third most common genetic degenerative disorder of the skeletal muscles without specific patterns in all the affected individuals. At present there is no cure for the disease but numerous management strategies are available to improve the quality of life and prevent further degeneration of various muscle groups. This review aims to provide an insight on the management strategies for FSHD patients including both lifestyle and medical intervention.**

**Keywords:** Facioscapulohumeral muscular dystrophy, Landouzy-Dejerine disease, clinical manifestations, management, surgical intervention

## 1. Introduction

Facioscapulohumeral muscular dystrophy (FSHD) also known as Landouzy-Dejerine disease, is the third most common genetic abnormality of the skeletal muscles characterized by progressive muscular dystrophy commonly appearing in individuals before the age of 20 (1,2). Individuals with mild symptoms may manifest FSHD in their later stages of life, but in rare cases, FSHD may also manifest early during infancy or childhood. It is an autosomal dominant genetic disorder which obtains its name from the muscle groups it affects: skeletal muscles of the face (facio), muscle groups surrounding the shoulder blades (scapulo), and the upper arms (humeral). There has not been an agreement on the prevalence on FSHD, but several authors reported a prevalence of 4 to 10 in 100,000 people (3-5).

FSHD commonly presents early in childhood with 95 percent of the affected individuals manifesting the disease by the age of 20 (6). Muscle weakness is commonly non-specific but asymmetrical in occurrence.

Individuals with FSHD manifesting with diaphragmatic weakness are at risk of respiratory insufficiency and 20 percent of individuals with FSHD become physically dependent requiring the use of wheelchairs or mobility scooters (7). Most of the cases of FSHD are associated with disorders of D4Z4 repeat in the 4q35 subtelomeric region of chromosome 4. A 2010 report on a unifying theory for the pathogenesis of FSHD explains a second mechanism resulting in toxic gain of function of the *DUX4* gene. This recent finding proposed the first pathophysiologic definition of the disease and the possible therapeutic approaches for management of FSHD (8).

Numerous management strategies are available to improve the quality of life of FSHD patients. A prompt diagnosis and lifestyle adjustments are detrimental in preventing unwanted mortality. This review aims to provide an insight into the numerous management strategies in FSHD patients according to each symptomatic presentation.

## 2. Clinical manifestations of FSHD

Different variations of FSHD exist resulting in the absence of an exact set of symptoms (1,9). FSHD commonly presents as progressive muscle weakness which involves various muscle groups of the face (difficulty whistling, drooping eyelid, decreased facial expressions, speech impairment), shoulder girdle

<sup>§</sup>These authors contributed equally to this work.

\*Address correspondence to:

Dr. Chi Zhang and Dr. Jian Zhang, Department of Orthopedic Surgery, Zhongshan Hospital affiliated with Fudan University, 180 Fenglin Road, Shanghai 200032, China.

E-mail: zhangchi.yaozhenjun@aliyun.com (CZ), zhang.jian@zs-hospital.sh.cn (JZ)

(difficulty raising arms laterally, sloping shoulder), and upper arms (asymmetrical weakness of the biceps and triceps brachii) (1,10,11). Muscle weakness prominent on one side of the body and scapular winging are the two main characteristics for FSHD. Scapular winging results from weakness of the lower trapezius muscle causing an upward movement of the scapula during flexion of the arm (posterior protrusion), which becomes obvious when the affected individual tries to raise their arms laterally (10). The shoulders tend to have a forward slant with straight clavicles and prominent atrophy of the pectoral muscles.

Typical symptoms of FSHD also involve muscle groups of the face, abdomen and diaphragm. Early presentation of FSHD is often characterized by a pronounced weakness of the facial muscles, which are then followed by symptoms of the shoulders (scapular winging) (12). Early signs also include difficulty whistling due to being unable to purse their lips or sleeping with their eyes partially open due to being unable to completely close their eyelids (13,14). In most cases, extraocular muscles, the eyelid and bulbar muscles are spared.

Individuals with FSHD often have unaffected deltoid muscles in the early stages. The biceps and triceps muscles are asymmetrically involved resulting in a prominent atrophy of the upper arms without affecting the forearm muscles. This leads to the appearance of a large forearm in comparison to the upper arm (Popeye arms) (11). Abdominal muscle weakness may lead to abdominal protuberance and in some cases, lumbar lordosis (15). Weakness of the lower abdominal muscles results in an upward displacement of the umbilicus upon flexion of the neck during supination (Beever's sign) (5,16).

Muscular weakness of the hip and pelvis results in difficulty climbing stairs or prolonged walking. This condition is further worsened by an aggravated curvature in individuals presenting with lumbar lordosis (12). FSHD individuals affected with progressive movement impairment then become physically dependent on mobility aids.

In rare cases, weakness of the diaphragm leads to respiratory insufficiency, increasing the overall mortality of this disease (2). Retinal telangiectasia and macular edema mimicking Coat's disease may also arise due to failure of vascularization of the vascular peripheries (17). Telangiectatic changes and microaneurysms can be detected by fluorescein angiography in up to 60 percent of the affected individuals (18,19). Bilateral high-tone sensorineural hearing loss can be detected in up to 60 percent of affected individuals. Subclinical sensorineural hearing loss occurs in a higher proportion of individuals (20).

In a study by Zatz *et al.* (19), FSHD penetrance was found to differ according to age and gender. Penetrance by the age of 30 was estimated to be at 83

percent for both genders, but significantly higher in males (95%) compared to females (69%). They also reported that *de novo* mutations were more common in females compared to the male participants. No particular evidence of X-chromosome related recessive inheritance is seen, which may be related to excess of symptomatic female individuals in their familial studies including asymptomatic mothers.

### 3. Subtypes of FSHD

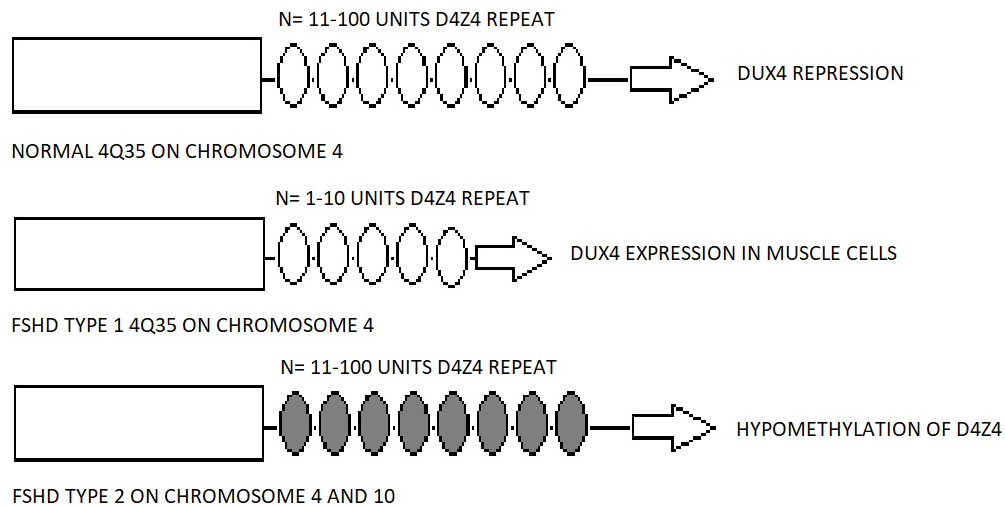
#### 3.1. FSHD Type 1

At least 95 percent of the affected individuals are associated with the pathogenic contraction of D4Z4 repeat (3.2kb unit, normally at 11-100 repeats) at the subtelomeric region 4q35 on chromosome 4. D4Z4 comprises both heterochromatin and euchromatin structures as well as the putative *DUX4* gene. A decreased D4Z4 repeat below a certain threshold results in a corresponding relaxation of the chromatin, causing an inappropriate expression of *DUX4* in muscle cells which leads to disease progression. In a study in 2014, FSHD was proposed as an "inefficient repeat-mediated epigenetic repression of the D4Z4 macrosatellite repeat array on chromosome 4, resulting in the variegated expression of the *DUX4* retrogene, encoding a double-homeobox transcription factor in skeletal muscle" (15). In a regular individual, the D4Z4 repeats are above a certain threshold value and keep the expression of *DUX4* repressed. Individuals affected with FSHD possess drastically lower amounts of D4Z4 in addition to a haplotype polymorphism on chromosome 4, causing expression of *DUX4*.

#### 3.2. FSHD Type 2

The majority of FSHD occurrences are Type 1 cases, accounting for approximately 95 percent. The remaining 5 percent of the cases are Type 2, possessing a phenotype indistinguishable from FSHD but without any evidence of pathological changes of D4Z4 (8,21). Individuals with FSHD type 2 have an open chromatin structure at the D4Z4 loci characterized by CpG methylation loss at D4Z4 repeats in chromosome 4 and 10. Around 80 percent of the cases of FSHD type 2 chromatin relaxation are caused by mutation of SMCHD1 (Structural maintenance of chromosome flexible hinge domain containing gene 1) on chromosome 18. SMCHD1 mutation results in the shortening of DNA of the D4Z4 region, which is permissive for the misexpression of the *DUX4* gene by repressing transcription through CpG DNA methylation (22). FSHD type 2 phenotype occurs in individuals who inherit both the SMCHD1 mutation as well as a permissive *DUX4* allele, presenting with a digenic inheritance pattern (23). A structural representation of





**Figure 1. Schematic representation of a pathologic Chromosome 4 in FSHD Type 1 compared to a normal allele.** The normal allele normally has 11-100 repeats of D4Z4 (represented by ovals) which is contracted to less than 10 units in FSHD Type 1. In FSHD Type II there is no evidence of pathological change of D4Z4 but there is hypomethylation loss in chromosome 4 and 10.

both FSHD type I and type II are represented in Figure 1.

#### 4. Treatment modalities

Currently there are no specific therapeutic cures for FSHD. But in 2010, the standard of care and management of FSHD were discussed and a census was agreed on at the 171st ENMC International Workshop (24). The main treatment strategies are divided upon the different aspects of the muscle systems it affects (25).

Individuals affected with FSHD are recommended to seek consultation with a physical therapist. The initial consultation may include the overall assessment of the balance, gait, posture, and the probable need of walking aids. According to each individual, a suitable exercise regimen including both aerobic and anaerobic exercises may be suggested to prevent movement impairment. Affected individuals will require a progressive follow-up to monitor the progress of muscular dystrophy and movement impairments during everyday activities. Stretching exercises and low intensity anaerobic exercises are beneficial in the management of symptoms and improve the overall cardiovascular function and muscle strength without having detrimental effects (26).

Affected individuals with severe mobility impairments will require continuous input from a physical therapist and may require mobility aids from an orthotist. Patients presenting with a prominent foot drop will benefit from the use of ankle-foot orthoses. Simple prostheses however may further provide a hindrance to patients who present with an accompanying quadriceps atrophy leading to weakness of the extensor mechanisms (27). A simple ankle-foot orthoses will prevent the full extension of the affected

knee and further worsen the walking gait. A floor-reaction ankle-foot orthoses or knee-ankle-foot orthoses are advised for patients presenting with foot drop and inadequate extensor mechanisms simultaneously.

Pain and fatigue are common findings in individuals with FSHD and are often neglected. In a study by van der Kooi *et al.* (28) they reported that pain occurs in 77 percent of their study population and is reported to occur daily. The most common source of pain is recorded to be localized around the joints where muscle weakness is observed: shoulders, upper back, knees and lumbosacral regions due to hyperlordosis. Pain may also reflect changes in psychological conditions. Chronic pain should be managed with appropriate analgesics and antidepressants if necessary, to improve the quality of life of FSHD individuals.

Respiratory insufficiency may occur in less than 1 percent of individuals with FSHD if muscular dystrophy affects the respiratory muscles (7). Patients presenting with severe symptoms of FSHD should be screened for the possibility of breathing disorders to reduce the overall mortality. Individuals requiring surgical correction are advised to undergo a comprehensive pulmonary function test (PFT) in case of anesthetic reactions. A routine pulmonary workup is also recommended for individuals with severe mobility deficiency, presenting with pelvic weakness accompanied with underlying pulmonary comorbidities, and individuals presenting with obvious spinal deformities causing an obvious abnormality in the thoracic cavity.

Cardiac abnormalities are present in approximately 5 percent of individuals with FSHD without other risk factors for cardiac diseases (29,30). Individuals commonly present with complaints of chest discomfort accompanied with a cardiac arrhythmia on an

electrocardiogram (ECG) caused by right bundle branch block, which may also be asymptomatic. At present, an ECG is not a routine exam in individuals with FSHD but may be recommended for those at risk.

In a multicenter study by Trevisan *et al.* (31), individuals affected with FSHD underwent auditory examination. Four patients with FSHD were tested to have auditory problems but none had awareness of any hearing loss. Innate FSHD occurring in infants may lead to auditory and verbal delays in development without being detected and be mistaken for cognitive abnormalities. Cognitive and hearing testing should be routinely examined in children diagnosed with FSHD to prevent auditory and speech impairment due to hearing loss.

Retinal changes in individuals with FSHD commonly are not life-threatening conditions. Retinal vasculopathy is commonly found in individuals affected with FSHD, but the localized pathological changes of the ocular vessels may be effectively treated with laser therapy (24,32). Common findings also include keratitis in individuals who are unable to completely shut their eyelids during sleep. A consultation with an Ophthalmologist is advised for all individuals with FSHD.

Orthopedic intervention is advised for individuals presenting with an obvious scapular winging in a rapidly progressive FSHD. Surgical fixation of the scapula to the thoracic wall (33-35) improves the overall range of motion of the arm in the affected side of the body, but may be temporary. In a series by Giannini *et al.* (10), 13 FSHD patients presenting with winged scapula underwent bilateral surgical fixation. All 13 patients experienced an obvious increase in active range of motion and a fix for their winged scapula. The scapulothoracic fixation provides a support for deltoid contraction which allows the affected arm to abduct and flex. This however does not provide a full range of motion because the treated joint will not be able to contribute to the arc of motion (10).

Hyperlordosis is a common presentation of FSHD, which subsequently causes pelvic extensor and paraspinal muscle insufficiency (36,37). The spinal deformity is a direct cause of incorrect posture and movement disorders, and patients do not benefit from simple bracing. There is no consensus on surgical intervention for hyperlordosis in FSHD patients due to the controversial results. But in a case report by Tan *et al.* (38), they reported a successful partial correction of hyperlordosis with an improvement in sitting posture after surgical correction. Surgical intervention in FSHD patients presenting with hyperlordosis requires further investigation to achieve a definite indication.

Two conflicting studies by Ciafaloni *et al.* (39) and Rudnik-Schoneborn (40) report on the risk factors for caesarian surgeries and preterm births, and FSHD. In cases of pregnant women affected with FSHD, 25

percent of the individuals report a progressive decrease in motor function which corresponds to the occurrence in other neuromuscular disorders. A comprehensive consult by an obstetrician is advised for pregnant women with FSHD to prevent pregnancy and delivery complications. Pregnant women with FSHD are also advised to closely monitor cardiopulmonary functions to prevent unwanted morbidities.

## 5. Conclusion

FSHD is one of the most common skeletal diseases, which is easily misdiagnosed during its early stages causing undesired effects in the overall quality of life. Numerous management strategies are available and crucial to prevent undesired progression of the disease. Early diagnosis and a prompt intervention are necessary in improving the life expectancy of FSHD patients.

## References

1. Tawil R, Van Der Maarel SM. Facioscapulohumeral muscular dystrophy. *Muscle Nerve*. 2006; 34:1-15.
2. Kilmer DD, Abresch RT, McCrory MA, Carter GT, Fowler WM Jr, Johnson ER, McDonald CM. Profiles of neuromuscular diseases. Facioscapulohumeral muscular dystrophy. *Am J Phys Med Rehabil*. 1995; 74:S131-S139.
3. Sposito R, Pasquali L, Galluzzi F, Rocchi A, Solito B, Soragna D, Tupler R, Siciliano G. Facioscapulohumeral muscular dystrophy type 1A in northwestern Tuscany: A molecular genetics-based epidemiological and genotype-phenotype study. *Genet Test*. 2005; 9:30-36.
4. Deenen JC, Arnts H, van der Maarel SM, Padberg GW, Verschuuren JJ, Bakker E, Weinreich SS, Verbeek AL, van Engelen BG. Population-based incidence and prevalence of facioscapulohumeral dystrophy. *Neurology*. 2014; 83:1056-1059.
5. Deenen JC, Horlings CG, Verschuuren JJ, Verbeek AL, van Engelen BG. The epidemiology of neuromuscular disorders: A comprehensive overview of the literature. *J Neuromuscul Dis*. 2015; 2:73-85.
6. Kissel JT. Facioscapulohumeral muscular dystrophy. *Semin Neurol*. 1999; 19:35-43.
7. Wohlgenuth M, van der Kooi EL, van Kesteren RG, van der Maarel SM, Padberg GW. Ventilatory support in facioscapulohumeral muscular dystrophy. *Neurology*. 2004; 63:176-178.
8. Lemmers RJ, van der Vliet PJ, Klooster R, Sacconi S, Camaño P, Dauwerse JG, Snider L, Straasheijm KR, van Ommen GJ, Padberg GW, Miller DG, Tapscott SJ, Tawil R, Frants RR, van der Maarel SM. A unifying genetic model for facioscapulohumeral muscular dystrophy. *Science*. 2010; 329:1650-1653.
9. van der Kooi AJ, Visser MC, Rosenberg N, van der Berg-Vos R, Wokke JH, Bakker E, de Visser M. Extension of the clinical range of facioscapulohumeral muscular dystrophy: Report of six cases. *J Neurol Neurosurg Psychiatry*. 2000; 69:114-116.
10. Giannini S, Faldini C, Pagkrati S, Grandi G, Digennaro V, Luciani D, Merlini L. Fixation of winged scapula in facioscapulohumeral muscular dystrophy. *Clin Med Res*. 2007; 5:155-162.

11. Statland JM, Tawil R. Facioscapulohumeral muscular dystrophy. *Continuum (Minneapolis, Minn)*. 2016; 22:1916-1931.
12. Kottlors M, Kress W, Meng G, Glocker FX. Facioscapulohumeral muscular dystrophy presenting with isolated axial myopathy and bent spine syndrome. *Muscle Nerve*. 2010; 42:273-275.
13. Jordan B, Eger K, Koesling S, Zierz S. Camptocormia phenotype of FSHD: A clinical and MRI study on six patients. *J Neurol*. 2011; 258:866-873.
14. Krasnianski M, Eger K, Neudecker S, Jakubiczka S, Zierz S. Atypical phenotypes in patients with facioscapularhumeral muscular dystrophy 4q35 deletion. *Arch Neurol*. 2003; 60:1421-1425.
15. Tawil R, van der Maarel SM, Tapscott SJ. Facioscapulohumeral dystrophy: The path to consensus on pathophysiology. *Skelet Muscle*. 2014; 4:12.
16. Eger K, Jordan B, Habermann S, Zierz S. Beevor's sign in facioscapulohumeral muscular dystrophy: An old sign with new implications. *J Neurol*. 2010; 257:436-438.
17. Osborne RJ, Welle S, Venance SL, Thornton CA, Tawil R. Expression profile of FSHD supports a link between retinal vasculopathy and muscular dystrophy. *Neurology*. 2007; 68:569-577.
18. Lindner M, Holz FG, Charbel Issa P. Spontaneous resolution of retinal vascular abnormalities and macular oedema in facioscapulohumeral muscular dystrophy. *Clin Exp Ophthalmol*. 2016; 44:627-628.
19. Zatz M, Marie SK, Cerqueira A, Vainzof M, Pavanello RC, Passos-Bueno MR. The facioscapulohumeral muscular dystrophy (*FSHD1*) gene affects males more severely and more frequently than females. *Am J Med Genet*. 1998; 77:155-161.
20. Padberg GW, Brouwer OF, de Keizer RJ, Dijkman G, Wijmenga C, Grote JJ, Frants RR. On the significance of retinal vascular disease and hearing loss in facioscapulohumeral muscular dystrophy. *Muscle Nerve Suppl*. 1995; S73-S80.
21. de Greef JC, Lemmers RJ, van Engelen BG, Sacconi S, Venance SL, Frants RR, Tawil R, van der Maarel SM. Common epigenetic changes of D4Z4 in contraction-dependent and contraction independent FSHD. *Hum Muta*. 2009; 30:1449-1459.
22. Blewitt ME, Gendrel AV, Pang Z, Sparrow DB, Whitelaw N, Craig JM, Apedaile A, Hilton DJ, Dunwoodie SL, Brockdorff N, Kay GF, Whitelaw E. SmcHD1, containing a structural-maintenance-of-chromosomes hinge domain, has a critical role in X inactivation. *Nat Genet*. 2008; 40:663-669.
23. Lemmers RJ, Tawil R, Petek LM, *et al*. Digenic inheritance of an SMCHD1 mutation and an FSHD-permissive D4Z4 allele causes facioscapulohumeral muscular dystrophy type 2. *Nat Genet*. 2012; 44:1370-1374.
24. Tawil R, van der Maarel S, Padberg GW, van Engelen BG. 171st ENMC International workshop: Standards of care and management of facioscapulohumeral muscular dystrophy. *Neuromuscul Disord*. 2010; 20:471-475.
25. Tawil R, Kissel JT, Heatwole C, *et al*. Evidence-based guideline summary: Evaluation, diagnosis, and management of facioscapulohumeral muscular dystrophy: Report of the Guideline Development, Dissemination, and Implementation Subcommittee of the American Academy of Neurology and the Practice Issues Review Panel of the American Association of Neuromuscular & Electrodiagnostic Medicine. *Neurology*. 2015; 85:357-364.
26. Olsen DB, Orngreen MC, Vissing J. Aerobic training improves exercise performance in facioscapulohumeral muscular dystrophy. *Neurology*. 2005; 64:1064-1066.
27. Tawil R. Facioscapulohumeral muscular dystrophy. *Neurotherapeutics*. 2008; 5:601-606.
28. van der Kooij EL, Kalkman JS, Lindeman E, Hendriks JC, van Engelen BG, Bleijenberg G, Padberg GW. Effects of training and albuterol on pain and fatigue in facioscapulohumeral muscular dystrophy. *J Neurol*. 2007; 254:931-940.
29. Laforêt P, de Toma C, Eymard B, Becane HM, Jeanpierre M, Fardeau M, Duboc D. Cardiac involvement in genetically confirmed facioscapulohumeral muscular dystrophy. *Neurology*. 1998; 51:1454-1456.
30. Trevisan CP, Pastorello E, Armani M, Angelini C, Nante G, Tomelleri G, Tonin P, Mongini T, Palmucci L, Galluzzi G, Tupler RG, Barchitta A. Facioscapulohumeral muscular dystrophy and occurrence of heart arrhythmia. *Eur Neurol*. 2006; 56:1-5.
31. Trevisan CP, Pastorello E, Ermani M, Angelini C, Tomelleri G, Tonin P, Mongini T, Palmucci L, Galluzzi G, Tupler RG, Marioni G, Rimini A. Facioscapulohumeral muscular dystrophy: A multicenter study on hearing function. *Audiol Neurootol*. 2008; 13:1-6.
32. Fitzsimons RB, Gurwin EB, Bird AC. Retinal vascular abnormalities in facioscapulohumeral muscular dystrophy. A general association with genetic and therapeutic implications. *Brain*. 1987; 110(Pt 3):631-648.
33. Mummery CJ, Copeland SA, Rose MR. Scapular fixation in muscular dystrophy. *Chochrane Database Syst Rev*. 2003; CD003278.
34. Rhee YG, Ha JH. Long-term results of scapulothoracic arthrodesis of facioscapulohumeral muscular dystrophy. *J Shoulder Elbow Surg*. 2006; 15:445-450.
35. Demirhan M, Uysal O, Atalar AC, Kilicoglu O, Serdaroglu P. Scapulothoracic arthrodesis in facioscapulohumeral dystrophy with multifilament cables. *Clin Orthop Relat Res*. 2009; 467:2090-2097.
36. Lee CS, Kang SJ, Wang CJ, Lee SW, Ahn YJ, Kim YT, Lee DH, Lee MY. Early-onset facioscapulohumeral muscular dystrophy - significance of pelvic extensors in sagittal spinal imbalance. *J Pediatr Orthop B*. 2009; 18:325-329.
37. Rijken NH, van Engelen BG, de Rooy JW, Geurts AC, Weerdesteyn V. Trunk muscle involvement is most critical for the loss of balance control in patients with facioscapulohumeral muscular dystrophy. *Clin Biomech (Bristol, Avon)*. 2014; 29:855-860.
38. Tan H, Feng F, Lin Y, Chen C, Li Z, Shen J. Surgical correction of hyperlordosis in facioscapulohumeral muscular dystrophy: A case report. *BMC Surg*. 2017; 17:83.
39. Cialfoni E, Pressman EK, Lori AM, Smirnow AM, Guntrum DJ, Dilek N, Tawil R. Pregnancy and birth outcomes in women with facioscapulohumeral muscular dystrophy. *Neurology*. 2006; 67:1887-1889.
40. Rudnik-Schoneborn S, Golner B, Rohrig D, Zerres K. Obstetric aspects in women with facioscapulohumeral muscular dystrophy, limb-girdle muscular dystrophy, and congenital myopathies. *Arch Neurol*. 1997; 54:888-894.

(Received January 31, 2019; Revised February 22, 2019; Accepted February 24, 2019)

## Novel missense mutation affecting the LIM-A domain of LMX1B in a family with Nail-Patella syndrome

Felix Claverie-Martin<sup>1,\*</sup>, Amelia Trindade<sup>1,§</sup>, Noriela C. Garcia-Gonzalez<sup>2</sup>, Alicia Callejon Callejon<sup>3</sup>

<sup>1</sup>Unidad de Investigacion, Hospital Nuestra Señora de Candelaria, Santa Cruz de Tenerife, Spain;

<sup>2</sup>Servicio de Rehabilitación, Hospital Nuestra Señora de Candelaria, Santa Cruz de Tenerife, Spain;

<sup>3</sup>Servicio de Pediatría, Hospital Nuestra Señora de Candelaria, Santa Cruz de Tenerife, Spain.

### Summary

Nail-patella syndrome (NPS) is a rare autosomal dominant disease characterized by developmental defects of dorsal limb structures, the kidney, and the eye, that manifest as dysplastic nails, hypoplastic or absent patella, elbow dysplasia, iliac horns, glomerulopathy, and adult-onset glaucoma, respectively. This disorder is inherited in an autosomal dominant mode and is caused by heterozygous loss-of-function mutations in the *LMX1B* gene, which encodes the LIM homeodomain transcription factor LMX1B. In this study, we report the clinical findings of a Spanish family, from the Canary Islands, with three affected members who displayed varying phenotypes. DNA sequence analysis identified a novel heterozygous missense mutation in *LMX1B*, c.305A>G, p.(Y102C), that segregated with the disease. The tyrosine residue affected by the mutation is highly conserved in evolution, and is located in the LIM-A domain, next to one of the cysteine residues involved in zinc binding, suggesting that p.(Y102C) affects LMX1B function by disturbing its interactions with other proteins. Our results expand the mutation spectrum of *LMX1B* and provide insight into the molecular mechanisms of NPS pathology.

**Keywords:** *LMX1B*, nail-patella syndrome, missense mutation, transcription factor, zinc finger

### 1. Introduction

Nail-patella syndrome (NPS; OMIM #161200), also known as hereditary osteoonychodysplasia, is a rare autosomal dominant disease characterized by nail malformations, absent or hypoplastic patellae, dysplasia of the elbows and dorsal ilium, nephropathy, and, in some cases primary open-angle glaucoma (1). Other common findings in NPS are hyperpigmentation of the central part of the iris (Lester's sign), ocular hypertension,

and sensorineural hearing loss. Furthermore, some patients present with renal involvement, ranging from asymptomatic proteinuria to nephrotic syndrome and sporadically end-stage renal failure (2-4).

The disease is caused by heterozygous loss-of-function mutations in the gene *LMX1B*, located on chromosome 9q34, which encodes the LIM-homeodomain transcription factor LMX1B (5-7). Molecular studies in *Lmx1b* knock out (KO) mice have shown that *Lmx1b* plays an important role in dorso-ventral patterning of limb development, morphogenesis and function of the podocytes and the glomerular basement membrane, and development of the anterior segment of the eye (8-11). Some of these findings indicate that the skeletal phenotype of NPS is the consequence of a defect in developmental patterning. More recent studies in an inducible podocyte-specific *Lmx1b* KO mouse have shown that deletion of this gene in fully differentiated podocytes causes proteinuria and deregulation of the actin cytoskeleton (12). This indicates an essential role of *Lmx1b* in maintenance of

Released online in J-STAGE as advance publication January 31, 2019.

\*Address correspondence to:

Dr. Félix Claverie-Martín, Unidad de Investigación, Hospital Nuestra Señora de Candelaria, Carretera del Rosario 145, 38010 Santa Cruz de Tenerife, Spain.  
E-mail: fclamar@gobiernodecanarias.org

§Present address:

Departamento de Medicina, Centro de Ciências Biológicas e da Saude (CCBS), Universidade Federal de São Carlos, São Carlos, Brasil.

differentiated podocytes in adult kidneys. The LMX1B protein contains two N-terminal zinc-binding LIM domains, LIM-A and LIM-B, which mediate protein-protein interactions, a homeodomain important for DNA binding, and a C-terminal glutamine-rich region that could be involved in transcriptional regulation (1). Activation of transcription by LMX1B requires its interaction with other transcription factors. Different *LMX1B* mutations that cause NPS have been identified, including mainly missense and nonsense mutations, small deletions and insertions, splice site mutations, and a few large gene deletions (3,13-15). These mutations are generally located in the homeodomain or in the LIM domains and affect conserved amino acid residues (16). It has not been possible to establish a correlation between phenotype and genotype in NPS patients. In fact, significant phenotypic variability at the individual, intrafamilial, and interfamilial level has been reported for different NPS symptoms (2). However, specific mutations in the central homeodomain of LMX1B seem to be associated with proteinuria and nephropathy without the NPS skeletal defects (2,4).

In the present study, we report the clinical findings of a Spanish family with three NPS affected members, and the identification of a novel heterozygous *LMX1B* missense mutation that segregates with the disease and disturbs the LIM-A domain of LMX1B.

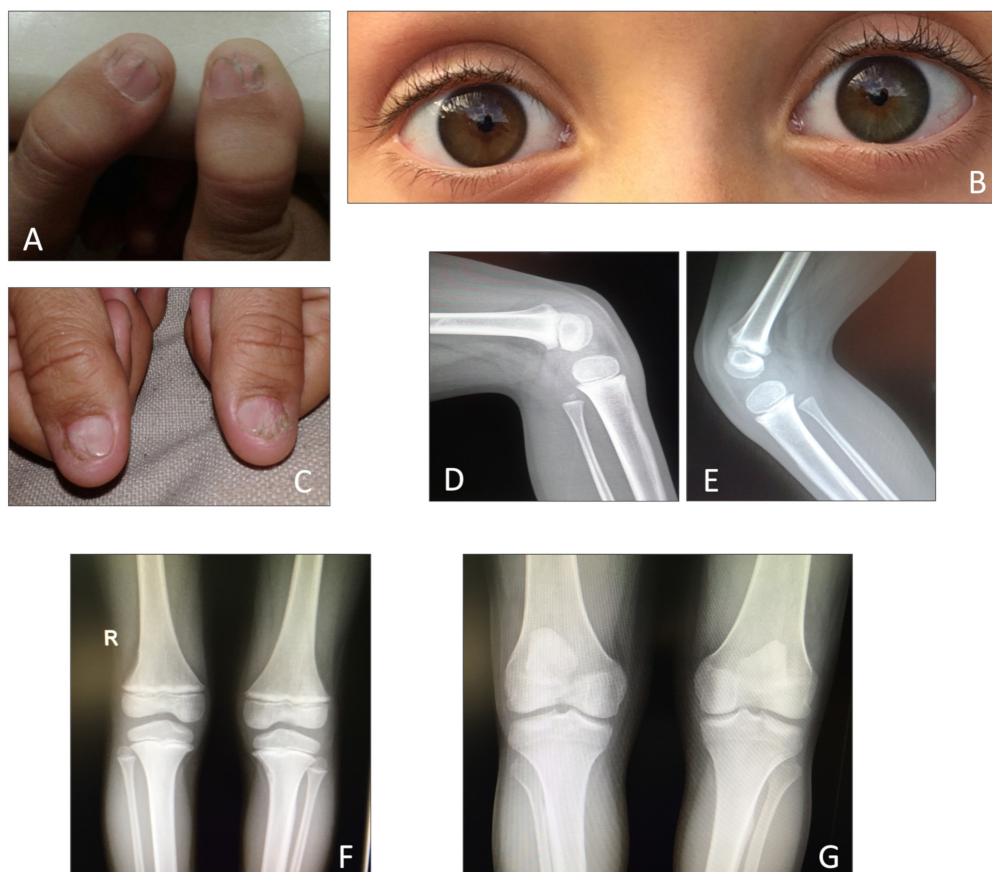
## 2. Subjects and Methods

### 2.1. Patients

The index case, a 7-year-old boy, was the second child of a non-consanguineous marriage, who presented at birth with a vertical astragalus foot, joint hypermobility and muscular hypotonia. In successive consultations, nail dystrophy and Lester's sign in his right eye were observed (Figures 1A and 1B). His father also showed clinical signs compatible with NPS including dystrophic nails and bilateral elbow dysplasia, not achieving extension of elbows. Consequently, clinical and genetic studies were also requested for his father and his 9-year-old brother. This clinical study included radiology, renal ultrasound, and urine analysis. Informed written consent for the genetic analysis was obtained from the patients' parents. The Ethics Committee of Nuestra Señora de Candelaria University Hospital (Santa Cruz de Tenerife, Spain) approved this study.

### 2.2. Mutation analysis

After obtaining written informed consent, genomic DNA of patients and relatives was extracted from peripheral blood samples using the Gen Elute Blood Genomic DNA kit (Sigma-Aldrich, St. Louis, MO,



**Figure 1. Clinical features of patients.** (A and C) Dystrophic nails in index case and his father, respectively; (B) Lester's sign in index case; (D and E) Absent patella in index case; (F) Absent patella the patient's brother; (G) Presence of kneecaps in the father.

USA) following the manufacturer's instructions. The eight coding exons and the flanking intronic sequences of *LMX1B* were amplified by polymerase chain reaction (PCR) using intronic primers previously described (17). PCR products were purified with the QIAquick PCR purification kit (Qiagen, Hilden, Germany) and sequenced with the BigDye Terminator v3.1 Cycle Sequencing Kit (Applied Biosystems, Foster City, CA, USA). Sequence reactions were purified with Performa<sup>®</sup> DTR Gel Filtration Cartridges (EdgeBio BioSystems, Gaithersburg, Maryland, USA), and analyzed on a 3500 Series Genetic Analyzer (Applied Biosystems, Foster City, CA, USA). Mutations were identified by comparison to the *LMX1B* reference sequence NG\_017039.1 (<https://www.ncbi.nlm.nih.gov>), and confirmed by sequencing additional independent amplification products. We examined several databases, including Exome Aggregation Consortium (ExAC, <http://exac.broadinstitute.org>), 1000 Genomes Project (TGP, <http://www.internationalgenome.org>), Human Gene Mutation Database (HGMD, <http://www.hgmd.cf.ac.uk/ac/index.php>) and ClinVar (<https://www.ncbi.nlm.nih.gov/clinvar/>), to verify that the mutation detected in our patients was not a common variant and to confirm that it was novel. Online bioinformatics tools PolyPhen (<http://genetics.bwh.harvard.edu/pph2>), SIFT ([http://sift.bii.a-star.edu.sg/www/SIFT\\_seq\\_submit2.html](http://sift.bii.a-star.edu.sg/www/SIFT_seq_submit2.html)), Align GVGD (<http://agvgd.iarc.fr>), MutPred2 (<http://mutpred.mutdb.org>) and Mutation Taster (<http://www.mutationtaster.org>) were used to predict the pathogenicity of the mutation. Default settings were used for all programs. The protein sequence of human LMX1B (isoform 2 containing 402 amino acids) was obtained from the NCBI database (accession number NP\_001167618.1). Human Splicing Finder v3.1 (HSF) was used to predict the effect of the new mutation on exonic splicing regulatory sequences (<http://www.umd.be/HSF3/>).

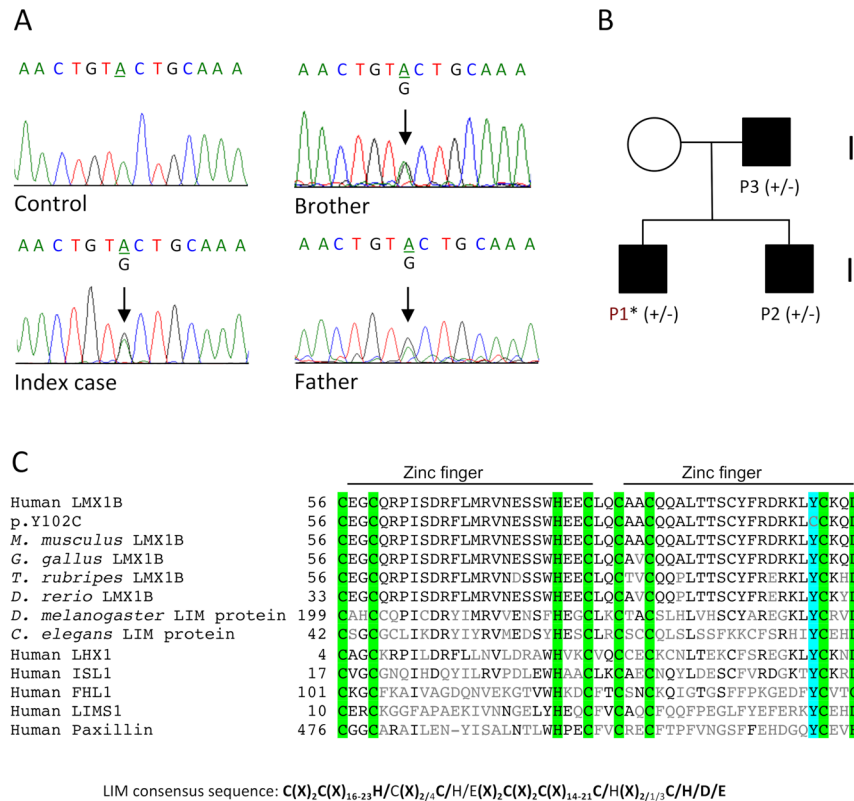
### 3. Results and Discussion

Radiological examination revealed bilateral agenesis of the patellae in the index case and his brother, and confirmed the existence of kneecaps in their father (Figures 1D to 1G). Urinalysis did not reveal proteinuria in any of the cases, and renal ultrasound examination showed normal kidneys. Therefore, affected members of the family studied here displayed the typical characteristics of NPS including dysplastic nails, the most constant characteristic of NPS, absent patella and elbow dysplasia. However, they showed varying phenotypes as has been described for other families with NPS (13,14,17). The index case presented nail dysplasia and bilateral agenesis of patellae, while his brother only showed absence of patella, and his father displayed dystrophic nails and elbow dysplasia. The proband showed the Lester's sign, which is present

in around 50% of the NPS patients (1). Approximately 10% of NPS patients will develop glaucoma and a smaller percentage has ocular hypertension (1), but these features were lacking for now in this family. The prognosis of NPS patients is established by their renal manifestations, which occur in approximately 40% of NPS patients and ranges from asymptomatic proteinuria to occasional renal failure (2,4). These manifestations may take many years to appear. Renal involvement was not present in any of our patients. It is worth noting that the mutation identified in our study is located in the LIM-A domain, since NPS patients with *LMX1B* mutations affecting the homeodomain showed significantly higher frequency of nephropathy and higher values of proteinuria than those carrying mutations in the LIM domains (2). The factors responsible for the phenotypic heterogeneity in NPS are basically unknown but it is possible that there are genetic variants that modify the interaction of LMX1B with other proteins giving rise to different clinical manifestations. Only a few cases of NPS have been reported in Spain (18-20) and, in general, pediatricians are not familiar with this disease.

Sequencing analysis of the proband revealed a novel heterozygous mutation, c.305A>G, in exon 2 of *LMX1B* (Figure 2A). The mutation segregated with the disease in the family; it was also present in heterozygous state in the patient's brother and father (Figures 2A and 2B). This new *LMX1B* variant implies the substitution of tyrosine 102 for cysteine, p.(Y102C), and it was not found in databases such as ExAC, TGP, HGMD and ClinVar. To obtain an estimation of the mutation pathogenicity, we evaluated the change of tyrosine for cysteine at position 102 of the LMX1B protein with five different bioinformatics tools. All of them predicted that the mutation affects protein function (Table 1). This amino acid residue is highly conserved among eight different species (human, mouse, cat, chicken, fugu, pufferfish, zebra fish, fruit fly and worm) and among other LIM proteins (Figure 2C). The novel variant described here was submitted to ClinVar and was included with the accession number NM\_001174146.1 (<https://www.ncbi.nlm.nih.gov/clinvar/variation/587694>).

LIM-homeodomain proteins contain two cysteine-rich zinc-binding LIM domains near the amino terminus that are involved in interactions with other cofactors for cooperative transcriptional regulation of genes in a tissue-specific manner (21). Most LMX1B mutations affect the LIM domains or the homeodomain by altering amino acids that are essential for the binding of zinc or amino acids essential for DNA binding, respectively. Functional studies of a few *LMX1B* mutations have shown reduced transcriptional activity and decreased DNA-binding ability, resulting in the partial or complete loss of LMX1B function (6,15,22). These and other results suggest that the main pathogenic



**Figure 2. Mutation analysis of the family with NPS and evolutionary conservation of tyrosine 102.** (A) Electropherograms showing the partial sequence of *LMX1B* exon 2 in affected members of the family and a control. The arrows indicate the location of the identified heterozygous missense mutation c.305A>G, p.(Y102C). (B) Pedigree of the family. Filled and open symbols represent affected and normal individuals, respectively. Circles and squares indicate females and males, respectively. The index case is marked with an asterisk. -, mutant *LMX1B* allele; +, normal *LMX1B* allele. (C) Protein alignment showing that tyrosine 102 (highlighted in light blue) in the LIM-A domain of *LMX1B* is totally conserved among species and among other LIM proteins suggesting that it is important for the zinc finger structure and function. The eight highly conserved zinc-binding residues (cysteine, histidine and aspartic acid) are highlighted in green. Since the less conserved spacer regions vary in size, non-conserved amino acid residues G87 and I88 of *C. elegans* LIM protein, S33, T56, C57 of *ISL1*, Y117 and V135 of *FHL1*, S26, G55 of *LIMS1*, and P521 of *paxillin*, were deleted to facilitate the alignment of the zinc-binding residues. Black and grey letters represent conserved and nonconserved residues, respectively. The LIM consensus sequence is shown at the bottom of the figure, where X represents any amino acid (21).

**Table 1. Bioinformatics predictions of pathogenicity for mutation p.(Y102C)**

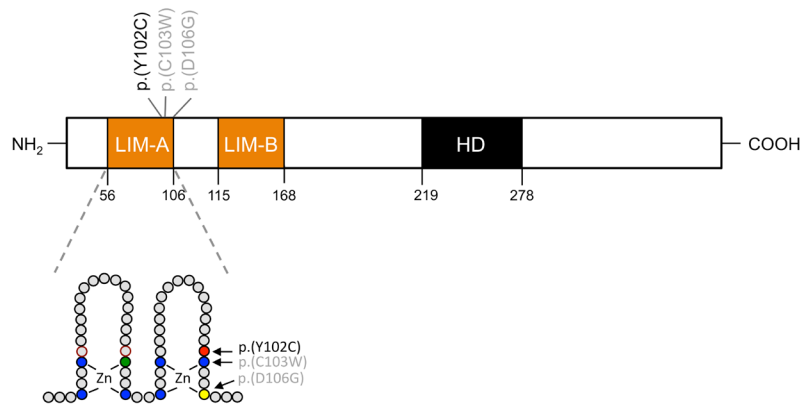
Tool	PolyPhen-2 <sup>1</sup>	SIFT <sup>2</sup>	Align GVG <sup>3</sup>	MutPred <sup>4</sup>	MutationTaster <sup>5</sup>
Score	0.991	0.00	Class C65	0.919	194
Prediction	Probably damaging	Affects function	Affects function	Deleterious	Disease causing

<sup>1</sup>The PolyPhen-2 score ranges from 0.0 to 1.0. Values closer to 1.0 are more confidently predicted to be deleterious. Variants with scores in the range 0.0 to 0.15 are predicted to be benign, while variants with scores in the range 0.15 to 1.0 are possibly damaging. Variants with scores in the range 0.85 to 1.0 are more confidently predicted to be damaging. <sup>2</sup>The SIFT probability score ranges from 0 to 1.0. Amino acid substitutions with scores < 0.05 are predicted to be deleterious (scores closer to 0 are more confidently predicted to be deleterious). Variants with scores in the range 0.05 to 1.00 are predicted to be tolerated (scores very close to 1.0 are more confidently predicted to be tolerated). <sup>3</sup>Align-GVG classifies variants in seven risk grades (C0, C15, C25, C35, C45, C55, C65) with C65 most likely to interfere with function and C0 least likely. <sup>4</sup>The general score of MutPred2 ranges from 0.0 and 1.0, with a higher score indicating a greater propensity to be pathogenic. <sup>5</sup>The MutationTaster score ranges from 0.0 to 215. It is taken from the Grantham Matrix for amino acid substitutions and reflects the physicochemical difference between the original and the mutated amino acid.

mechanism causing NPS is haploinsufficiency (7,15,23,24). Tyrosine residue 102 of *LMX1B* is located in the second zinc-binding motif of the LIM-A domain, next to cysteine 103, which is one of the four amino acid residues involved in zinc binding (Figure 3). Several missense mutations in the LIM-A domain of *LMX1B*, including p.(C103W) and p.(D106G), that lead to substitutions of amino acids essential for the

binding of zinc have been identified in NPS patients (Figure 3) (14,16). Similar mutations affecting highly conserved cysteine residues within the LIM-B domain have also been reported (3,13). Therefore, we suggest that p.(Y102C) disturbs the binding of zinc and the function of *LMX1B*.

Previous studies in other genes have shown that some exonic mutations can be damaging by altering pre-



**Figure 3. Schematic representation of LMX1B.** The two protein-binding LIM domains (orange boxes) located near the N terminus and the DNA binding homeodomain (HD) (black box) are shown. The position of mutation p.(Y102C) identified in this study is indicated. Two previously reported missense mutations, p.(C103W) and p.(D106G), affecting zinc-binding residues of the LIM-A domain are also indicated (grey letters). Numbers beneath the boxes denote amino acid residues. Below is a diagram showing the structure of the two zinc fingers present in LIM-A. Blue, green and yellow circles indicate conserved zinc binding residues, cysteine, histidine and aspartic acid, respectively. The mutated residue, tyrosine 102, is identified in red. Non-conserved residues are represented as grey circles. Mutations p.(C103W) and p.(D106G) are also indicated.

mRNA splicing (25-27). Since mutation c.305A>G is located in exon 2, twenty-two nucleotides away from the donor splice site of intron 2, we analyzed its potential effect on splicing. Results obtained with HSF showed that the A to G change (underlined) creates a potential exonic splicing silencer (5'-ACTGTGCTG) and could, therefore, alter *LMX1B* pre-mRNAsplicing. This will have to be investigated further using RNA from a patient or cell lines expressing the mutant *LMX1B*.

In conclusion, we identified a novel *LMX1B* missense mutation, c.305A>G, p.(Y102C), in a family with NPS. We suggest that this mutation, located in the highly conserved LIM-A domain of *LMX1B*, affects the formation of a zinc-binding motif and disturbs the interaction of the protein with other transcription factors. Mutation p.(Y102C) expands the spectrum of *LMX1B* mutations. The identification of missense mutations within the LIM domains may help elucidate the function of these domains.

### Acknowledgements

We thank the patient and his family for their cooperation. This work was supported by grant PI17/00153 integrated in the Plan Nacional de I+D+I 2013-2016 and co-financed by the ISCIII-Subdirección General de Evaluación y Fomento de la Investigación and the European Regional Development Fund "Another way to build Europe".

### References

1. Witzgall R. Nail-patella syndrome. *Pflugers Arch.* 2017; 469:927-936.
2. Bongers EM, Huysmans FT, Levtschenko E, *et al.* Genotype-phenotype studies in nail-patella syndrome show that *LMX1B* mutation location is involved in the risk of developing nephropathy. *Eur J Hum Genet.* 2005; 13:935-946.
3. Ghomid J, Petit F, Holder-Espinasse M, Jourdain AS, Guerra J, Dieux-Coeslier A, Figeac M, Porchet N, Manouvrier-Hanu S, Escande F. Nail-Patella Syndrome: Clinical and molecular data in 55 families raising the hypothesis of a genetic heterogeneity. *Eur J Hum Genet.* 2016; 24:44-50.
4. Harita Y, Kitanaka S, Isojima T, Ashida A, Hattori M. Spectrum of *LMX1B* mutations: From nail-patella syndrome to isolated nephropathy. *Pediatr Nephrol.* 2017; 32:1845-1850.
5. Iannotti CA, Inoue H, Bernal E, Aoki M, Liu L, Donis-Keller H, German MS, Permutt MA. Identification of a human *LMX1* (*LMX1.1*)-related gene, *LMX1.2*: Tissue-specific expression and linkage mapping on chromosome 9. *Genomics.* 1997; 15:520-524.
6. Dreyer SD, Zhou G, Baldini A, Winterpacht A, Zabel B, Cole W, Johnson RL, Lee B. Mutations in *LMX1B* cause abnormal skeletal patterning and renal dysplasia in nail patella syndrome. *Nat Genet.* 1998; 19:47-50.
7. Vollrath D, Jaramillo-Babb VL, Clough MV, McIntosh I, Scott KM, Lichter PR, Richards JE. Loss-of-function mutations in the LIM-homeodomain gene, *LMX1B*, in nail-patella syndrome. *Hum Mol Genet.* 1998; 7:1091-1098.
8. Chen H, Lun Y, Ovchinnikov D, Kokubo H, Oberg KC, Pepicelli CV, Gan L, Lee B, Johnson RL. Limb and kidney defects in *Lmx1b* mutant mice suggest an involvement of *LMX1B* in human nail patella syndrome. *Nat Genet.* 1998; 19:51-55.
9. Pressman CL, Chen H, Johnson R.L. *LMX1B*, a LIM homeodomain class transcription factor, is necessary for normal development of multiple tissues in the anterior segment of the murine eye. *Genesis.* 2000; 26:15-25.
10. Morello R, Zhou G, Dreyer SD, Harvey SJ, Ninomiya Y, Thorner, PS Miner, JH, Cole W, Winterpacht A, Zabel B, Oberg KC, Lee B. Regulation of glomerular basement membrane collagen expression by *LMX1B* contributes to renal disease in nail patella syndrome. *Nat Genet.* 2001; 27:205-208.
11. Miner JH, Morello R, Andrews KL, Li C, Antignac C, Shaw AS, Lee B. Transcriptional induction of slit



- diaphragm genes by *Lmx1b* is required in podocyte differentiation. *J Clin Invest*. 2002; 109:1065-1072.
12. Burghardt T, Kastner J, Suleiman H, *et al.* *LMX1B* is essential for the maintenance of differentiated podocytes in adult kidneys. *J Am Soc Nephrol*. 2013; 24:1830-1848.
  13. McIntosh I, Dreyer SD, Clough MV, Dunston JA, Eyaid W, Roig CM, Montgomery T, Ala-Mello S, Kaitila I, Winterpacht A, Zabel B, Frydman M, Cole WG, Francomano CA, Lee B. Mutation analysis of *LMX1B* gene in nail-patella syndrome patients. *Am J Hum Genet*. 1998; 3:1651-1658.
  14. Hamlington JD, Jones C, McIntosh I. Twenty-two novel *LMX1B* mutations identified in nail patella syndrome (NPS) patients. *Hum Mutat*. 2001; 18:458.
  15. Sato U, Kitanaka S, Sekine T, Takahashi S, Ashida A, Igarashi T. Functional characterization of *LMX1B* mutations associated with nail-patella syndrome. *Pediatr Res*. 2005; 57:783-788.
  16. Clough MV, Hamlington JD, McIntosh I. Restricted distribution of loss-of-function mutations within the *LMX1B* genes of nail-patella syndrome patients. *Hum Mutat*. 1999; 14:459-465.
  17. Lee BH, Cho TJ, Choi HJ, Kang HK, Lim IS, Park YH, Ha IS, Choi Y, Cheong HI. Clinico-genetic study of nail-patella syndrome. *J Korean Med Sci*. 2009; 24:82-86.
  18. Millá E, Hernan I, Gamundi MJ, Martínez-Gimeno M, Carballo M. Novel *LMX1B* mutation in familial nail-patella syndrome with variable expression of open angle glaucoma. *Mol Vis* 2007; 27:639-648.
  19. Alvarez-Martin N, Gamundi MJ, Hernan I, Carballo M, Luis-Yanes MI, Garcia-Nieto V. Nail-patella syndrome. A case with a de novo mutation in the *LMX1B* gene not previously described. *Nefrologia*. 2013; 33:585-586.
  20. Figueroa-Silva O, Vicente A, Agudo A, Baliu-Piqué C, Gómez-Armayones S, Aldunce-Soto MJ, Inarejos Clemente EJ, Navallas Irujo M, Gutiérrez de la Iglesia D, González-Enseñat MA. Nail-patella syndrome: Report of 11 pediatric cases. *J Eur Acad Dermatol Venereol*. 2016; 30:1614-1617.
  21. Kadmas JL, Beckerle MC. The LIM domain: From the cytoskeleton to the nucleus. *Nat Rev Mol Cell Biol*. 2004; 5:920-931.
  22. Mukai M, Fujita H, Umegaki-Arao N, Sasaki T, Yasuda-Sekiguchi F, Isojima T, Kitanaka S, Amagai M, Kubo A. A familial case of nail patella syndrome with a heterozygous in-frame indel mutation in the LIM domain of *LMX1B*. *J Dermatol Sci*. 2018; 90:90-93.
  23. Dreyer SD, Morello R, German MS, Zabel B, Winterpacht A, Lunstrum GP, Horton WA, Oberg KC, Lee B. *LMX1B* transactivation and expression in nail-patella syndrome. *Hum Mol Genet*. 2000; 9:1067-1074.
  24. Bongers EM, de Wijs IJ, Marcelis C, Hoefsloot LH, Knoers NV. Identification of entire *LMX1B* gene deletions in nail patella syndrome: Evidence for haploinsufficiency as the main pathogenic mechanism underlying dominant inheritance in man. *Eur J Hum Genet*. 2008; 16:1240-1244.
  25. Cartegni L, Chew SL, Krainer AR. Listening to silence and understanding nonsense: Exonic mutations that affect splicing. *Nat Rev Genet*. 2002; 3:285-298.
  26. Gonzalez-Paredes FJ, Ramos-Trujillo E, Claverie-Martin F. Defective pre-mRNA splicing in *PKD1* due to presumed missense and synonymous mutations causing autosomal dominant polycystic disease. *Gene*. 2014; 546:243-249.
  27. Suarez-Artiles L, Perdomo-Ramirez A, Ramos-Trujillo E, Claverie-Martin F. Splicing Analysis of Exonic OCRL Mutations Causing Lowe Syndrome or Dent-2 Disease. *Genes (Basel)*. 2018; 4:9. pii: E15.

(Received December 6, 2018; Revised January 11, 2019; Accepted January 15, 2019)

## The expression of EpCAM in extramammary Paget's disease

Saori Yamada-Kanazawa<sup>§</sup>, Yukino Tasaki<sup>§</sup>, Ikko Kajihara<sup>\*</sup>, Ryoko Sakamoto,  
Saki Maeda-Otsuka, Hironobu Ihn

Department of Dermatology and Plastic Surgery, Faculty of Life Sciences, Kumamoto University, Honjo, Kumamoto, Japan.

**Summary** Extramammary Paget's disease (EMPD) is a rare skin malignant tumor. The prognosis of EMPD with distant metastasis is poor, however an effective therapy has not yet established. Recently, EpCAM (epithelial cell adhesion molecule, CD326) has attracted attention as both prognostic marker and therapeutic target in several cancers. Besides, EpCAM is an important surface marker of circulating tumor cell (CTC) in the collection of CTC. Thus, the purpose of our study was to examine the expression levels of EpCAM and evaluate the correlation between its intensity of EpCAM and the clinical characteristics of EMPD. The expression of EpCAM in EMPD was examined using immunohistochemistry. Skin samples were obtained from 32 patients with EMPD. We found that almost all EMPD tissues (90.6%, 29/32) were positive for EpCAM. Furthermore, the staining intensity of EpCAM protein negatively correlated with the presence of distant metastasis. Overexpression of EpCAM in EMPD cells suggests that EpCAM may be a novel therapeutic target and the research of CTC may be newly developed in EMPD. Based on these findings, EpCAM may be a meaningful molecule in EMPD.

**Keywords:** Extramammary Paget's disease, epithelial cell adhesion molecule, CD326, distant metastasis, immunohistochemistry, circulating tumor cell

### 1. Introduction

Extramammary Paget's disease (EMPD) is a rare skin malignant tumor that shows erythematous plaques and erosions in pubic or axillary lesions. Although the prognosis of EMPD with distant metastasis is poor, an effective therapy has not yet established. Thus, there is need to investigate molecular targets for EMPD.

Recently, EpCAM (epithelial cell adhesion molecule, CD326) has attracted attention as both prognostic marker and therapeutic target in several cancers (1). EpCAM is involved in not only cell adhesion but also cellular signaling, cell migration, proliferation and differentiation (2). EpCAM is overexpressed in many malignant tumors, e.g. prostatic, ovarian, urothelial

and breast carcinoma (2). The anti-EpCAM antibody (catumaxomab) has been authorized for treatment of malignant ascites in cancer patients (3). On the other hand, EpCAM has been reported to be a tumor suppressive protein in certain types of cancers such as oral, rectal and endometrial carcinoma (4-6) although the molecular mechanism of the tumor suppressive function of EpCAM in several cancers has not been found yet (7). Moreover, EpCAM is an important surface marker of circulating tumor cell (CTC) (8), and the CellSearch system (CTC detector of circulating EpCAM<sup>+</sup>CD45<sup>-</sup> cells) is approved by FDA (9).

Thus, the purpose of our study was to examine the expression levels of EpCAM and evaluate the correlation between its intensity of EpCAM and the clinical characteristics of EMPD.

### 2. Materials and Methods

#### 2.1. Patients

Skin samples were obtained from 32 patients with EMPD. All patients with EMPD were diagnosed by clinical and histopathological findings. These

Released online in J-STAGE as advance publication February 25, 2019.

<sup>§</sup>These authors contributed equally to this work.

<sup>\*</sup>Address correspondence to:

Dr. Ikko Kajihara, Department of Dermatology and Plastic Surgery, Faculty of Life Sciences, Kumamoto University, Honjo1-1-1, Kumamoto 860-8556, Japan.

E-mail: kajiderma@gmail.com

findings were comprehensively analyzed by more than five dermatologists. Paraffin-embedded sections were collected from patients undergoing operation or mapping biopsy in Kumamoto University Hospital between 2011 and 2018. All patients underwent imaging tests for the presence or absence of metastasis. Most of EMPD patients were treated with definitive operation or radiotherapy although EMPD patients with unresectable and metastasis received chemotherapy or palliative radiotherapy. Institutional review board approval and written informed consent were obtained according to the Declaration of Helsinki.

### 2.2. Immunohistochemical staining

Paraffin-embedded sections were mounted on glass slides, then dewaxed in Clear Plus (FALMA, Japan) and rehydrated in graded alcohols. Immunohistochemistry (IHC) antigen activation was performed by incubation with antigen retrieval solution (pH9, Nichirei, Japan) for 10 min at 121°C. The sections were then incubated overnight with the antibody against EpCAM (Dako, CA, USA, 1:50) at 4°C. The immunoreactivity was visualized with DAB. We used the following grading system: - negative staining, + for slight staining, ++ for strong staining, as described previously (10).

### 2.3. Statistical analysis

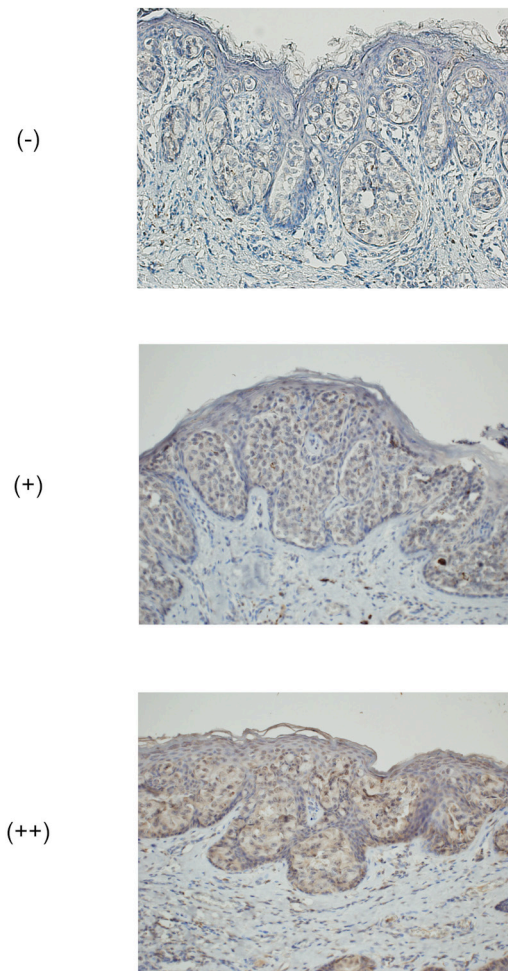
Correlations were assessed according to Fisher's correlation coefficient and its statistical analyses were performed using GraphPad Prism version 7 (MDF, Tokyo, Japan). A p value less than 0.05 was considered significant.

## 3. Results and Discussion

First, we investigated EpCAM protein expression in EMPD using immunohistochemical staining. Immunohistochemistry of EpCAM revealed that EMPD cells had more intense staining than the normal keratinocytes cells in same tissue samples (Figure 1). Almost all EMPD tissues (90.6%, 29/32) were positive for EpCAM.

Next, to analyze the relationship between the intensity of EpCAM protein expression levels and clinical findings of patients with EMPD, we classified semi-quantitative scoring of immunoreactivity ([-], [+], [++]) (Figure 1 and Table 1). The expression of EpCAM in EMPD patients with distant metastasis was significantly decreased compared to that in patients without distant metastasis ( $p = 0.036$ ), although it did not correlate any other clinical findings (age:  $p = 0.365$ , sex:  $p = 0.087$ , the degree of invasiveness:  $p = 0.826$ , the presence of lymph node metastasis:  $p = 0.132$ ) (Table 2).

In this study, we presented two novel findings: first,



**Figure 1. Representative images of semi-quantitative scoring using the immunohistochemical staining (EpCAM).** ([-], [+], [++]) (original magnification  $\times 200$ ). -: negative staining, +: slight staining, ++: strong staining.

we found that almost all EMPD tissues were positive for EpCAM. Furthermore, the staining intensity of EpCAM protein negatively correlated with the presence of distant metastasis.

EpCAM is overexpressed in several cancers such as adenocarcinomas of colon, stomach, pancreas and lung (11-13). As with these cancers, our results showed that almost all EMPD tissues were positive for EpCAM. It suggests that EpCAM may be a novel therapeutic target in EMPD.

Overexpression of EpCAM was associated with an advanced stage of the disease and linked to worse overall survival in certain tumor types (2). On the other hand, EpCAM could be a tumor suppressive protein in certain types of cancers (7). In gastric cancer, EpCAM appeared to be associated with a more favorable prognosis (14). Besides, the loss of EpCAM in rectal cancer was associated with the reduction of cell-cell adhesion and the augmentation of migration function (15). Our results showed that the EpCAM expression negatively correlated with the presence of distant metastasis. Taken together, these findings suggest that

**Table 1. Expression of EpCAM protein and clinical manifestations in the patients with extramammary Paget's disease**

Case	Age	Sex	The degree of invasiveness	Lymph node metastasis	Distant metastasis	EpCAM
1	85	Male	invasive	+	-	++
2	78	Male	<i>in situ</i>	-	-	++
3	77	Male	<i>in situ</i>	-	-	+
4	76	Female	<i>in situ</i>	-	-	-
5	81	Male	<i>in situ</i>	-	-	++
6	66	Male	invasive	-	-	+
7	76	Female	<i>in situ</i>	-	-	+
8	68	Male	invasive	+	+	-
9	71	Female	<i>in situ</i>	-	-	++
10	72	Male	invasive	+	-	+
11	69	Male	<i>in situ</i>	-	-	+
12	69	Male	<i>in situ</i>	-	-	+
13	71	Female	<i>in situ</i>	-	-	+
14	78	Male	<i>in situ</i>	+	+	-
15	87	Female	<i>in situ</i>	-	-	++
16	63	Female	<i>in situ</i>	-	-	++
17	82	Male	<i>in situ</i>	-	-	+
18	67	Female	<i>in situ</i>	-	-	+
19	78	Female	<i>in situ</i>	-	-	++
20	76	Male	<i>in situ</i>	-	-	+
21	78	Male	<i>in situ</i>	-	-	+
22	74	Male	invasive	+	+	+
23	64	Female	<i>in situ</i>	-	-	++
24	54	Male	<i>in situ</i>	-	-	+
25	64	Male	<i>in situ</i>	-	-	+
26	65	Female	<i>in situ</i>	-	-	++
27	60	Male	<i>in situ</i>	-	-	+
28	76	Female	<i>in situ</i>	-	-	+
29	90	Female	<i>in situ</i>	-	-	+
30	59	Female	<i>in situ</i>	-	-	+
31	83	Male	invasive	+	-	+
32	94	Female	invasive	-	-	++

**Table 2. Correlation between the semiquantitative evaluation of the EpCAM protein and patient characteristics**

Items	EpCAM			p values
	-	+	++	
Age (from 54 to 94)				0.365
Sex				0.087
male (n = 18)	2	13	3	
female (n = 14)	1	6	7	
The degree of invasiveness				0.826
invasive (n = 6)	1	3	2	
microinvasion (n = 1)	0	1	0	
<i>in situ</i> (n = 25)	2	15	8	
Lymph node metastasis				0.132
- (n = 26)	1	16	9	
+ (n = 6)	2	3	1	
Distant metastasis				0.036
- (n = 29)	1	18	10	
+ (n = 3)	2	1	0	

the reduced expression of EpCAM may enhance the metastatic ability in EMPD.

Moreover, EpCAM is an important surface marker of CTC (8). Overexpression of EpCAM in EMPD cells may facilitate the research of CTC in EMPD. Based on

these findings, EpCAM may be a meaningful molecule in EMPD although further investigations are needed.

### Acknowledgements

This study was supported in part by a grant for scientific research from the Japanese Ministry of Education, Science, Sports and Culture and by project research from the Japanese Ministry of Health, Labour and Welfare.

### References

- Schnell U, Cirulli V, Giepmans BN. EpCAM: Structure and function in health and disease. *Biochim Biophys Acta.* 2013; 1828:1989-2001.
- Patriarca C, Macchi RM, Marschner AK, Mellstedt H. Epithelial cell adhesion molecule expression (CD326) in cancer: A short review. *Cancer Treat Rev.* 2012; 38:68-75.
- Linke R, Klein A, Seimetz D. Catumaxomab: Clinical development and future directions. *MAbs.* 2010; 2:129-136.
- Hwang EY, Yu CH, Cheng SJ, Chang JY, Chen HM, Chiang CP. Decreased expression of Ep-CAM protein is significantly associated with the progression and prognosis of oral squamous cell carcinomas in Taiwan. *J Oral Pathol Med.* 2009; 38:87-93.
- Gosens MJ, van Kempen LC, van de Velde CJ, van Krieken JH, Nagtegaal ID. Loss of membranous Ep-CAM in budding colorectal carcinoma cells. *Mod Pathol.* 2007; 20:221-232.
- Wen KC, Sung PL, Chou YT, Pan CM, Wang PH, Lee OK, Wu CW. The role of EpCAM in tumor progression and the clinical prognosis of endometrial carcinoma. *Gynecol Oncol.* 2018; 148:383-392.
- Huang L, Yang Y, Yang F, Liu S, Zhu Z, Lei Z, Guo J. Functions of EpCAM in physiological processes and diseases (Review). *Int J Mol Med.* 2018; 42:1771-1875.
- Li Y, Wu S, Bai F. Molecular characterization of circulating tumor cells-from bench to bedside. *Semin Cell Dev Biol.* 2018; 75:88-97.
- Heitzer E, Haque IS, Roberts CES, Speicher MR. Current and future perspectives of liquid biopsies in genomics-driven oncology. *Nat Rev Genet.* 2019; 20:71-88.
- Yamada-Kanazawa S, Kajihara I, Fukushima S, Jinnin M, Masuzawa M, Masuzawa M, Amoh Y, Hoshina D, Abe R, Ihn H. Inhibition of heat shock protein 90 exerts an antitumor effect in angiosarcoma: Involvement of the vascular endothelial growth factor signalling pathway. *Br J Dermatol.* 2017; 177:456-469.
- Went PT, Lugli A, Meier S, Bundi M, Mirlacher M, Sauter G, Dirnhofer S. Frequent EpCam protein expression in human carcinomas. *Hum Pathol.* 2004; 35:122-128.
- Rao CG, Chianese D, Doyle GV, Miller MC, Russell T, Sanders RA Jr, Terstappen LW. Expression of epithelial cell adhesion molecule in carcinoma cells present in blood and primary and metastatic tumors. *Int J Oncol.* 2005; 27:49-57.
- Brezicka T. Expression of epithelial-cell adhesion molecule (Ep-CAM) in small cell lung cancer as defined

- by monoclonal antibodies 17-1A and BerEP4. *Acta Oncol.* 2005; 44:723-727.
14. Warneke VS, Behrens HM, Haag J, Krüger S, Simon E, Mathiak M, Ebert MP, Röcken C. Members of the EpCAM signalling pathway are expressed in gastric cancer tissue and are correlated with patient prognosis. *Br J Cancer.* 2013; 109:2217-2227.
15. Gosens MJ, van Kempen LC, van de Velde CJ, van Krieken JH, Nagtegaal ID. Loss of membranous EpCAM in budding colorectal carcinoma cells. *Mod Pathol.* 2007; 20:221-232.

*(Received January 26, 2019; Revised February 14, 2019; Accepted February 19, 2019)*

## Propranolol and ascorbic acid in control of fibrodysplasia ossificans progressiva flare-ups due to accidental falls

Durval Batista Palhares<sup>1</sup>, Deborah Ribeiro Nascimento<sup>1,2</sup>, Marilene Garcia Palhares<sup>1</sup>, Suzana Lopes Bomfim Balaniuc<sup>1</sup>, Liane de Rosso Giuliani<sup>1</sup>, Paula Cristhina Niz Xavier<sup>1</sup>, José Mauro Goulart Brum<sup>3</sup>, Fabiana Alves<sup>4,5</sup>, Francisco Oliveira Vieira<sup>4,5</sup>, Elaine Maria Souza-Fagundes<sup>4</sup>, Adam Underwood<sup>6</sup>, Amy Milsted<sup>6</sup>, Robson Augusto Souza Santos<sup>4</sup>, Almir Sousa Martins<sup>4,\*</sup>

<sup>1</sup>UFMS/ Faculty of Medicine, Campo Grande, MS, Brazil;

<sup>2</sup>Medical Faculty of Barbacena, José Bonifácio Lafayette de Andrada Foundation, MG, Brazil;

<sup>3</sup>Procter & Gamble Health Care & Global Clinical Sciences, Mason, OH, USA;

<sup>4</sup>UFMG/ Department of Physiology and Biophysics, Belo Horizonte, MG, Brazil;

<sup>5</sup>Centro Universitário Metodista Izabela Hendrix- IMIH, Belo Horizonte, MG, Brazil;

<sup>6</sup>The Walsh University, Division of Mathematics and Sciences, North Canton, OH, USA.

### Summary

Fibrodysplasia ossificans progressiva (FOP) is a rare, intractable and devastating genetic connective tissue disorder characterized by progressive ectopic ossification in the soft tissues and skeleton. Three patients, one teenage girl (P1), one male adult (P2) and one male child (P3), were studied and treated with FOPCON (combined formulation of 14 mg of propranolol and 250 mg of ascorbic acid), given three times per day. P1 started treatment in March 2012, P2 in October 2012 and P3 in July 2015. The clinical follow-up of these three patients, before initiating treatment with FOPCON, showed that FOP flare-ups used to occur frequently and that under FOPCON therapy, none of these patients had flare-ups. The striking feature of this treatment with FOPCON, is that, all three cases suffered accidental falls with documented injuries until complete healing and that where major flare-ups should occur, injuries or sequels, there was none. The present clinical observation shows that ascorbic acid plus the nonspecific beta blocker propranolol can be effectively useful, when administered previously and continually, in the prophylaxis of FOP flare-ups, especially for accidental falls. In this regard, FOPCON could be a prophylactic aid in cases of surgery of patients with FOP, hoping that it may benefit patients from having the severe sequels, characteristic of heterotopic bone formation. All three patients reported, to date, they no longer had flare-ups nor heterotopic ossification and showed normal scar healing.

**Keywords:** Vitamin C, beta blocker, ectopic ossification, FOPCON

### 1. Introduction

Fibrodysplasia ossificans progressiva (FOP, OMIM#135100) is a rare genetic connective tissue

disorder characterized by malformations of the hallux and progressive ectopic ossification in skeletal muscles and soft tissues. It is an autosomal dominant disease and worldwide prevalence is 1 per 2,000,000 births (1). The gene responsible for essential activation of activin receptor type-1 (ACVR1) or activin-like kinase 2 [ALK-2], was discovered in 2006 (2), in patients who had recurrent mutation of codon 206 from arginine to histidine in ACVR1, also named bone morphogenic protein (BMP) type I receptor, for activating the BMP signaling pathway (2,3), and consequently responsible for inherited and sporadic FOP.

Released online in J-STAGE as advance publication February 22, 2019.

\*Address correspondence to:

Dr. Almir Sousa Martins, Departamento de Fisiologia e Biofísica-ICB/UFMG. Av Antonio Carlos, 6627, A4-256, Belo Horizonte, MG, Brazil – 31.270-900.

E-mail: asm2011@ufmg.br

Until today no treatment has been effectively able to control FOP disease. Progress has been achieved in inhibiting ossification, with Palovarotene, a retinoic acid receptor gamma agonist with low potential for side effects (4,5). In the literature there are few other drugs (6-10). Ascorbic acid treatment case reports of FOP were previously described by Palhares *et al.* (1997, 2001 and 2010), showing improvement of symptoms (8), decrease of flare-ups (9) and transient stabilization of crisis (10).

Because FOP disease is prone to flare-ups (11), due to any manipulations, be they accidental trauma, surgeries, dental procedures, intramuscular injections, bacterial or viral infections and stress, it becomes impossible to control flare-ups and heterotopic ossification.

In this regard, as a novelty we report three cases of FOP patients, who had accidental falls, and were benefited by a combination therapy of ascorbic acid and propranolol (FOPCON), without flare-ups or sequels.

## 2. Materials and Methods

The present study is a comparison of three FOP patients, one teenage girl (P1), one male adult (P2) and one male child (P3). They were clinically evaluated and followed up by medical professionals, including a pediatrician, a medical geneticist, odontologists and academic researchers at the University Hospital of The Federal University of Mato Grosso do Sul and Federal University of Minas Gerais. Patients were studied and treated with FOPCON 14.250 (Fibrodysplasia ossificans progressiva combined formulation of 14 mg of propranolol and 250 mg of ascorbic acid), given three times per day. P1 started treatment in March 2012, P2 in October 2012 and P3 in July 2015 and are part of a project approved by the University Hospital Ethics Committee (CAAE: 60117916.0.0000.0021), upon Free and Informed Consent Form, signed by patients and their caregivers (12).

P1 was born April 2002, with diagnosis within 34 months old. Her manifestation of FOP was first described by Palhares (2010) (8). P2, born April 1984, showed clinical manifestations at 30 months of age, reported somewhere else (9,10). This patient achieved adulthood and received several conventional treatments with anti-inflammatories and corticosteroids during crisis and received significant therapy. Although, otherwise healthy, the patient evolved with some control of the disease including ossification and significant loss of mobility as an adult FOP patient. On October 2012, the patient was added onto FOPCON therapy only. P3 was born September 2009, with bilateral *hallux valgus* and his first acute FOP crisis occurred when he was 7 months old.

Before FOPCON, P1 and P2 were pretreated with ascorbic acid (AA), and obtained transient stabilization of crises, subsequently propranolol was introduced combined with AA. Both cases were previously described by Palhares (8-10), featuring previous

classical treatment medicines compared with the present FOPCON treatment results.

On the other hand, P3 was treated directly with FOPCON formulation. Thus, the results obtained in P3 were compared to their previous history (recorded in clinical practice) of frequent falls or traumas and consequent limitation of movement, despite the use of conventional treatments.

## 3. Results and Discussion

To our knowledge, the present report is the first demonstrating three cases of FOP patients, who had accidental falls with injuries, and were safe using a novel combination therapy (FOPCON) of AA and propranolol (PP), and showing, so far, no flare-ups or sequels from those injuries (Table 1).

P1 suffered a fall when running in the schoolyard leading to bruising, and a cut in the upper left eyebrow area, in June 2014, about two years after starting treatment. The skin was cleaned, repaired, and sutured with seven stitches. During the recovery phase after suture, there was no flare-up (Figure 1), and tissue showed normal resolution and scar healing. P1 has been maintained on FOPCON since that time and has shown good drug tolerance, normal blood pressure and no side effects. However, in 2017, P1 began taking FOPCON on an irregular schedule, and inadvertently, at the same time, the teen had a tattoo on her right arm drawn in December 2017, which consequently led to a large flare-up on each upper limb, compromising the hand on the same side of the tattoo. After re-introduction of FOPCON, the flare-up regressed, and she is doing active physiotherapy to improve the movements of the fingers, which were initially totally frozen. Currently, P1 is taking medication correctly and is clinically stabilized without any flare-up.

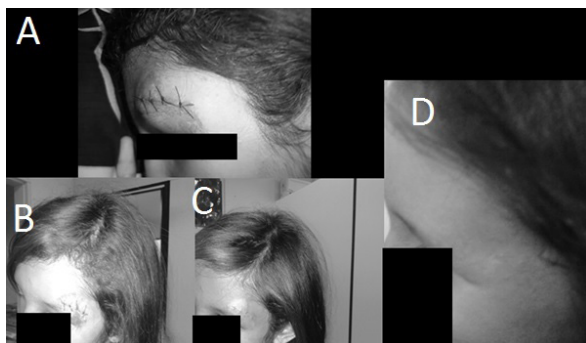P2, previously treated with AA plus bisphosphonates, was added to a new treatment with FOPCON in October 2012. Since then, P2 has had no flare-up. Though P2 has vague complaints associated to pre-existing numerous ectopic ossifications, his overall status has improved significantly. Patient's blood pressure has always remained within normal limits, ranging 100/60 mmHg. By February 2015, during domestic transportation, P2 fell from a stretcher and suffered an injury in the soft tissue of his left leg, with good healing and did not present flare-up (Figure 2). Since he started treatment with FOPCON, he has never had any FOP crisis, showing clinical improvement, better neck movement, better sleep, and excellent mouth opening, which gradually improved, since initially it was only 30%. Now it's six years and four months of treatment with improvements, although he began his treatment under a bedridden condition.

P3 started FOPCON treatment in July 2015. P3 showed good tolerability to FOPCON without any

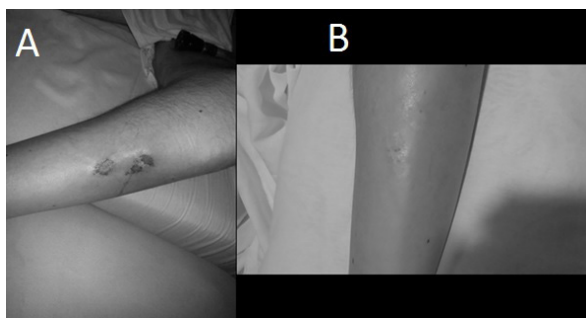
**Table 1. Clinical characteristics, previous treatments, current treatment characteristics and results for each individual case**

Identification	First flare-up (years/month)	Previous treatment	Current physical situation	FOPCON treatment onset	Current treatment*	Accident	Results
P1	2 / 5	Anti-inflammatory, bisphosphonates, vitamin C	Walks with little limitation	March 2012	FOPCON 14.250 3x per day	March 2014 – fall; seven stitches in the upper left eyebrow  December 2017** - tattoo in right arm	No flare-up, normal resolution and scar healing.  Flare-up in the upper limbs, regressing after re-introduction FOPCON, without ectopic bone.
P2	2 / 6	Corticosteroids, analgesics, bisphosphonates, vitamin C	Bedridden	Oct. 2012	FOPCON 14.250 3x per day	February 2015 – fall; injury in the soft tissue of left leg	No flare-up; good healing.
P3	0 / 7	Corticosteroids, analgesics, anti-inflammatory	Walks with limitation	July 2015	FOPCON 14.250 3x per day	Several falls; stitches in forehead; humerus fracture	No flare-up; good recovery.

\*Dosage: FOPCON 14.250 = 14 mg of propranolol and 250 mg ascorbic acid; \*\*irregular schedule FOPCON.

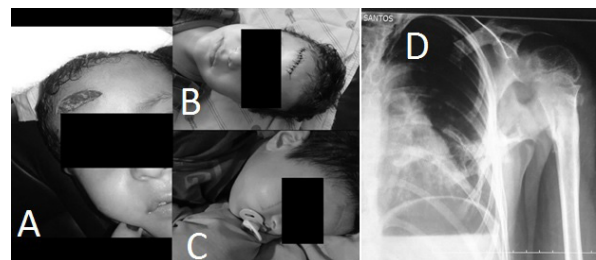

**Figure 1. FOP patient 1 (P1) under treatment with FOPCON.** P1 suffered a fall in the schoolyard, it was necessary to make seven stitches in the eyebrow region. (A), (B), (C) and (D) show the scar healing chronological evolution over a period of about 30 days. Scar healing evolved without FOP flare-up.



**Figure 2. FOP patient 2 (P2) under treatment with FOPCON.** P2 fell from the stretcher, injuring his left leg (A). The healing was natural under treatment with FOPCON. Ten months after trauma, there was no evidence of ectopic bone on the scar (B) site or elsewhere.

adverse events and normal blood pressure for his age. He has suffered several falls due to considerable limitations in the range of motion of limbs, mainly



**Figure 3. FOP patient 3 (P3) under treatment with FOPCON.** Forehead severe injury, due to a fall, while playing at home. Under FOPCON treatment, the healing process (A), (B) and (C) was normal. There was no ectopic bone formation at the wound site or elsewhere in the body. Later, P3 had a second fall, with left humerus fracture (D). The healing process showed normal bone healing with the orthopedic treatment and did not develop disease crisis.

in the upper limbs' abduction. Typically, physical injuries or trauma in patients with severe FOP such as P3, would cause acute crisis with appearance of inflammation and swelling. However, P3 so far, shows no sign of FOP crisis. His healing evolved naturally without ectopic bone formation (Figure 3A, 3B and 3C). Later, P3 had another fall, resulting in a left humerus fracture, nevertheless, showed good recovery (Figure 3D). Recently, P3 had a left knee trauma and he had a joint effusion and pain but without FOP crisis, however parents were advised to seek orthopedic treatment.

No effective medical therapy is known for FOP, bisphosphonates and corticosteroids are only beneficial during flare-up, but do not prevent formation of ectopic bone (6). Distinct case reports reveal reasonable disease control with etidronate, including ectopic bone reduction, however, they agree that long-term use leads to osteopenia, contraindicating its continuous use



(13,14). Other groups have proposed drugs already in a clinical trial phase, however, their efficacy and side effects can be questioned (15,16). The use of AA only (11) as well as AA plus intravenous bisphosphonates (10), despite some improvement in the patients, did not avoid disease progression. Therefore, although many treatments have been reported, the disease may have shown slight improvement, but disease progression has been observed, as well as recurrence of flare-ups.

FOP crisis always appears spontaneously or due to local trauma that leads to severe inflammatory responses of connective tissue and intramuscular edema in such ways that biopsies of FOP patient's tissues, with inflammatory processes, have shown formation of endochondral osteogenesis in heterotopic sites, causing ectopic ossification (11). Consequently, attempts to remove heterotopic ossification surgically have been mostly unsuccessful, since surgical trauma itself can provoke disease flare-ups. With the intent to block formation of new tissue, anti-angiogenic drugs such as thalidomide and Squalamine, have been used in FOP (17) for inhibition of new blood vessel formation, but failed to resolve the manifestation of FOP signs and symptoms.

The major rationale for the usage of beta-blockers comes with reports that heterotopic bone is formed along with new neurons and that enervation is important in the onset of bone morphogenesis in FOP (18). Furthermore, endochondral bone formation requires angiogenesis, so the use of propranolol may be a limiting factor in this process, because without angiogenesis, there would be no vessels to form bones (19) and beta-blockers are anti-angiogenic, while propranolol usage has shown effectiveness in the treatment of hemangiomas (20,21). How FOPCON acts and interferes with bone morphogenic protein (BMP) signaling, is not known, but BMP signaling pathway is controlled by receptors types 1 and 2 in a cascade regulated at multiple levels where FOPCON may modulate.

The function of propranolol is not explained solely by these factors. Propranolol is one of the drugs indicated for cardiovascular and other clinical applications such as migraine, anxiety and glaucoma (22), and is a nonselective beta-blocker antagonist, which blocks the action of both adrenaline and noradrenaline adrenergic receptors such as  $\beta_1$  and  $\beta_2$ . Also, propranolol can act as a partial agonist of one or more serotonin receptors (22,23).

Reports on the therapeutic combination of AA and PP concomitantly are rare, which includes atrial fibrillation treatment (24) and clinical pharmacokinetics study of drug interactions (25). Nevertheless, AA has recently been shown to regulate expression of a battery of genes (26), but PP has not yet been investigated in this regard. *In vivo* AA modulates the expression of inflammatory genes (27) and *in vitro*, modulates target genes related to

FOP pathology (28).

The autonomous nervous system has been lately, strongly linked to inflammatory processes, specially the sympathetic system as a pro-inflammatory branch (29). FOP and its symptoms involve the autonomic nervous system and neurohumoral mechanisms. A neurogenic pain in FOP patients has been recently described and to be of a more intense degree than reported for the general population (30). The pain and emotional symptoms of FOP must be targeted as neuro-inflammatory symptoms for clinical treatment. Our three FOP patient cases improved considerably, being free from body pain after FOPCON.

#### 4. Conclusion

In conclusion, the composition of AA and PP can be effectively useful, if administered previously and continually, for prophylaxis of flare-ups due to accidental falls. FOPCON may benefit patients in future surgical procedures by preventing them from having the severe sequels characteristic of heterotopic bone formation. All three patients reported, to date, no longer had flare-ups nor heterotopic ossification and showed normal scar formation without sequae. The monitoring of younger patients like P3, who still do not have all the heterotopic bone formation in advanced stages that immobilize most patients in bed, will allow us to see, in the coming years, the effect of FOPCON blocking the deplorable evolution of FOP.

#### Acknowledgements

Project supported by: Instituto de Assistência em Pesquisa, Educação e Saúde – IAPES, CG, MS, Brazil and CAPES. Present report is a project of FOP treatment study approved by University Hospital Ethics Committee (CAAE: 60117916.0.0000.0021). FOPCON is under Invention Patent: pharmaceutical compositions of propranolol and ascorbic acid and uses – Protocol number: BR1020150324928.

#### References

1. Pignolo RJ, Shore EM, Kaplan FS. Fibrodysplasia ossificans progressiva: Clinical and genetic aspects. *Orphanet J Rare Dis.* 2011; 6:80.
2. Shore EM, Xu M, Feldman GJ, *et al.* A recurrent mutation in the BMP type I receptor ACVR1 causes inherited and sporadic fibrodysplasia ossificans progressiva. *Nat Genet.* 2006; 38:525-527.
3. Morales-Piga A, Bachiller-Corral J, Trujillo-Tiebas MJ, Villaverde-Hueso A, Gamir-Gamir ML, Alonso-Ferreira V, Vázquez-Díaz M, Posada de la Paz M, Ayuso-García C. Fibrodysplasia ossificans progressiva in Spain: Epidemiological, clinical, and genetic aspects. *Bone.* 2012; 51:748-755.
4. Shimono K, Tung W, Macolino C, Chi A.H, Didizian JH, Mundy C, Chandraratna RA, Mishina Y, Enomoto-

- Iwamoto M, Pacifici M, Iwamoto M. Potent inhibition of heterotopic ossification by nuclear retinoic acid receptor- $\gamma$  agonists. *Nat Med*. 2011; 17:454-460.
5. Clementia initiates Phase 2 extension study of palovarotene in FOP patients. *News Medical Life Sciences*. 2014. <http://www.news-medical.net/news/20141027/Clementia-initiates-Phase-2-extension-study-of-palovarotene-in-FOP-patients.aspx> (accessed May 05, 2018).
  6. Kaplan FS, Shore EM, Pignolo RJ (eds). The medical management of fibrodysplasia ossificans progressiva: current treatment considerations. International Clinical Consortium on Fibrodysplasia Ossificans Progressiva. 2011; 4:1-100. <http://fundacionfop.org.ar/wp-content/uploads/2015/09/the-medical-management.pdf> (accessed May 05, 2018).
  7. Katagiri T, Tsukamoto S, Nakachi Y, Kuratani M. Recent topics in fibrodysplasia ossificans progressiva. *Endocrinol Metab (Seoul)*. 2018; 33:331-338.
  8. Palhares DB, Leme LM, Naka EM, Melnikov P. Fibrodysplasia ossificans progressiva: Oral ascorbate and intravenous bisphosphonate during flare-ups. *J Musculoskelet Pain*. 2010; 18:270-276.
  9. Palhares DB. Myositis ossificans progressive. *Calcif Tissue Int*. 1997; 60:394.
  10. Palhares DB, Leme LM. A perspective on the control of myositis ossificans progressiva. *J Pediatr (Rio J)*. 2001; 77:431-444. (in Portuguese)
  11. Kaplan FS, Tabas JA, Gannon FH, Finkel G, Hahn GV, Zasloff MA. The histopathology of fibrodysplasia ossificans progressiva. An endochondral process. *J Bone Joint Surg Am*. 1993; 75:220-230.
  12. Palhares MG, Nascimento DR, Giuliani LR, Xavier PCN, Nascimento VA, Martins AS, Palhares DB. Clinical reports of 31 Brazilian case presentations with fibrodysplasia ossificans progressiva. *Int J Dev Res*. 2018; 8:18315-18320.
  13. Nucci A, Queiroz LD, Santos AD, Camargo EE, Moura-Ribeiro MV. Fibrodysplasia ossificans progressiva: Case report. *Arq Neuropsiquiatr*. 2000; 58:342-347.
  14. Fonseca JE, Branco JC, Reis J, Evangelista T, Tavares V, Gomes AR, Queiroz MV. Fibrodysplasia ossificans progressiva: Report of two cases. *Clin Exp Rheumatol*. 2000; 18:749-752.
  15. Kaplan FS, Zeitlin L, Dunn SP, Benor S, Hagin D, Mukaddam MA, Pignolo RJ. Acute and chronic rapamycin use in patients with fibrodysplasia ossificans progressiva: A report of two cases. *Bone*. 2018; 109:281-284.
  16. Lees-Shepard JB, Nicholas SE, Stoessel SJ, Devarakonda PM, Schneider MJ, Yamamoto M, Goldhamer DJ. Palovarotene reduces heterotopic ossification in juvenile FOP mice but exhibits pronounced skeletal toxicity. *Elife*. 2018; 7.pii:e40814.
  17. Kaplan FS, Glaser DL, Pignolo RJ, Shore EM. A new era for fibrodysplasia ossificans progressiva: A druggable target for the second skeleton. *Expert Opin Biol Ther*. 2007; 7:705-712.
  18. Salisbury E, Sonnet C, Heggeness M, Davis AR, Olmsted-Davis E. Heterotopic ossification has some nerve. *Crit Rev Eukaryot Gene Expr*. 2010; 20:313-324.
  19. Sommers Smith SK, Smith DM. Beta blockade induces apoptosis in cultured capillary endothelial cells. *In Vitro Cell Dev Biol Anim*. 2002; 38:298-304.
  20. Léauté-Labrèze C, Taïeb A. Efficacy of beta-blockers in infantile capillary haemangiomas: the physiopathological significance and therapeutic consequences. *Ann Dermatol Venereol*. 2008; 135:860-862. (in French)
  21. Lowenthal DT, Saris SD, Packer J, Haratz A, Conry K. Mechanisms of action and the clinical pharmacology of beta-adrenergic blocking drugs. *Am J Med*. 1984; 77:119-127.
  22. Black JW, Crowther AF, Shanks RG, Smith LH, Dornhorst AC. A new adrenergic beta receptor antagonist. *Lancet*. 1964; 1:1080-1081.
  23. Yamamura HI, Horita A. Effect of propranolol on the blockade of alpha adrenergic receptors. *J Pharmacol Exp Ther*. 1968; 164:82-89.
  24. Eslami M1, Badkoubeh RS, Mousavi M, Radmehr H, Salehi M, Tavakoli N, Avadi MR. Oral ascorbic acid in combination with beta-blockers is more effective than beta-blockers alone in the prevention of atrial fibrillation after coronary artery bypass grafting. *Tex Heart Inst J*. 2007; 34:268-274.
  25. Gonzalez J, Valdivieso A, Calvo R, Rodríguez-Sasiaín JM, Jimenez R, Aguirre C, du Souich P. Influence of vitamin C on the absorption and first pass metabolism of propranolol. *Eur J Clin Pharmacol*. 1995; 48:295-297.
  26. Belin S, Kaya F, Burtey S, Fontes M. Ascorbic Acid and gene expression: another example of regulation of gene expression by small molecules? *Curr Genomics*. 2010; 11:52-57.
  27. Canali R, Ntarelli L, Leoni G, Azzini E, Comitato R, Sancak O, Barella L, Virgili F. Vitamin C supplementation modulates gene expression in peripheral blood mononuclear cells specifically upon an inflammatory stimulus: A pilot study in healthy subjects. *Genes Nutr*. 2014; 9:390.
  28. Ribeiro DR, Palhares DB, Del Puerto HL, Alves F, Martins SF, Vieira FO, Brum JMG, Giuliani LR, Palhares MG, Souza-Fagundes EM, Underwood A, Milsted A, Santos RAS, Martins AS. Ascorbic acid modulates the expression of genes involved in heterotopic ossification. *NBC-Periódico Científico do Núcleo de Biociências*. 2017; 7:81-97.
  29. Olofsson PS, Rosas-Ballina M, Levine YA, Tracey KJ. Rethinking inflammation: neural circuits in the regulation of immunity. *Immunol Rev*. 2012; 248:188-204.
  30. Kitterman JA, Strober JB, Kan L, Rocke DM, Cali A, Peeper J, Snow J, Delai PL, Morhart R, Pignolo RJ, Shore EM, Kaplan FS. Neurological symptoms in individuals with fibrodysplasia ossificans progressiva. *J Neurol*. 2012; 259: 2636-2643.

(Received September 8, 2018; Revised January 26, 2019; Accepted February 4, 2019)

## Retroperitoneal fibrosis associated with orbital pseudotumor without evidence of IgG4: A case report with review of literature

María-Teresa Pérez-Sanz\*, Eva Cervilla-Muñoz, Jaime Alonso-Muñoz, Almudena Marcelo-Ayala, María-Dolores Pulfer, Francisco Galeano-Valle

Internal Medicine Department, Hospital General Universitario Gregorio Marañón, Madrid, Spain.

### Summary

Retroperitoneal fibrosis (RPF) is a rare disease characterized by chronic inflammation and periaortic fibrosis that affects retroperitoneal structures and often entraps the ureters. The idiopathic form has an incidence of 0.1-1.3/100,000 person-years. A substantial percentage of patients with idiopathic retroperitoneal fibrosis (IRF), as well as patients with orbital pseudotumor, is associated with IgG4-related disease (IgG4-RD). It is not clear what percentage of IRF is related to the spectrum of the IgG4-RD or if both represent different stages of the same disease (especially in those cases with extra-retroperitoneal involvement). Histopathological features such as storiform fibrosis, obliterative phlebitis and tissue infiltration of IgG4-positive plasma cells (ratio IgG4<sup>+</sup>/IgG higher than 0.4) are essential to identify this association. Extra-retroperitoneal manifestations are often presented among patients with IgG4-related RPF. About 90% of cases of IRF have a good prognosis, with adequate response to treatment. We report a case of a 59-year-old woman with history of past occupational asbestos exposure and smoking habit. She was diagnosed with RPF, periaortitis and orbital pseudotumor, without histopathologic or serologic features of IgG4-related disease. This could be related to the fact that the biopsy was done in a place with scarce inflammatory activity but high fibrosis. We want to emphasize the usual need to perform several biopsies or to be guided by positron emission tomography (PET-CT) in order to achieve a histopathological confirmation. Our case differs from the main IgG4 international cohorts in the involvement of the retroperitoneum, aorta and eye, whereas the usual involvement includes liver, pancreas, lymph nodes and salivary glands. Our patient had lower IgG4 serum levels than those described in the international cohorts. However, they were similar to those of the Spanish population.

**Keywords:** Idiopathic retroperitoneal fibrosis, IgG4-related disease, orbital pseudotumor, periaortitis, asbestos

### 1. Introduction

Idiopathic retroperitoneal fibrosis (IRF) is a rare immune-mediated condition with systemic involvement that affects retroperitoneal structures; it is characterized by chronic inflammation and periaortic fibrosis. The incidence rate is 0.1-1.3/100,000 person-years with a median age at diagnosis of 40-60 years and affects

males more frequently (1-3). The majority of cases (70%) of retroperitoneal fibrosis (RPF) are idiopathic, whereas one third of cases are secondary to other causes such as drugs, cancer or infections (2,4). Its diagnosis can be challenging due to the wide range of associated diseases, and the need to eliminate secondary causes. Although it has a benign course in the majority of cases, it can also lead to severe complications. Therefore, it is important to treat it at an early stage and monitor it very closely (4).

Although it has been recently included in the spectrum of IgG4-related disease (IgG4-RD), this association has not been proved in all patients. IgG4-RD is a systemic fibroinflammatory condition

\*Address correspondence to:

Dr. María-Teresa Pérez-Sanz, Internal Medicine Department, Hospital General Universitario Gregorio Marañón, Calle Doctor Esquerdo, 46, 28007, Madrid, Spain.  
E-mail: perezsanmaite@gmail.com

characterized by the infiltration of IgG4-positive plasma cells in the affected tissues (mostly pancreas, salivary glands and lymph nodes, although it can affect a large number of tissues) (3,5,6).

We present the case of a 59-year-old woman diagnosed with retroperitoneal fibrosis. In this particular patient, orbital pseudotumor presented as an extra-retroperitoneal lesion, which would point to an IgG4-related disease, but the histo-pathological and laboratory findings suggested otherwise.

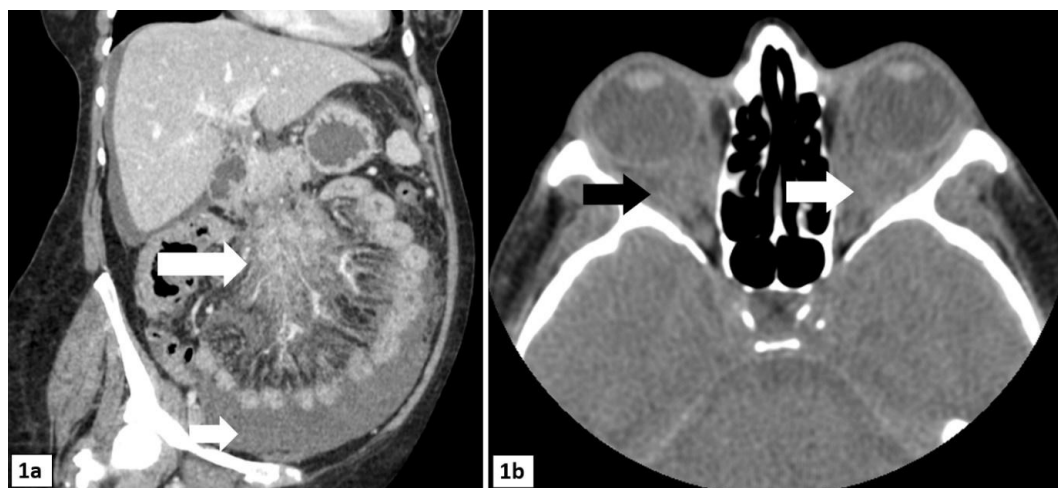
## 2. Case Report

A 59-year-old woman with a history of occupational asbestos exposure and a smoking habit came to the Emergency department with a 1-month history of abdominal pain, vomiting, hyperthermia, weakness and 5 kg weight loss. She had progressively developed bilateral proptosis over the last year. Upon arrival at the hospital, physical examination showed fever (37.8°C), tachycardia, bilateral restriction on upgaze, mild ascites and a palpable mesogastric abdominal mass. Laboratory tests revealed the following alterations: leukocytes 17,200/ $\mu$ L (neutrophils 10,900/ $\mu$ L, monocytes 5,100/ $\mu$ L, lymphocytes 1,100/ $\mu$ L), Hemoglobin 10.7 g/dL, platelets 404,000/ $\mu$ L, elevated C reactive protein (CRP) and erythrocyte sedimentation rate (ESR) (12.7 mg/dL and 44 mm respectively), albumin levels 3.1 g/dL and ferritin 392  $\mu$ g/L. Other biochemistry blood parameters including glucose, liver enzymes, renal function, serum angiotensin-converting enzyme, electrolytes and 24-hour urine analysis were normal. Peripheral blood smear confirmed monocytosis. Blood cultures were sterile. Urine infection caused by *Escherichia coli* was detected in the urine culture. Despite appropriate antibiotic therapy, fever persisted. Concentrations of B, T-CD8<sup>+</sup> and NK lymphocytes were low. Low levels of serum IgG (516 mg/dL) and elevated values of IgE (192

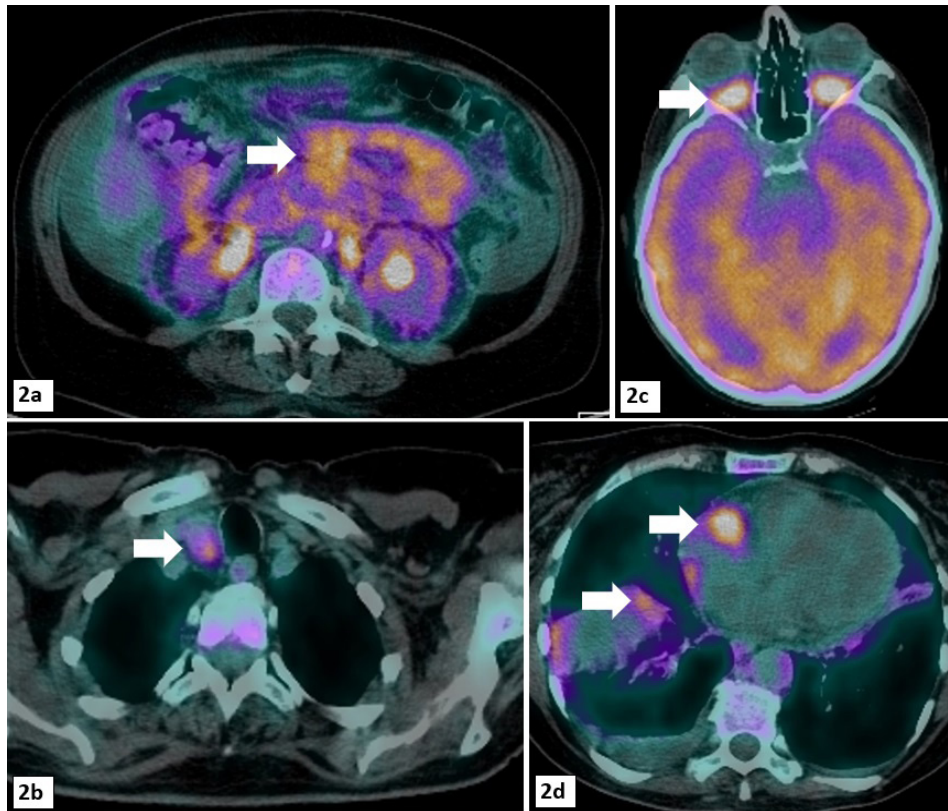
mg/dL) were observed. IgG4 (0.18 g/dL), IgA and IgM were within normal range.

A computerized tomography (CT) showed a soft tissue mass around the aortic arch, the descending aorta and iliac arteries that infiltrated the retroperitoneum, the mesenteric vessels and the inferior vena cava and caused bilateral obstructive uropathy. An inflammatory infiltration of orbital soft tissues suggestive of orbital inflammatory pseudotumor was also described (Figure 1). There was no evidence of lymph node enlargement. Positron emission tomography (PET-CT) revealed inflammatory activity of the infiltrative retroperitoneal, periaortic and orbital masses as well as in pericardium, right atrium, pleura and perinephric space (Figure 2). Further studies including transthoracic echocardiogram, large bone radiography, upper endoscopy and colonoscopy, were normal. Tumoral biomarkers and autoantibodies were negative, with the exception of elevated CA-125 values (114 U/mL). Core needle biopsy of the retroperitoneal mass demonstrated a fibroblastic proliferation and IgG plasma cells without atypia on a collagenous and adipose tissue stroma. Immunohistochemical (IHC) staining did not reveal IgG4 or other cell line markers. These findings were compatible with the diagnosis of idiopathic retroperitoneal fibrosis (Figure 3).

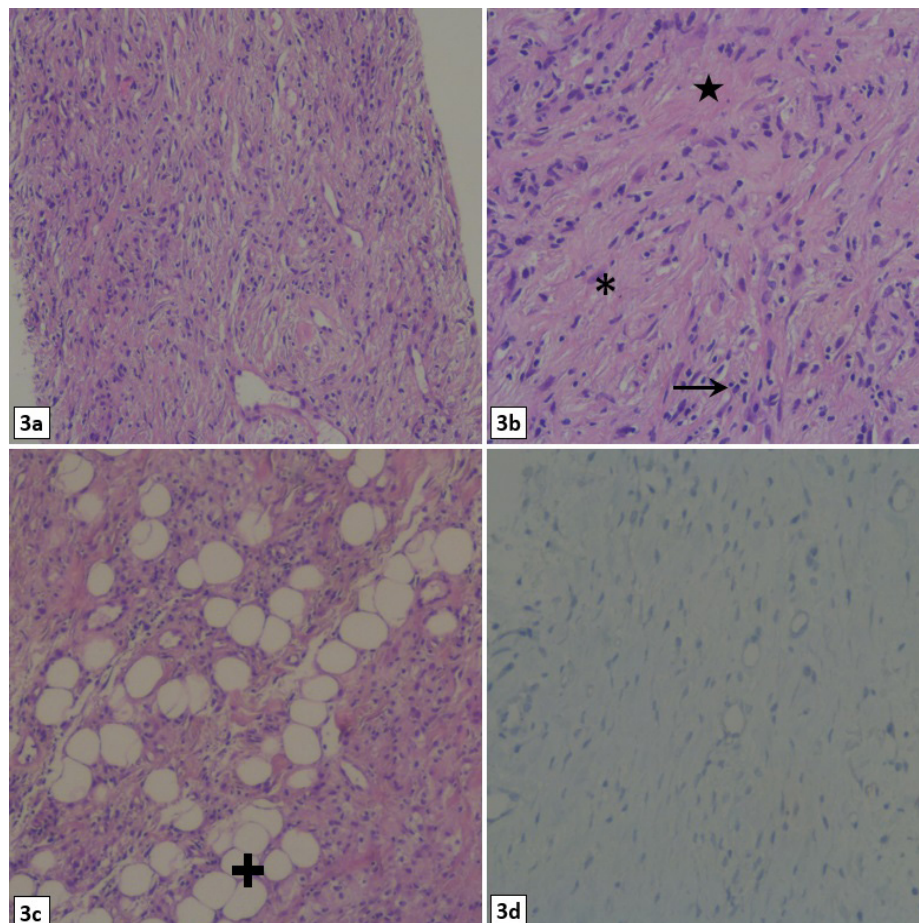
The patient needed parenteral nutrition due to oral feeding intolerance. She also developed obstructive uropathy and it was necessary to implant an ureteral stent. Treatment with high doses of intravenous methylprednisolone (1 g/day) for 3 days was started with a significant clinical improvement with resolution of proptosis, fever, vomiting, ascites and abdominal pain as well as with normalization of the acute phase reactants (APR). The initial corticosteroids bolus were followed by lower doses of oral prednisone. She was discharged 2 weeks after the beginning of the immunosuppressive treatment to be seen on an



**Figure 1.** (1a), Abdominal CT. Mesenteric and retroperitoneal infiltrative mass surrounding mesenteric vessels and the inferior vena cava (big arrow). Free intraperitoneal fluid (small arrow). (1b), Cranial TC. orbital inflammatory pseudotumor (arrows).



**Figure 2. PET-TC.** Inflammatory activity (arrows) of the infiltrative retroperitoneal (2a), periaortic (2b) and orbital masses (2c) as well as pericardium, right atrium, pleura (2d) and perirenal space.



**Figure 3. (3a, 3b and 3c),** fibroblastic proliferation (\*) and plasma cells (arrow) without atypia on a collagenous (star) and adipose tissue stroma (cross). **(3d),** Negative immunohistochemical staining for Ig G4.

outpatient basis. 3 days after that the patient had clinical deterioration and was admitted to intensive care unit with an abdominal sepsis due to urinary tract infection and pseudomembranous colitis. Treatment with broad-spectrum antibiotics and vasoactive drugs was initiated. Unfortunately, the patient did not respond to the treatment and evolved with multiple organ failure (hepatic, renal and encephalopathy) and was deceased after one week.

### 3. Discussion

RPF, also named Ormond's disease, is a rare process characterized by chronic inflammation and periaortic fibrosis that affects retroperitoneal structures. The incidence rate is 0.1-1.3/100,000 person-years with a median age at diagnosis of 40-60 years and affects males more frequently (1). The pathophysiological mechanisms of this disease remain unknown. Some studies suggest that an immune-mediated mechanism might be involved, based on the frequent association of RPF with autoimmune disorders (2,3). The majority of cases (70%) of RPF are idiopathic whereas one third of cases are secondary to other causes such as drugs (derivatives of ergot alkaloids, methyldopa, beta-blockers and biological agents); metastatic neoplasm with a desmoplastic response (e.g. carcinoma of the prostate, breast, lung or genitourinary tract among others); carcinoid tumors; infections such as tuberculosis, histoplasmosis and actinomycosis or primary retroperitoneal malignancies such as sarcomas or lymphomas (2,4). Other processes such as secondary amyloidosis, surgical interventions, abdominal trauma, barium enemas, radiotherapy, mesenteric panniculitis and particular forms of histiocytosis – specially Erdheim-Chester disease (ECD) – have also been described (2,7-9). Some studies have concluded that asbestos or tobacco exposures are strong risk factors for the development of idiopathic retroperitoneal fibrosis (IRF) (10).

IgG4-RD is a relatively new clinical entity, which can be described as a systemic fibroinflammatory condition with variable organ involvement characterized by the infiltration of IgG4-positive plasma cells in the affected tissues (3). Up to 50% of patients with IgG4-RD usually have a history of chronic allergic conditions. It can affect virtually any territory and the territories most frequently affected are pancreas, salivary glands and lymph nodes (5). The diagnosis of this entity is based on clinical, serologic and pathological studies. It is widely thought that IRF belongs to the spectrum of IgG4-RD (6). Nevertheless, there are some major points that continue to be a cause for debate. The differences in clinical manifestations, response to treatment and prognosis between IgG4-related and -unrelated IRF are not known very well, and therefore they need to be investigated with larger

prospective studies. As we do not know what their differences and similarities are, we can not know what proportion of patients can be "IgG4-related". Therefore, most authors use anatomopathological and IHC criteria to classify them (storiform fibrosis, obliterative phlebitis and tissue infiltration of IgG4-positive plasma cells). The comparison between the two groups seems to associate more frequently with the presence of extra-retroperitoneal manifestations to IgG4-related IRF (3).

Clinical manifestations are similar in the different forms of RPF and often initially nonspecific. The definitive diagnosis is usually delayed until there is significant organ damage. At the time of diagnosis most cases frequently present with obstructive uropathy and altered renal function. The most frequent symptom is abdominal pain. Systemic symptoms are frequent and include malaise, fatigue, nausea, vomiting, anorexia, myalgia and loss of weight. Lower extremity edema, deep vein thrombosis, mesenteric ischemia, claudication of upper and lower extremities, scrotal swelling, varicocele, hydrocoele or secondary arterial hypertension are complications that appear as a result of the compression of lymphatic and blood vessels (2,3,11). Clinical features and laboratory findings are nonspecific, therefore IRF is a diagnosis of exclusion (3).

Most patients have increased levels of CRP and ESR and its monitoring can be useful to evaluate the clinical course of the disease, although it has limited prognostic value. Other laboratory findings are chronic inflammatory anemia, leukocytosis, eosinophilia and decreased glomerular filtration rate. The urinary sediment is most often normal (2,4). Evaluation of antinuclear antibodies (ANAs), anti-neutrophil cytoplasmic antibodies, anti-thyroid microsomal antibodies, and antithyroglobulin antibodies is necessary. ANAs are positive in 60% of cases and autoimmune thyroiditis is the autoimmune disease most frequently associated (12). Serum IgG4 concentrations are elevated in approximately 60-70% of patients with IgG4-related IRF (10).

Imaging studies play a key role in the diagnosis. While ultrasonography is useful for the identification of hydronephrosis or aneurysmatic aortic dilatation, CT is considered the gold standard for the diagnosis. It can show the presence of homogeneous tissue isodense to muscle, surrounding the lower abdominal aorta and the iliac arteries, and often enveloping other intra-abdominal structures. It also allows to rule out secondary causes (13). MRI usually provides better definition of IRF (14). PET-CT is recommended to evaluate the extension, activity and evolution of this entity. PET-CT demonstrates higher uptake in active phases of the evolution, whereas advanced phases are characterized by marked fibrosis and therefore the uptake is lower. It guides the best management option allowing to decide between immunosuppressive treatment and decompression surgery (15).

**Table 1. Characteristics of IgG4-RD cohorts from China, US, Italy, Spain and Japan**

Items	Hong Kong, China (n = 20) (2/0)	Massachusetts, US (n = 125) (2/1)	Milan, Italy (n = 41) (2/2)	Spain (n = 55) (2/3)	Hokuriku region, Japan (n = 235) (2/4)	Beijing, China (n = 118) (2/5)
Male	42 (76.4%)	76 (60.8%)	26 (63.4%)	38 (69.1%)	189 (80.4%)	82 (69.5%)
Age (years)	62 (27-86)	55 (24-83)	62 (55-67)	53 (41-64)	67 (35-86)	53 (19-80)
Organ involvement						
Retroperitoneum	7 (12.7%)	23 (18.4%)	8 (19.5%)	15 (27.27%)	9 (4%)	31 (26%); retroperitoneal fibrosis and periaortitis
Hepatobiliary and pancreatic system	26 (47.3%)	24 (19.2%)	Pancreas: 17 (41.5%); biliary tree: 4 (9.8%)	Pancreas: 9 (16.36%)	Pancreas: 142 (60%); biliary tree: 31 (13%)	Pancreas: 45 (38.1%); sclerosing cholangitis: 21 (17.8%)
Aorta	NA	14 (11.2%)	4 (9.75%)	4 (7.27%)	28 (20%)	NA
Salivary gland	24 (43.6%)	Submandibular: 35 (28%); parotid: 21 (16.8%)	8 (19.5%)	9 (16.36%)	81 (34%)	76 (64.4%)
Lymph node	8 (14.5%)	34 (27.2%)	5 (12.2%)	2 (1.81%)	34 (14%)	77 (65.3%)
Eye	8 (14.5%)	28 (22.4%)	Orbit: 3 (7.3%); lacrimal glands: 2 (4.9%)	Orbital pseudotumor: 12 (21.82%); lacrimal glands: 8 (14.55%)	Orbit: 9 (4%); 1 lacrimal glands: 53 (23%)	Orbital pseudotumor: 10 (8.5%); lacrimal glands: 60 (50.8%)
Lung	7 (12.7%)	22 (17.6%)	1 (2.4%)	4 (7.27%)	31 (13%)	32 (27.1%)
Renal system	2 (3.6%)	15 (12%)	1 (2.4%)	4 (7.27%)	54 (23%)	29 (24.6%)
Central nervous system	1 (1.8%)	Meninges: 3 (2.4%)	Meninges: 3 (7.3%)	Meninges: 2 (3.64%)	NA	NA
Skin/soft tissue	1 (1.8%)	2 (1.6%)	NA	NA	NA	5 (4.2%)
No. of involved organ systems	1.7 (1-5)	2.3 (1-7)	1.51 (1-3)	NA	NA	NA
Multiorgan involvement	NA	41 (39.78%) n = 103	17 (41.46%)	36 (47.3%)	136 (58%)	93 (78.8%)
Serum IgG4 (mg/dL)	660.5 (116-2100) n = 48	216.56 (28-817) n = 105	284 (132-545)	163.90 (30.8-1145-2)	470 (22-4150) n = 229	1521.8
Total IgG (mg/dL)	2202.1 (1080-5900) n = 43	1339.58 (868-2114) n = 93	NA	NA	NA	2300
IgG4/IgG ratio	0.29 (0.04-0.65) n = 43	NA	NA	104.29	NA	0.38
Histopathological confirmation	40 (72.7%)	125 (100%)	30 (73.2%)	55 (100%)	150 (64%)	64 (54.2%)
Treatment						
Glucocorticoids	37 (67.3%)	64 (51.2%); 86% improved; 77% non-remission	36 (87.8%); 70.73% remission; 29.27% non-remission	47 (85.5%); 43.6% complete response; 43.7% partial response (< 50% of regression)	167 (71%); 24% non remission; 10% mortality	114 (96.6%)
Surgery	19 (34.5%)	50 (40%)	4 (9.75%)	16 (29.1%)	21 (9%)	71 (60.2%); glucocorticoids and other immunosuppressants
Other	12 (21.81%); other immunosuppressants	16 (13%); urethral and hepatobiliary stents	10 (24.39%); hepatobiliary stent	19 (34.5%); other immunosuppressants	NA	NA

IgG4-RD: IgG4-related disease; NA = not available.

Anatomopathological study of biopsy samples is necessary to rule out secondary causes and to establish a definitive diagnosis, especially when imaging techniques do not show characteristic IRF findings. Biopsy samples reveal both a fibrous tissue (type I collagen, fibroblasts and myofibroblasts) and a variably inflammatory infiltrate (lymphocytes, macrophages, plasma cells, and more rarely eosinophils) organized into perivascular and diffuse patterns. In the perivascular pattern, aggregated lymphocytes surround the small retroperitoneal vessels and usually have a central core of B cells and a periphery of CD4<sup>+</sup> and CD8<sup>+</sup> T cells. In cases of IRF secondary to malignant conditions it is usually necessary to obtain multiple biopsies, because neoplastic cells are frequently scattered into abundant fibrous tissue (2). The IgG4-RD more commonly shows obliterative phlebitis, mild-to-moderate eosinophil infiltrate and fibrosis with a storiform pattern and positive IHC for IgG4 (with a ratio IgG4<sup>+</sup>/IgG higher than 40%). It is usually necessary to perform several biopsies or to be guided by PET-CT in order to get an histopathological confirmation from a zone with high inflammatory activity (3,10). ECD is characterized by infiltration of typically lipid-laden histiocytes with admixed or surrounding fibrosis. On IHC staining, ECD histiocytes are positive for CD68, CD163, and Factor XIIIa, and negative for CD1a and Langerin (9).

Treatment should be started as soon as possible. In case of renal failure due to hydronephrosis, ureteral decompression (ureteral stents or nephrostomies) should rapidly be accomplished in order to avoid permanent renal damage (16). In cases of secondary RPF we need to treat the underlying condition. Medical treatment of IRF consists in early administration of prednisone (0.5-1 mg/kg/day during the first month). After clinical re-evaluation, if remission is achieved the initial dose should be progressively decreased. Most studies recommend to maintain steroid treatment for at least 9 months (2,3). If there is a contraindication to prednisone therapy, some studies suggest the use of tamoxifen (2,17). In case of refractory forms (patients who fail to achieve clinical or radiologic improvement within 4 to 6 months) mycophenolate mofetil or methotrexate associated with a low dose of prednisone have been proposed as good alternatives. Recent studies with rituximab, infliximab and tocilizumab have demonstrated good results although further studies are needed to draw definitive recommendations (2,18,19).

Regarding follow-up, patients should be monitored clinically, and imaging techniques and laboratory tests should be used. It includes inflammatory markers and renal function status. Ultrasonography is a useful and harmless technique which allows surveillance of obstructive uropathy. PET-CT enables the evaluation of disease activity and its extension.

IRF tends to have a good prognosis and evolution with treatment. Approximately 90% of cases have an

adequate response to treatment with a mortality rate lower than 10%. The relapse frequency is estimated to be around 10%, especially after the withdrawal of steroid treatment (4).

We performed a systematic review in PubMed using the terms "IgG4-related disease" and "case series" in English and 71 articles were found. We excluded case reports, review articles and case series that addressed only a specific organ involvement of IgG4-related disease. We also reviewed the references of those articles. We found ten articles of IgG4-RD case series and we finally included six of them in Table 1 (20-25). Unlike the principal IgG4-RD cohorts, in which the most frequently affected organs are liver, pancreas, lymph nodes and salivary glands, our case shows involvement of retroperitoneum, aorta and eye. Despite being considered a multisystemic illness, most of the described cases only had apparent infiltration in one organ. Our patient had lower IgG4 serum levels than those described in the international cohorts. However, they were similar to those of the Spanish population. As it happens on many occasions, our case did not show histopathologic features of IgG4-related disease, probably because only one biopsy was performed and this disease usually shows a patchy effect on tissues. The patient evolved with multiple organ failure and was deceased three weeks after the immunosuppressive treatment was initiated, despite that both IRF and IgG4-RD tend to have a good prognosis with low frequency of complications and favorable evolution with treatment (20-25).

In conclusion, we presented a case of a 59-year-old woman with idiopathic retroperitoneal fibrosis, periaortitis and orbital pseudotumor, without histopathologic or serologic features of IgG4-related disease. This could be related to the fact that the biopsy was done in a place with scarce inflammatory activity but high fibrosis. We want to emphasize the usual need to perform several biopsies or to be guided by PET-CT in order to achieve a histopathological confirmation. Although knowledge about IRF has significantly improved, it still remains an ambiguous condition. A lot of questions still need to be answered, especially about the pathogenesis. Further research on the relationship between IRF and IgG4-RD is required.

#### Acknowledgements

We would like to thank the Internal Medicine Department of the Hospital General Universitario Gregorio Marañón from Madrid for the support provided, especially to Dr. Jesús García-Castaño.

#### References

1. van Bommel EF, Jansen I, Hendriksz TR, Aarnoudse AL. Idiopathic retroperitoneal fibrosis: Prospective evaluation of incidence and clinicoradiologic presentation. *Medicine*



- (Baltimore). 2009; 88:193-201.
2. Urban ML, Palmisano A, Nicastro M, Corradi D, Buzio C, Vaglio A. Idiopathic and secondary forms of retroperitoneal fibrosis: A diagnostic approach. *Rev Med Interne*. 2015; 36:15-21.
  3. Rossi GM, Rocco R, Accorsi Buttini E, Marvisi C, Vaglio A. Idiopathic retroperitoneal fibrosis and its overlap with IgG4-related disease. *Intern Emerg Med*. 2017; 12:287-299.
  4. Vaglio A, Salvarani C, Buzio C. Retroperitoneal fibrosis. *Lancet*. 2006; 367:241-251.
  5. Ardila-Suarez O, Abril A, Gómez-Puerta JA. IgG4-related disease: A concise review of the current literature. *Reumatol Clin*. 2017; 13:160-166.
  6. Khosroshahi A, Carruthers MN, Stone JH, Shinagare S, Sainani N, Hasserjian RP, Deshpande V. Rethinking Ormond's disease "idiopathic" retroperitoneal fibrosis in the era of IgG4-related disease. *Medicine (Baltimore)*. 2013; 92:82-91.
  7. Hosaka N, Ito M, Taki Y, Iwai H, Toki J, Ikehara S. Amyloid A gastrointestinal amyloidosis associated with idiopathic retroperitoneal fibrosis. Report of a rare autopsy case and review of the literature. *Arch Pathol Lab Med*. 2003; 127:735-738.
  8. Janssen T, van Cangh PJ. Retroperitoneal fibrosis due to barium. *Prog Urol*. 1994; 4:429-432. (in French)
  9. Diamond EL, Dagna L, Hyman DM, *et al*. Consensus guidelines for the diagnosis and clinical management of Erdheim-Chester disease. *Blood*. 2014; 124:483-492.
  10. Goldoni M, Bonini S, Urban ML, Palmisano A, De Palma G, Galletti E, Coggiola M, Buzio C, Mutti A, Vaglio A. Asbestos and smoking as risk factors for idiopathic retroperitoneal fibrosis: A case-control study. *Ann Intern Med*. 2014; 161:181-188.
  11. Laroche AS, Bell RZ, Bezzaoucha S, Földes E, Lamarche C, Vallée M. Retroperitoneal fibrosis: Retrospective descriptive study on clinical features and management. *Res Rep Urol*. 2016; 8:175-179.
  12. Ceresini G, Urban ML, Corradi D, Lauretani F, Marina M, Usberti E, Palmisano A, Buzio C, Vaglio A. Association between idiopathic retroperitoneal fibrosis and autoimmune thyroiditis: A case-control study. *Autoimmun Rev*. 2015; 14:16-22.
  13. Feinstein RS, Gatewood OM, Goldman SM, Copeland B, Walsh PC, Siegelman SS. Computerized tomography in the diagnosis of retroperitoneal fibrosis. *J Urol*. 1981; 126:255-259.
  14. Bakir B, Yilmaz F, Turkay R, Ozel S, Bilgiç B, Velioglu A, Saka B, Salmaslioglu A. Role of diffusion-weighted MR imaging in the differentiation of benign retroperitoneal fibrosis from malignant neoplasm: Preliminary study. *Radiology*. 2014; 272:438-445.
  15. Moroni G, Castellani M, Balzani A, Dore R, Bonelli N, Longhi S, Martinelli I, Messa P, Gerundini P. The value of (18)F-FDG PET/CT in the assessment of active idiopathic retroperitoneal fibrosis. *Eur J Nucl Med Mol Imaging*. 2012; 39:1635-1642.
  16. Tiptaft RC, Costello AJ, Paris AM, Blandy JP. The long-term follow-up of idiopathic retroperitoneal fibrosis. *Br J Urol*. 1982; 54:620-624.
  17. Costanzi S, Zoli A, Ferraro PM, Danza FM, Ferraccioli GF. A paraneoplastic retroperitoneal fibrosis resistant to corticosteroids treated with tamoxifen. *Clin Nephrol*. 2008; 70:172-175.
  18. Maritati F, Corradi D, Versari A, Casali M, Urban ML, Buzio C, Vaglio A. Rituximab therapy for chronic periaortitis. *Ann Rheum Dis*. 2012; 71:1262-1264.
  19. Vaglio A, Catanoso MG, Spaggiari L, Magnani L, Pipitone N, Macchioni P, Pulsatelli L, Nicastro M, Becchi G, Corradi D, Versari A, Boiardi L, Salvarani C. Interleukin-6 as an inflammatory mediator and target of therapy in chronic periaortitis. *Arthritis Rheum*. 2013; 65:2469-2475.
  20. Li PH, Ko KL, Ho CT, Lau LL, Tsang RK, Cheung TT, Leung WK, Lau CS. Immunoglobulin G4-related disease in Hong Kong: Clinical features, treatment practices, and its association with multisystem disease. *Hong Kong Med J*. 2017; 23:446-453.
  21. Wallace ZS, Deshpande V, Mattoo H, Mahajan VS, Kulikova M, Pillai S, Stone JH. IgG4-related disease: Clinical and laboratory features in one hundred twenty-five patients. *Arthritis Rheumatol*. 2015; 67:2466-2475.
  22. Campochiaro C, Ramirez GA, Bozzolo EP, *et al*. IgG4-related disease in Italy: Clinical features and outcomes of a large cohort of patients. *Scand J Rheumatol* 2015; 45:135-145.
  23. Fernández-Codina A, Martínez-Valle F, Pinilla B, *et al*. IgG4-related disease: Results from a multicenter Spanish registry. *Medicine (Baltimore)*. 2015; 94:e1275.
  24. Inoue D, Yoshida K, Yoneda N, Ozaki K, Matsubara T, Nagai K, Okumura K, Toshima F, Toyama J, Minami T, Matsui O, Gabata T, Zen Y. IgG4-related disease: Dataset of 235 consecutive patients. *Medicine (Baltimore)*. 2015;94:e680.
  25. Lin W, Lu S, Chen H, *et al*. Clinical characteristics of immunoglobulin G4-related disease: A prospective study of 118 Chinese patients. *Rheumatology*. 2015; 54:1982-1990.
- (Received July 24, 2018; Revised February 11, 2019; Accepted February 20, 2019)

## Hydatid cyst of gall bladder masquerading as carcinoma: A rare case report with review of literature

Garima Jain<sup>1</sup>, Chandan Kumar<sup>1</sup>, Pankaj Meena<sup>2</sup>, Angel Rajan Singh<sup>3</sup>, Virendra Kumar<sup>4</sup>, Sunil Kumar<sup>5</sup>, Pranay Tanwar<sup>1,\*</sup>

<sup>1</sup>Laboratory Oncology Unit, Dr. B.R.A. Institute Rotary Cancer Hospital, All India Institute of Medical Sciences, New Delhi, India;

<sup>2</sup>Radiology Unit, Dr. B.R.A. Institute Rotary Cancer Hospital, All India Institute of Medical Sciences, New Delhi, India;

<sup>3</sup>Department of Hospital Administration, All India Institute of Medical Sciences, New Delhi, India;

<sup>4</sup>Department of NMR and MRI Facility, All India Institute of Medical Sciences, New Delhi, India;

<sup>5</sup>Department of Surgical Oncology, Dr. B.R.A. Institute Rotary Cancer Hospital, All India Institute of Medical Sciences, New Delhi, India.

### Summary

Hydatid disease is a parasitic infestation caused by *Echinococcus*, most commonly *Echinococcus granulosus*. Liver is the most common location followed by lungs. Hydatid involvement of gall bladder is a very rare entity, which masqueraded as gall bladder cancer. Here, we attempt to highlight the relevance of this rare disease and discuss this unique case of a 60-year-old male, who presented with gall bladder mass, abdominal pain, and vomiting. The patient was eventually diagnosed as Hydatid disease. The patient has been treated on medical management and has shown improvement. The manuscript has discussed diagnosis and management of disease along with review of literature.

**Keywords:** Hydatid cyst, gall bladder, *Echinococcus*, gall bladder carcinoma

### 1. Introduction

The 2015 WHO Foodborne Disease Burden Epidemiology Reference Group (FERG) statistics display a whopping 19,300 deaths and around 871,000 disability-adjusted life-years (DALYs) due to echinococcosis globally each year (1). Hydatid disease is a zoonotic disease caused by the larvae of genus *Echinococcus*, most commonly *Echinococcus granulosus* (95%) (2). It is one of the oldest parasitic diseases known to man and is most prevalent among sheep raising Mediterranean countries, Africa, South – America, Middle east, Australia and New Zealand. In India, southern states like, Andhra Pradesh, Saurashtra region of Gujrat, and Tamil Nadu reports highest prevalence of human hydatid disease (3). Humans are an accidental dead host, where liver (70-80%) is

the most common location followed by lungs (15-25%). Liver, being filtering organ for portal vessels, becomes, first probable site for lodging of parasitic ova (4). If parasites are not trapped in either liver or lung or may escape liver *via* lymphatic channels, they may get lodged in any part, like peritoneal cavity (8-18%), spleen (2-3%), kidney (1-4%), uterus and adnexa (0.5-1%), retroperitoneum (0.5-1%), pancreas (0.5-0.8%), brain (2%), gall bladder (< 1%), and others (0.1-3%) (5).

Gall bladder hydatid disease (GBHD) is a very rare entity and can be either primary or secondary to liver hydatid disease. Extensive literature review revealed 32 PubMed indexed and published case reports of GBHD (2,5-16). Here, we describe a case of GBHD along with involved liver suspected as GB malignancy with liver secondaries.

### 2. Case Report

A 60-year male, laborer by profession and non-vegetarian by diet presented with the complaints of abdominal pain associated with anorexia and weight loss for 1 year to Surgical OPD of All India Institute of Medical Sciences, New Delhi in January 2018. General physical examination and abdominal examination

Released online in J-STAGE as advance publication February 5, 2019.

\*Address correspondence to:

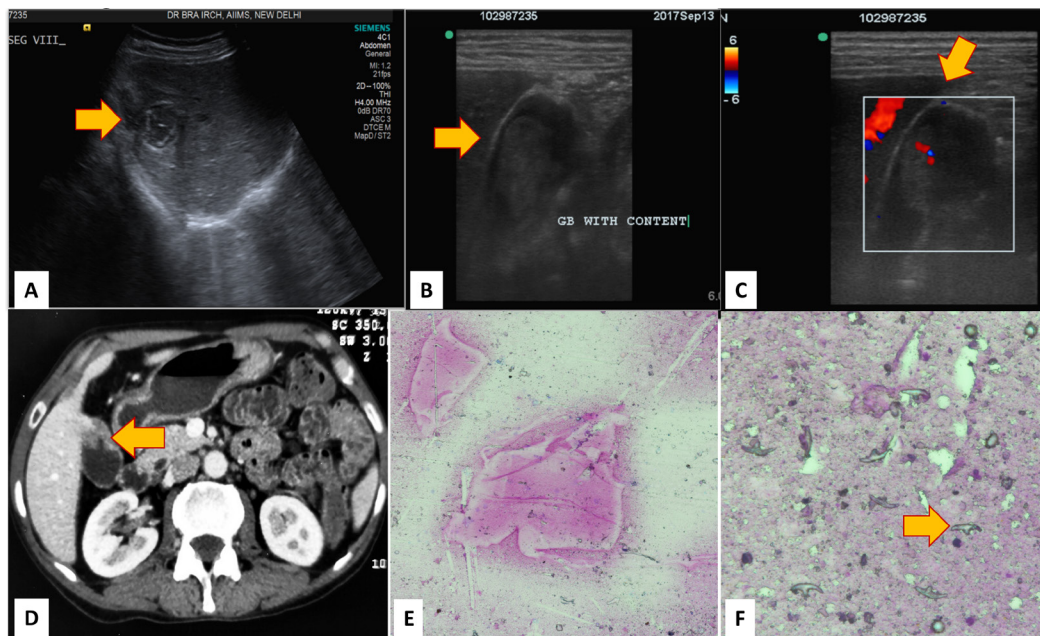
Dr. Pranay Tanwar, Laboratory Oncology Unit, Dr. B.R.A. Institute Rotary Cancer Hospital All India Institute of Medical Sciences New Delhi 110029, India.

E-mail: pranaytanwar@gmail.com

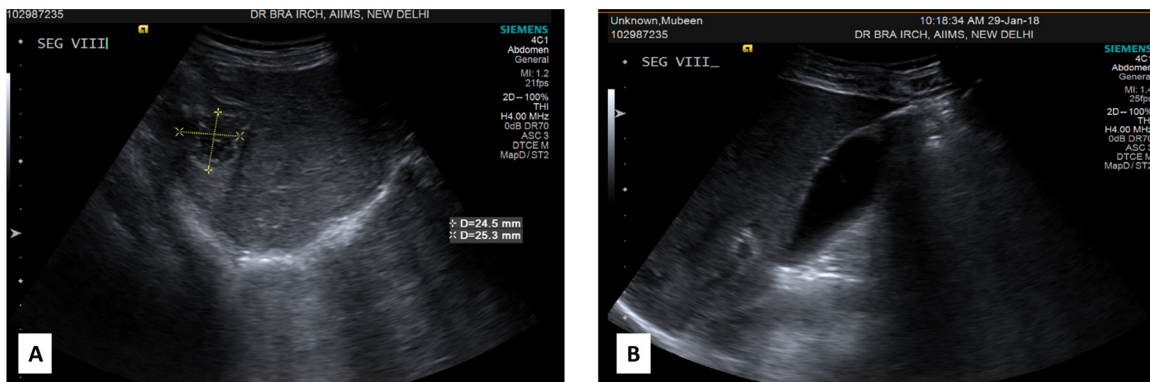
were within normal limits. Routine biochemical and hematological investigations were also within normal limits. Ultrasound (USG) abdomen (Figures 1A-1C) revealed a 4 × 3 cm mass in the gall bladder along with hypo-echoic lesion in segment IV A, segment I, segment VII & VIII of liver. Abdomen MRI (Figure 1D) further showed similar lesion in gall bladder. An impression of gall bladder carcinoma with metastasis to liver was proposed on imaging and guided Fine needle aspiration cytology (FNAC) was advised.

Guided aspirate smears from liver lesion showed very scant cellularity. It showed few fragments of lamellar tegument from cyst wall. There were scattered parasitic hooklets and calcareous corpuscles in a necro-inflammatory background. Features were consistent with *Echinococcus granulosus* (Hydatid cyst). In second setting, FNAC from gall bladder mass was done to rule out malignancy. GB mass fine needle aspiration

smears also yielded similar findings to that of liver aspirate (Figures 1E and 1F). Subsequently, hydatid serology was found to be positive. Patient was started on Albendazole tablet 400 mg BD for 4 weeks followed by a 2-week treatment free interval cycle in 3 cycles for 3 months. Patient was then advised for pericystectomy and cholecystectomy but, he denied any surgical intervention. Patient is on regular follow-up for the past year. Routine biochemical parameters were within normal limits and patient is symptomatically better with no nausea, vomiting or abdominal pain. After 3 months of treatment, USG abdomen and Hydatid serology levels were repeated. USG revealed a normally distended gall bladder without any mass lesion (Figure 2B), however a 2.5 × 2.4 cm hypo-echoic lesion with internal membranes and calcific foci was noted in segment VIII of liver (Figure 2A) suggesting residual disease.



**Figure 1.** (A) Hydatid cyst in segment VIII of liver, (B) GB mass with content mimicking malignancy, (C) with absolute nil vascular flow, (D) Liver hydatid with the typical water lily sign, (E) FNAC from GB showing laminated membranes, and (F) multiple hooklets with hydatid sand.



**Figure 2.** (A) A 2.5cm X 2.4cm hypoechoic lesion in liver segment VIII indicating residual disease, (B) GB without any mass lesion.

### 3. Discussion

Worldwide annual incidence of cystic echinococcosis has been estimated to be around 100,000-300,000 new cases. Increased prevalence of this disease is found in Mediterranean countries (between 1-8/100,000), Middle east, Africa (> 3%), Australia, South America and New Zealand. However, due to widespread international migration and global travel, the disease is increasing in incidence throughout the world (3). Hydatid disease is endemic in India and a major health concern, which adds to economic burden of the country. The annual incidence varies from 1-200/100,000 in different parts of the country. It has highest prevalence in Andhra Pradesh and Tamil Nadu (17).

The life cycle of *Echinococcus* species involves two hosts and a free-living egg stage. It is principally maintained in a dog-sheep-dog cycle, yet several other domestic animals may be involved. The adult *E. granulosus* resides in the small bowel of the definitive hosts *i.e.* dogs or other canines. A heavily infected dog alone can infect intermediate hosts like sheep over a wide area. The infection may be acquired by contact with infected dogs, egg-containing faces, egg-contaminated plants and soil usually happening by direct hand-to-mouth transfer. Eggs can also be ingested by consuming uncooked contaminated raw vegetables, salads, fruits and drinking water (3).

Sites: Once, egg reaches small intestine of man or intermediate host, oosphere gets released, which then, penetrates intestinal wall and enters into portal circulatory system ultimately reaching liver. Liver (65-75%) is the most common site of involvement followed by lungs (10-25%). All other sites of involvement are considered as unusual sites, which include peritoneal cavity (8-18%), spleen (2-3%), kidney (1-4%), uterus and adnexa (0.5-1%), retroperitoneum (0.5-1%), pancreas (0.5-08%), brain (2%), gall bladder (< 1%) and others. (0.1-3%) (5).

Most patients with atypical localizations produce symptoms at advanced stages. Radiological methods such as ultrasonography and computed tomography scan or magnetic resonance imaging may be confirmatory in most cases, while serological tests such as ELISA which have a sensitivity of > 90% serve as a useful ancillary diagnostic tool in cases with equivocal imaging (18).

GBHD is a very rare entity, even in areas where hydatid is endemic. It can primarily involve gall bladder only in rare occasions or secondary infestation may be seen by daughter cysts from pre-infected liver. The pathogenesis for GBHD is not very well understood and few hypotheses have been proposed. The most widely accepted route of infestation is through bile duct usually with co-existing primary liver involvement. Others routes include, spread of cyst through lymphatic channels after absorption of contaminated food into bowel, and gall bladder seeding done during any prior surgical

intervention of hepatic hydatid cyst (2).

Hydatid cyst has three layers *i.e.* outermost layer – pericyst – consists of modified fibrous and protective zone produced as host immune response. Middle layer is laminated, acellular membrane responsible for diffusion of nutrients and innermost is germinal layer, which contains scolices, which are larval stages of parasite. Together, middle and innermost layer are called an endocyst being the true layers of cyst, and outermost layer is referred to as pericyst. Infectious embryogenic tapeworms, develop from an out pouching of the germinal layer (19).

Pathological examination *via* FNAC or biopsy usually demonstrates different layers of cysts along with broad capsules and protoscolices. Occasionally, only hydatid sand along with hooklets may be found which are PAS and AFB positive.

Radiologically, Hydatid cyst is classified into 4 types. Type I includes active and initial stage of hydatid cyst, Type II also includes active phase of the parasite which can spread to adjoining areas by an out-pouching of a new cyst from main cyst cavity. Type III includes dead/inactive cyst and Type IV complicated cysts (20). USG also categorize cysts as solitary univesicular, solitary multivesicular, solid echogenic mass, multiple, either uni or multi-vesicular, or collapsed, flattened, and calcified. Additionally, USG can also identify active stage of disease where routine X-Ray may come out as normal. CT gives a clearer picture with respect to number of cysts, size, site, architecture and their relationship to adjoining areas. Many studies have demonstrated higher sensitivity of CT compared to USG for diagnosis (21). However, MRI is the diagnostic modality of choice for atypical Hydatid like muscular or subcutaneous because of its better assessment of soft tissue structure and its relationship (22).

Serological tests supplement radiological data in diagnosis of hydatid cyst. The gold standard serology test for echinococcosis detects IgG antibodies to hydatid cyst fluid-derived native or recombinant antigen B subunits. This is performed using ELISA or immunoblot formats and have high sensitivity (> 95%) but lower specificity (22).

The differential diagnosis of a cystic mass anywhere in the body includes a spectrum of congenital, traumatic, infective, benign and malignant etiologies. A liver or gall bladder cyst could be a simple (bile duct) cyst, Carolis disease, polycystic liver disease, benign adenoma, focal nodular hyperplasia, metastatic lesion, biliary cystadenoma or cystadenocarcinoma, primary hepatoma, pyogenic or amoebic abscess, and echinococcal cyst.

Complications like rupture can occur and can be contained (internal), communicating, and direct. The pericyst remains intact in internal rupture and may occur due to degeneration, trauma or response to therapy. Direct rupture occurs when both endocyst and pericyst rupture and can cause widespread dissemination into the

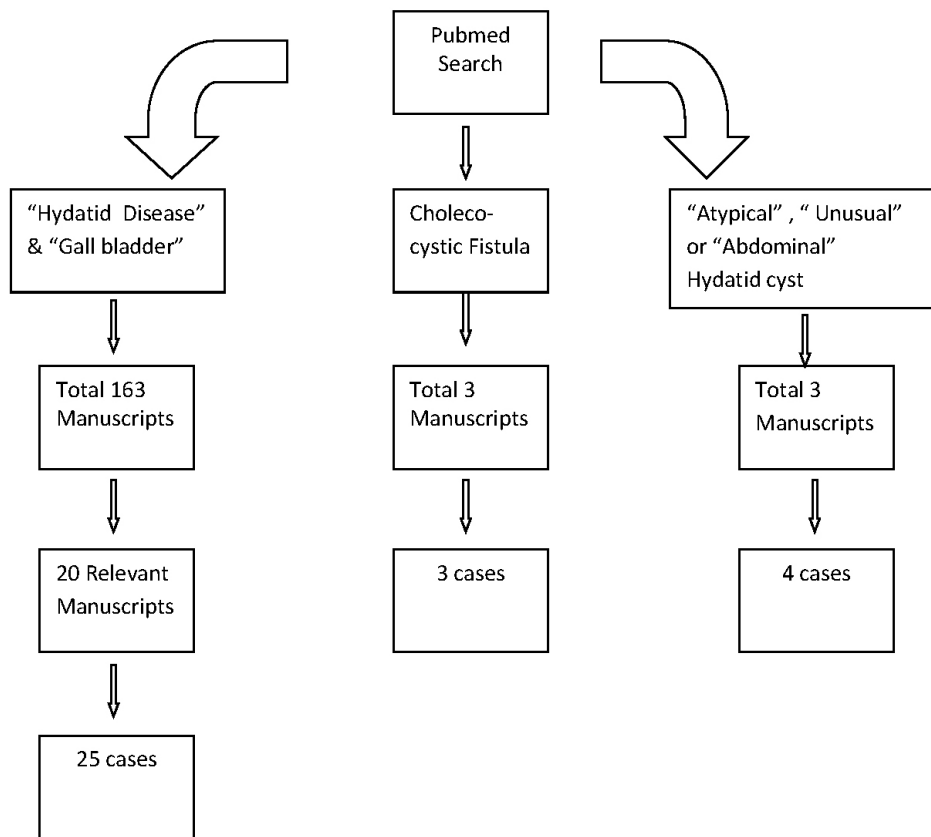


Figure 3. Flowchart depicting search of literature for "hydatid cyst of gall bladder".

peritoneal cavity. Iatrogenic rupture can also occur *via* surgical or percutaneous treatment and sudden death; anaphylactic shock or dissemination of disease can occur if cystic content spills into the peritoneal cavity.

Management of liver hydatid cysts includes medical therapy, percutaneous drainage or surgery. Various studies (21) demonstrated that Albendazole therapy and surgery combined have cure rates of > 90% and lower recurrence rates.

Mechanism of action of Albendazole is that it binds to colchicine-sensitive site of  $\beta$ -tubulin and inhibits their polymerization into microtubules in the intestinal cells of the parasites subsequently decreasing their absorptive function, especially the uptake of glucose by the adult and larval forms of the parasites, and also depleting glycogen storage. Depleted glucose levels result in insufficient energy for ATP production leading to the eventual death of the parasite. Albendazole sulfoxide (the active metabolite of Albendazole) is 70% bound to plasma protein and is widely distributed throughout the body; with active levels detected in urine, bile, liver, cyst wall, cyst fluid, and cerebrospinal fluid (CSF). Biliary concentrations of Albendazole sulfoxide have been found to be similar to those achieved in plasma because biliary elimination forms a significant proportion of elimination of Albendazole from the circulatory system (23).

The cure rate of medical management is around 60% and its indications are where there are contraindications

such as complex or widespread injury, advanced patient age, pregnancy, co-morbidities, multiple cysts which are difficult to access, partially inactive or calcified liver cysts, or patient refusal of surgery.

Surgical options include conservative surgeries like partial cyst resection, removal of cyst content followed by sterilization of residual cavity and PAIR (percutaneous aspiration and reinstallation of normal saline). Though conservative surgery is safer and less complex, however, they are associated with higher recurrence and morbidity rates. Complicated cysts, which are very close to biliary channels are best treated with conservative procedures to avoid risk of biliary leaks. Radical surgery includes pericystectomy and involved liver resection and comes with risks of compromising liver function. There is high risk of spillage of cyst contents leading to anaphylaxis with/without peritoneal seeding.

Extensive literature review was done on PubMed for listing previously reported cases of hydatid cyst of gall bladder. Mesh terms such as gall bladder, hydatid cyst, choleco-cystic fistula, atypical hydatid, unusual hydatid were used and a total of 169 manuscripts were screened. Subsequently, articles were enlisted, which pertained to GBHD as selection algorithm mentioned in flowchart (Figure 3). A total of 32GBHD cases, which included both primary (only GB) and secondary (involving GB and Liver) were analyzed (2,5-16). The discussed case will be the 33rd case in continuation with already

Table 1. Case reports with clinical data

Authors (Ref.)	No. of Cases	Year	Primary /Secondary	Age /Sex	Clinical Data	Abdominal Examination	Biochemical Results	Radiology	GB stones /Cholecystitis	Serology	Management		Recurrence
											Surgical	Medical	
BarónUrbaNo <i>et al.</i> (2)	1	1978	Secondary	76	1	4	Normal	NA	NA	NA	Cholecystectomy + Total cyst resection	None	NA
Rigas <i>et al.</i> (2)	1	1979	Primary	65/F	1,2	None	NA	CT	No	Not done	Cholecystectomy	None	No
Cangiotti <i>et al.</i> (2)	1	1994	Secondary	M	NA	NA	NA	NA	NA	NA	Cholecystectomy	None	NA
Kappor <i>et al.</i> (2)	1	2000	Primary	53/M	1,3,4	1,3	Deranged LFT	USG	No	Positive	ERCP + Stent	None	No
Raza <i>et al.</i> (2)	1	2003	Secondary	27/M	1,4	4	NA	USG	YES	Not done	Cholecystectomy + Rt. Lobe enucleation	None	NA
Kumar <i>et al.</i> (2)	1	2004	Secondary	27/F	1,6	None	NA	CT	No	Not done	Partial pericystectomy + Cholecystectomy; percutaneous aspiration, instillation and re-aspiration hypertonic saline	post operative albendazole x 4 months	No
Safioleas <i>et al.</i> (2)	1	2004	Primary	65/F	1,2	None	Normal	X- Rays, Barium Meal &Cholangiography	YES	Not done	Cholecystectomy + total cyst resection	None	No
Safioleas <i>et al.</i> (2)	2	2004	Primary	51/F	1	None	Eosinophilia & Normal LFT	X- Rays, Barium Meal, USG	YES	Not done	Cholecystectomy + total cyst resection	None	No
Safioleas <i>et al.</i> (2)	3	2004	Primary	63/M	1,5	None	Normal	X- Rays, CT	YES	Positive	Cholecystectomy + total cyst resection	None	No
Pitiakoudis <i>et al.</i> (2)	1	2005	Primary	60/M	1,2,3,4	3	Deranged LFT	USG , Spiral CT, MRI	YES	Not done	Cholecystectomy	post operative albendazole x 4 months	No
Wani <i>et al.</i> (2)	1	2006	Primary	51/F	1	None	NA	USG,CT	YES	Not done	Cholecystectomy	None	No
Sabat <i>et al.</i> (2)	1	2008	Secondary	35/F	1,3,4	2	Deranged LFT	USG,CT	No	Not done	Cholecystectomy + percutaneous aspiration, instillation and re-aspiration using hypertonic saline (segment VII)	post operative albendazole x 9 months	No
Murtaza <i>et al.</i> (2)	1	2008	Secondary	32/F	1,5	4	Normal	USG	None	Not done	sub-total Cholecystectomy	preoperative albendazole	NA
Krasniqui <i>et al.</i> (2)	1	2010	Primary	39/F	1,2	2	Normal	USG, CT , X- Ray Abdomen and Chest	None	Not done	Pericystectomy & Cholecystectomy	post operative albendazole ( 3 cycles 21 days each with gap of 1 week)	No
Rabbani <i>et al.</i> (16)	1	2011	Secondary	38/M	1,2,3,4	4	Eosinophilia & Normal LFT	USG & Chest X-Ray	No	Not done	Pericystectomy & Cholecystectomy	post operative albendazole ( 3 cycles 21 days each with gap of 1 week)	No
Mushtaque <i>et al.</i> (7)	1	2012	Secondary	NA	1,5	1	NA	USG & CECT	NA	Positive	Cholecystectomy	post operative albendazole ( 2 cycles 21 days each with gap of 14 days)	No
Ertem <i>et al.</i> (2)	1	2012	Primary	42/M	1,2,3,4	1	Deranged LFT	USG, CT, MRCP, ERCP	No	Positive	Cholecystectomy	None	NA
Noomene <i>et al.</i> (2)	1	2013	Primary	32/F	1,2	2	Normal	USG, CT, MRI	No	NEGATIVE	Cholecystectomy	None	No
Yücesoy <i>et al.</i> (2)	1	2014	Secondary	58/M	1,2,3,4	1	Deranged LFT	USG & MRCP	No	Not done	Cholechohomy & Cholechoduodenostomy	post operative albendazole x 2 weeks	No
Index Case	1	2018	Secondary	60/M	1,2,3	None	Normal	USG & CT	No	Positive	Pericystectomy & Cholecystectomy	post operative albendazole	No

Clinical data: - abdominal pain 1, nausea & vomiting 2, fever -3, jaundice -4, dyspepsia- 5, past history of hydatid- 6. Examination: -hypochondrium lump-1, abdominal tenderness -2, ascites-3, hepatomegaly -4

**Table 2. Case reports without clinical data**

Authors (Ref.)	No. Of cases	Year	Primary/Secondary	Language
Seror <i>et al.</i> (15)	1	1958	Secondary	French
Khokhlov <i>et al.</i> (14)	1	1962	Primary	Russian
Ansimov <i>et al.</i> (13)	1	1962	Primary	Russian
Tkebuchava <i>et al.</i> (11)	1	1966	Primary	Other
Khokhlov <i>et al.</i> (12)	1	1967	Primary	Russian
Gillet <i>et al.</i> (10)	3	1973	Secondary	French
Mizaushv <i>et al.</i> (9)	1	1979	Primary	Russian
Ivanis <i>et al.</i> (8)	1	1994	Secondary	German
Aksu <i>et al.</i> (6)	3	2013	Primary	Other

reported cases.

Out of all reported cases (Tables 1 and 2), 18 cases (56.3%) were primary and the other 14 were secondary. Detailed clinical data was available in 19 cases (Table 1) whereas it could not be extracted in the other 13 cases (Table 2) as they were published in indigenous languages with only the abstract available in English. We hereby, analyzed clinical, management and outcome profile for 19 cases along with the indexed case.

Among these, abdominal pain was most common presenting symptoms seen in 19/19 (100%) cases. Nausea/vomiting 8/19 (42.2%) and jaundice 8/19 (42.2%) were ranked as the second most common symptom. The index case also presented with nausea, vomiting and abdominal pain. Out of all the cases studied only a single case (5.3%) had prior history of hydatidosis. This patient had lung hydatidosis 2 years back and later presented with GB hydatidosis. However, the index case did not have previous such history. Abdominal examination was normal in 6/19 (31.6%) whereas 4/19 (21.1%) patients had mild hepatomegaly. Abdominal tenderness and ascites was seen in 3/19 (15.8%). Six cases 6/19 (31.6%) had associated gallstones. Liver function was deranged in 5/19 (26.3%) while it was normal in 7/19 (36.8%) cases similar to the index case.

Alone or in combination, USG, CT, and MRI were used to confirm diagnosis of GBHD with variable frequency in different cases. MRCP and ERCP were also used as a part of workup in 2/19 (10.5%) cases. Hydatid serology was used as a part of workup in 6 cases with a high positive rate in 5/6 (83.3%) cases. Index case also demonstrated positive serology results.

As a part of medical treatment 7/19 (36.8%) received post-operative Albendazole. Only a single case (5.3%) received pre-operative Albendazole. Our case has received only medical treatment and has dissented from surgical intervention. 11/19 cases (57.9%) cases did receive various anti helminthic therapies as a part of treatment. Cases were followed up for a minimum period of 5 years and none of the cases reported recurrence on follow-up. GBHD either primary or secondary has never been reported to be associated with hepatobiliary malignancy.

The current case was an adult male presenting with a

long standing history of abdomen pain. Gall bladder lump along with lesions in liver were discovered on imaging. The history of anorexia and weight loss coupled with the imaging findings put the differential of gall bladder carcinoma as the most probable diagnosis. GBHD as has been discussed is a rare entity and is not among the top differentials thought of in a GB lump. This case teaches us the importance of keeping infective etiologies such as hydatid cyst in mind while investigating a lump as Hydatid cyst, which has been reported from rare sites such as peritoneal cavity, spleen, kidney, uterus, adnexa, pancreas, brain, etc.

#### 4. Conclusion

Despite the available advances medical and surgical management, the prevalence is still high for hydatid disease especially in endemic regions. This is a completely treatable and preventable disease. It calls for promotion of healthcare and hygiene awareness among rural masses along with health care providers about disease. Good hygiene and ideal quality assurance of slaughter houses, equipping healthcare professionals and health centers for timely diagnosis and treatment is mandatory for eradication of this disease.

#### References

1. World Health Organization. (2018). Echinococcosis. <http://www.who.int/news-room/fact-sheets/detail/echinococcosis> (Accessed August 24, 2018)
2. Gómez R, Allaoua Y, Colmenares R, Gil S, Roquero P, Ramia JM. Hydatid cyst of the gallbladder: A systematic review of the literature. *World J Hepatol.* 2016; 8:1087-1092.
3. Rao SS, Mehra B, Narang R. The spectrum of hydatid disease in rural central India: An 11-year experience. *Ann Trop Med Public Health.* 2012; 5:225-230.
4. Krasniqi A, Limani D, Gashi-Luci L, Spahija G, Dreshaj IA. Primary hydatid cyst of the gallbladder: A case report. *J Med Case Rep.* 2010; 4:29.
5. Mushtaque M, Mir MF, Malik AA, Arif SH, Khanday SA, Dar RA. Atypical localizations of hydatid disease: Experience from a single institute. *Niger J Surg.* 2012; 18:2-7.
6. Aksu M, Sevimli FK, Ibioloğlu I, Arpacı RB. Cystic

- echinococcosis in the Mersin province (119 cases). *Turkiye Parazitolojisi Dergisi*. 2013; 37:252-256. (in Turkish)
7. Yücesoy AN, Poçan S. Secondary gallbladder hydatidosis and nonfragmented germinative membrane sourced obstructive jaundice caused by intrabiliary ruptured hepatic hydatid cyst (a case report): Two rare complications of the intrabiliary ruptured hepatic hydatid cyst. *Hepatobiliary Surg Nutr*. 2014; 3:209-211.
  8. Ivanis N, Rubinić M, Gudović A, Zeidler F. Ultrasound image of an echinococcus daughter cyst in the gallbladder. *Ultraschall Med*. 1994; 15:269-271. (in German)
  9. Mizaushvili BA, EmuzovSKh. Rare case of acute phlegmonous cholecystitis in combination with echinococcosis of the gallbladder and mechanical jaundice. *Vestn Khir Im I I Grek*. 1979; 122:93-94. (in Russian)
  10. Gillet M, Runser C, Monange C, Carayon P, Gisselbrecht H, Paquette JP, Leconte des Floris R. Migration of daughter cysts into the common bile duct and gallbladder hydatid cyst of the liver. Emergency surgery. Apropos of 3 cases. *Ann Chir*. 1973; 27:831-838. (in French)
  11. Tkebuchava GI. Calcified echinococcosis of the gallbladder. *Khirurgiia (Mosk)*. 1966; 42:134-135. (in Russian)
  12. Khokhlov NF. Echinococcosis of gallbladder and bile ducts. *Sov Zdravookhr Kirg*. 1967; 3:26-27. (in Russian)
  13. Ansimov AF. On echinococcosis of the gallbladder and bile ducts. *Khirurgiia (Mosk)*. 1962; 38:106-107. (in Russian)
  14. Khokhlov NF. A case of echinococcosis of the gallbladder. *Zdravookhranenie Kazakhstana*. 1962; 22:72-73. (in Russian)
  15. Seror J, Rives J, Azoulay C. Common bile duct obstruction caused by hydatid gallbladder revealed by systematic examination of the bile ducts: Importance of radiomanometry in hydatid cysts of the liver with biliary content; excellent results of an ideal choledochotomy. *Afr Fr Chir*. 1958; 16:367-370. (in Russian)
  16. Rabbani K, Narjis Y, Louzi A, Benelkhaat R, Jalal H, Finech B. Unusual localization of hydatidosis: Hydatid cyst of gallbladder. *Annals of Tropical Medicine and Public Health*. 2011; 4:119-121.
  17. Mathur PN, Parihar S, Joshi CP, Kumawat JL. Hydatid disease-still endemic in the southern region of state of rajasthan, India: A clinical study carried out in tertiary care hospital. *Int Surg J*. 2016; 3:1802-1805.
  18. Zaman K, Mewara A, Kumar S, Goyal K, Khurana S, Tripathi P, Sehgal R. Seroprevalence of human cystic echinococcosis from North India (2004–2015). *Trop Parasitol*. 2017; 7:103-106.
  19. Pedrosa I, Saíz A, Arrazola J, Ferreirós J, Pedrosa CS. Hydatid disease: Radiologic and pathologic features and complications. *Radiographics*. 2000; 20:795-817.
  20. Polat P, Atamanalp SS. Hepatic Hydatid Disease: Radiographic Findings. *Eurasian J Med*. 2009; 41:49-55.
  21. Scherer K, Gupta N, Caine WP, Panda M. Differential diagnosis and management of a recurrent hepatic cyst: A case report and review of literature. *J Gen Intern Med*. 2009; 24:1161-1165.
  22. Gomez I, Gavara C, López-Andújar R, Belda Ibáñez T, Ramia Ángel JM, Moya Herraiz Á, Orbis Castellanos F, Pareja Ibars E, San Juan Rodríguez F. Review of the treatment of liver hydatid cysts. *World J Gastroenterol*. 2015; 21:124-131.
  23. Smego RA Jr, Sebanego P. Treatment options for hepatic cystic echinococcosis. *Int J Infect Dis*. 2005; 9:69-76.
- (Received September 10, 2018; Revised January 4, 2019; Accepted January 21, 2019)



# Guillain-Barré syndrome in a patient of acute Hepatitis E virus infection associated with genotype 1: Case report and literature review

Manish Chandra Choudhary<sup>1,2,§</sup>, Vijeta Bajpai<sup>1,§</sup>, Lovkesh Anand<sup>3</sup>, Ekta Gupta<sup>1,\*</sup>

<sup>1</sup> Department of Virology, Institute of Liver and Biliary Sciences, New Delhi, India;

<sup>2</sup> Molecular and Cellular Medicine department, Institute of Liver and Biliary Sciences, New Delhi, India;

<sup>3</sup> Department of Hepatology, Institute of Liver and Biliary Sciences, New Delhi, India.

## Summary

Hepatitis E is a serious public health problem in developing countries. Most of the patients with Hepatitis E virus (HEV) infection present with typical acute hepatitis symptoms. However, in few patients it may lead to complications such as liver failure and extrahepatic symptoms. One of the rare extrahepatic presentations of this infection is neurological complications such as Guillain-Barré syndrome (GBS) which is observed in 5.5% of HEV infected patients (mainly in developed countries). Moreover, only genotype (gt) 3 HEV was found in association with GBS among patients in developed countries whereas molecular characterisation of HEV cases detected from developing countries have not been reported till now. Here, we are reporting a case of GBS as an extrahepatic complication of HEV associated with gt1 identified by molecular characterization by performing PCR of open-reading frame 2 (ORF2) region of HEV. Phylogenetic analysis by maximum likelihood method revealed that HEV gt1 case reported in this paper rooted closely with other HEV gt1 samples from South-Asian countries with high bootstrap values indicative of fully resolved tree.

**Keywords:** Hepatitis E virus, Guillain-Barré syndrome, genotype, sofosbuvir

## 1. Introduction

Hepatitis E is an enterically transmitted viral hepatitis caused by Hepatitis E virus (HEV) infection. It is a non-enveloped, single stranded RNA virus and the most common cause of acute sporadic hepatitis in all age groups (1). According to World Health Organization (WHO), there are 20 million Hepatitis E infections annually with over 3 million cases of acute hepatitis E infections resulting in 56,600 hepatitis E-related deaths, with the highest prevalence in East and Southern Asia (2).

Acute HEV infection is usually a self-limiting disease which usually gets resolved within 1 to 2

months even without treatment. It may cause chronic infection when there is persistence of HEV RNA for more than 3 months after exposure (3). Chronic HEV infection rapidly progress to cirrhosis and Acute-on-Chronic Liver Failure (ACLF), especially in organ transplant recipients and other immunocompromised patients. Numerous extra-hepatic manifestations have been reported in association with acute or chronic HEV infection. However, little data is available regarding HEV-related neurological symptoms and it is observed that only 5.5% HEV infected patients presents with neurological disease like GBS, bell's palsy, neuralgic amyotrophy, acute transverse myelitis and acute meningoencephalitis mainly in developed countries (4). The spectrum of neurological injury is mainly divided into two clinical presentations: dominant clinical presentation in form of GBS and neuralgic amyotrophy; and less frequent presentation in the form of meningitis, encephalitis, transverse myelitis (4-7). Early diagnosis and specific treatment of HEV infected patient with such neurological manifestations is necessary to avoid

Released online in J-STAGE as advance publication January 31, 2019.

<sup>§</sup>These authors contributed equally to this work.

\*Address correspondence to:

Dr. Ekta Gupta, Department of Virology, Institute of Liver and Biliary Sciences, New Delhi 110070, India.

E-mail: ektagaurisha@gmail.com

increased risk of serious long-term complications and mortality of patients. To the best of our knowledge, there have been only four reported cases of GBS as an extrahepatic symptom of HEV in India with no description of its molecular analysis (5-8).

## 2. Case Report

We report a case of 30-year-old male, presented with high grade intermittent fever (102°F) for 15 days. Fever was followed by jaundice, which was insidious in onset, gradually progressive, not associated with pruritus and clay coloured stools. There was no history of petechiae, ecchymosis, abdominal distention, altered sensorium, decrease in urine output and hematemesis or melena. After one week of jaundice, patient developed shortness of breath which was not associated with chest pain, orthopnoea, and paroxysmal nocturnal dyspnoea. Patient's breathlessness was also accompanied by bilateral lower limb weakness. The patient was transferred to Out-patient Department (OPD) of Institute of Liver and Biliary Sciences for further check-up. There was no history of indigenous medications or any other intoxication. There was no history of major surgeries, blood transfusions, or intravenous drug abuse prior to onset of disease, and other comorbid situations like diabetes mellitus, hypertension, coronary artery disease, tuberculosis, and thyroid disorders.

On clinical examination, patient was febrile, conscious and well oriented to time, place, person. Blood pressure was normal (125/65 mmHg), pulse rate was increased (130/minute), respiratory rate was normal (20/minute). Pallor was absent; icterus and pedal edema were present. Neurological examination revealed that there was generalized areflexia and decreased power (3/5) in bilateral lower limbs. In view of these clinical findings, a diagnosis of lower motor neuron type paraparesis was made. Laboratory investigations revealed normal blood counts and serum electrolytes levels. Liver function tests showed conjugated hyperbilirubinemia with increased serum aminotransferases (Table 1). In order to detect acute viral hepatitis infection, serological analysis was performed for all viral hepatitis markers (Hepatitis A virus (HAV) IgM antibody, Hepatitis B surface antigen (HBsAg), anti-HCV antibody (anti-HCV) and HEV IgM antibody). All serological markers were negative except HEV IgM antibody. This was suggestive of acute HEV infection. Further, HEV RNA was detected in the serum sample using *in-house* designed primers with Roche probe master mix (Roche Diagnostics, MA, USA) on Light Cycler 480 (LC480) instrument. HEV viral load was detected to be  $3.4 \times 10^3$  IU/ml. For phylogenetic analysis, HEV ORF2 was amplified from serum sample (High pure viral RNA kit, Roche Diagnostics, MA, USA) and 10% stool sample in 0.5% NaCl solution (FastRNA Pro™ Soil-Direct Kit, MP

**Table 1. Baseline biochemical parameters of patient at the time of admission**

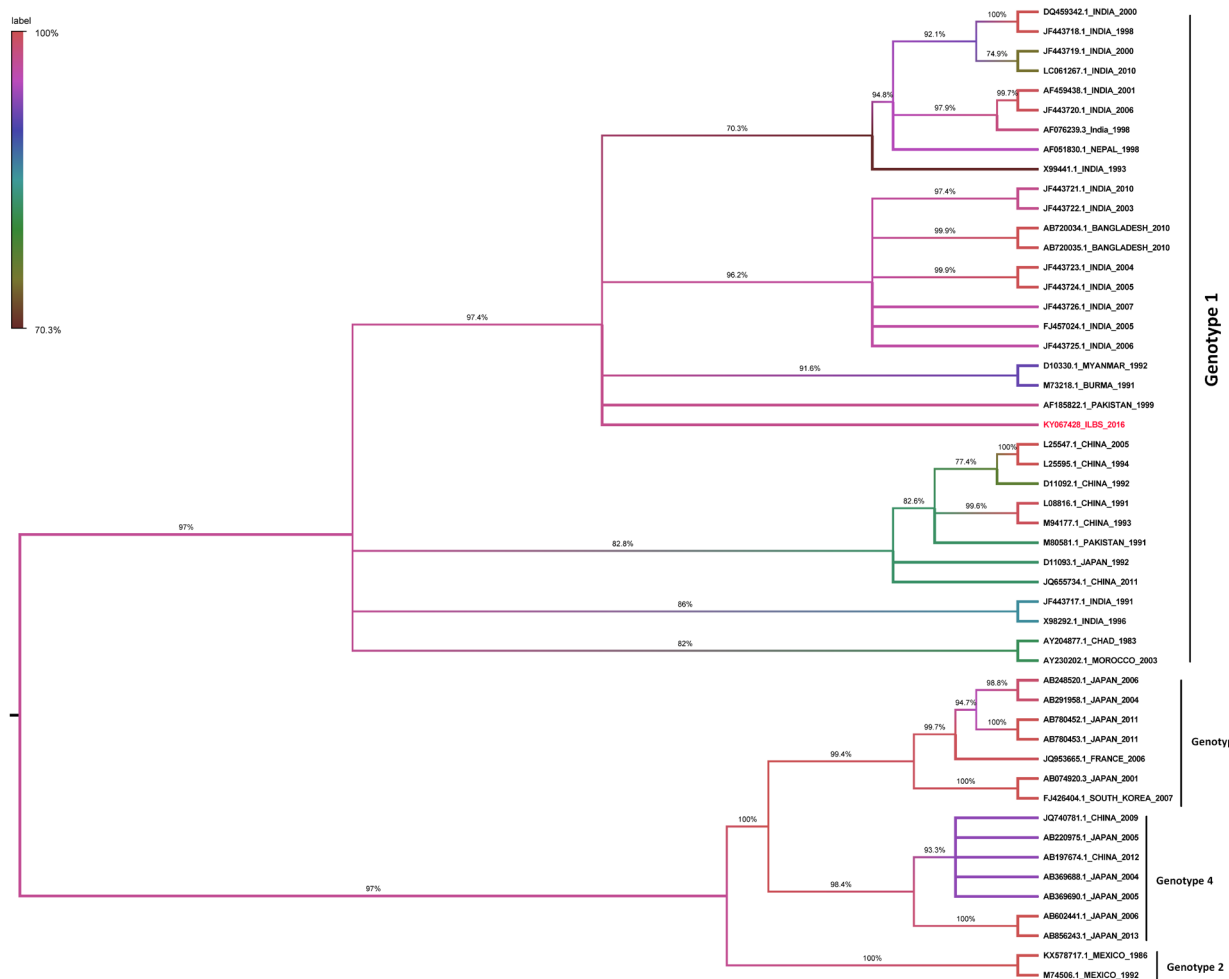
Biochemical Parameters (Normal Range)	Values
HB (13 - 17 g/dL)	13.4
PCV (36 - 48 g/dL)	42.1
TLC (4,000 - 11,000/mm <sup>3</sup> )	$15.2 \times 10^9$
PLT ( $150 \times 10^3$ - $400 \times 10^3$ )/mm <sup>3</sup>	177
AST (5 - 40 IU/mL)	864
ALT (10 - 40 IU/mL)	648
Serum Bilirubin direct (0 - 0.2) mg/dL	16.8
Serum Indirect Bilirubin (0.2 - 0.8) mg/dL	10.1
Serum total Bilirubin (0.3 - 1.2) mg/dL	6.7

HB, haemoglobin; PCV, packed cell volume; TLC, total leucocyte count; PLT, platelet; AST, aspartate serum transaminases; ALT, alanine aminotransferases.

Biomedicals, LLC, CA, USA) using ORF2 specific Polymerase Chain Reaction (PCR), generating an amplicon length of 846 bp (HEV\_ILBS\_GBS). HEV\_ILBS\_GBS PCR product was gel purified and Sanger-sequenced followed by genotype search using NCBI genotyping tool program which showed similarity with gt1. The sequence was submitted in Genbank and an accession number was provided, viz, KY067428. Further, phylogenetic tree reconstruction was done using MEGA software v7.0 using KY067428 in conjunction with global HEV sequences using GTR + G model (9). KY067428 aligned with other HEV gt1 sequence from India, Burma, and Pakistan with high bootstrap values indicative of highly resolved tree as shown in Figure 1.

On the basis of clinical features and laboratory investigations, diagnosis of acute viral hepatitis E with gt1 was made and patient was managed conservatively and given anti-viral medications; Sofosbuvir 400 mg orally once-a-day for one month, and Ribavirin 200 mg orally twice-a-day for one month. In view of lower limb weakness, nerve conduction studies were performed. They showed alteration in nerve conduction velocity with pure motor axonal neuropathy affecting lower limbs. Cerebrospinal fluid (CSF) analysis showed elevated proteins with normal cell count (CSF proteins, 243 mg/dL (normal range: 15-45 mg/dL); total leukocyte count, < 5 cells/mL), suggestive of albuminocytologic dissociation. Magnetic resonance imaging of brain and spinal cord were normal.

With these neurological findings, the diagnosis of GBS, as sequelae of acute HEV infection was made. Supportive measures, such as administration of intravenous fluids and nutritional therapy, were used for management of GBS. Patient recovered symptomatically after antiviral and supportive therapy. The patient was discharged after 1 week, with significant improvement in clinical symptoms (jaundice, fever) and neurological power. Follow-up of patient was done on out-patient basis. There was complete recovery of neurological power 4 weeks post-treatment. Patient's blood samples were also tested for HEV IgM antibody and HEV RNA.



**Figure 1. Molecular Phylogenetic analysis of HEV strains by Maximum Likelihood method.** The evolutionary history was inferred by using the Maximum Likelihood method based on the General Time Reversible model. Numbers at the nodes indicates bootstrap values in percentage generated by 1,000 replicates. Only bootstrap values greater than 0.70 were considered for constructing tree. Strain sequenced in the study has been highlighted with red. Evolutionary analyses were conducted in MEGA7. The analysis involved 50 nucleotide sequences

Both tests were found to be negative.

### 3. Discussion

GBS is an acute immune-mediated polyradiculoneuropathy that results in rapidly progressing symmetric motor paralysis, limb palsy, hypoflexia and areflexia. It is usually preceded by an infection, which evokes an immune response those cross-reacts with peripheral nerve components *via* molecular mimicry. The presentation of this disorder has several forms, including acute inflammatory demyelinating polyneuropathy (AIDP), acute motor axonal neuropathy (AMAN), acute motor-sensory axonal neuropathy (AMSAN), and Miller Fisher syndrome (MFS) (10).

A brief literature review was done using Pubmed database to identify other published cases and describe the clinical characteristics of HEV-associated GBS. With the addition of our patient, 54 cases were included, and the clinical characteristics of these cases are summarized in Table 2. Mean age of the reported

patients was 51 years (20-73 years). Most of our reviewed cases were found in Western Europe and Southern and Eastern parts of Asia. These patients developed HEV-associated GBS within an acute onset and experienced hepatitis like symptoms, including nausea, malaise, vomiting and jaundice. This was followed by GBS symptoms which includes motor weakness, sensory disorder, and cranial nerve palsy. In most of the previously published reports, the association between HEV infection and GBS has been based on laboratory detection of HEV IgM antibody in serum and only few case reports have detected HEV RNA along with HEV IgM in serum for confirmation of diagnosis (6,7). Genotyping was performed in only 11 patients and revealed gt3 in ten patients while only one patient from Bangladesh revealed gt1, suggestive of higher HEV gt3 tropism for GBS (11,12). As far as treatment is concerned, treatment details for 31 cases were available, out of which 4 used plasmapheresis, 25 used Intravenous immunoglobulin, whereas 1 patient used Ribavirin. All patients had good clinical outcome

**Table 2. List of HEV-associated GBS cases with its clinical characteristics**

Year	No of cases	Age /sex	HEV IgM	HEV RNA	Nerve-conduction	Treatment	Ref.
2018	1	30Y/M	+	Serum+	study	Supportive/ Sofosbuvir+ Ribavirin	Present case
2017	8	Mean: 50Y/ 6M, 2F	+	Serum+ (n = 2) Others NT	AMAN AIDP (n = 3) AMSAN (n = 1) Equivocal (n = 1) Demyelinating (n = 2) Sensory neuropathy (n = 1)	IVIG (n = 5) PP (n = 1) Supportive (n = 2)	(11,12,15)
2016	4	Mean: 53Y/M	+	Serum+ (n = 1) Others NT	AIDP (n = ) MSF (n = ) NM (n = 2)	IVIG	(13,14)
2015	4	Mean: 50Y/2M, 2F	+	Serum+ (n = 2) Others NT	AIDP (n = 3) AMSAN (n = 1)	IVIG	(8,16,17)
2014	14	Mean: 60Y/10M,4F	+	Serum+ (n = 3) CSF- (n = 10)	AIDP (n = 9) AMSAN (3) (Equivocal n = 2)	MV/IVIG	(18-22)
2013	13	Mean: 45Y/2M, 1F Others NM	+	Serum+	AIDP (n = 2) NM	IVIG	(23-25)
2012	3	Mean: 60Y/1M, 2F	+	Serum+ (n = 2), 1 NT	AIDP	IVIG MV/IVIG/Ribavirin	(26-28)
2011	2	66Y/M, 40Y/F	+	NT	AIDP	IVIG MV/IVIG/PP	(5,29)
2009	1	60Y/M	+	NT	AIDP	IVIG	(30)
2008	1	20Y/M	+	NT	AIDP + AMSAN	MV	(31)
2005	1	58Y/F	+	NT	NT	IVIG/PP	(6)
2002	1	35Y/M	+	NT	AIDP	MV/IVIG	(32)
2000	1	50Y/M	+	NT	AIDP	Supportive	(7)

F, female; M, male; HEV, hepatitis E virus; +, positive; -, negative; CSF, cerebrospinal fluid; AIDP, acute inflammatory demyelinating polyneuropathy; AMAN, acute motor axonal neuropathy; AMSAN, acute motor-sensory axonal neuropathy; MSF, miller fisher syndrome; NM, not mentioned; NT, not tested; MV, mechanical ventilation; IVIG, intravenous immunoglobulin; PP, plasmapheresis.

with varying duration of recovery period.

In the present case report, the patient was diagnosed with acute HEV infection which subsequently developed neurological complications in form of GBS. Detailed molecular analysis showed that the patient was infected with HEV gt1 which is quite common in developing countries including India. To the authors knowledge, this is the first case report of neurological complications (GBS) associated with acute HEV gt1 infection in an Indian patient. Among GBS-HEV cases reported so far, most of them were treated with intravenous immunoglobulin (IVIG) or ribavirin (13,14). This treatment may prolong clinical and neurological recovery in patient up to 18 months. In the present case, antiviral namely sofosbuvir and ribavirin were used in combination which improved clinical and neurological recovery of patient in one week and helped in clearance of viremia in a month's time.

Neurologic disorders as GBS are an emerging extrahepatic manifestation of HEV infection in gt1. This suggests that neurotropic variant HEV may lead to fatal clinical outcome and must be treated with specific antiviral to avoid morbidity and mortality of acute HEV infected patients. Additional case-control prospective studies should confirm this association, which would attribute GBS to HEV infection associated disease burden.

## Acknowledgements

This research did not receive any specific grant from funding agencies in the public, commercial, or not-for-profit sectors. Further, authors wish to acknowledge Mr. Keshav Singh for handling and storage of patient's plasma and stool samples.

## References

1. Mushahwar IK. Hepatitis E virus: Molecular virology, clinical features, diagnosis, transmission, epidemiology, and prevention. *J Med Virol.* 2008; 80:646-658.
2. Hepatitis E fact sheet (revised August 2004). *Wkly Epidemiol Rec.* 2004; 79:314-316.
3. Krain LJ, Nelson KE, Labrique AB. Host immune status and response to hepatitis E virus infection. *Clin Microbiol Rev.* 2014; 27:139-165.
4. Bazerbachi F, Haffar S, Garg SK, Lake JR. Extra-hepatic manifestations associated with hepatitis E virus infection: A comprehensive review of the literature. *Gastroenterol Rep (Oxf).* 2016; 4:1-15.
5. Kamar N, Bendall RP, Peron JM, Cintas P, Prudhomme L, Mansuy JM, Rostaing L, Keane F, Ijaz S, Izopet J, Dalton HR. Hepatitis E virus and neurologic disorders. *Emerg Infect Dis.* 2011; 17:173-179.
6. Kamani P, Baijal R, Amarapurkar D, Gupte P, Patel N, Kumar P, Agal S. Guillain-Barre syndrome associated with acute hepatitis E. *Indian J Gastroenterol.* 2005;

- 24:216.
7. Sood A, Midha V, Sood N. Guillain-Barré syndrome with acute hepatitis E. *Am J Gastroenterol.* 2000; 95:3667-3668.
  8. Bandyopadhyay D, Ganesan V, Choudhury C, Kar SS, Karmakar P, Choudhary V, Banerjee P, Bhar D, Hajra A, Layek M, Mukhopadhyay S. Two uncommon causes of Guillain-Barre syndrome: Hepatitis E and Japanese encephalitis. *Case Rep Neurol Med.* 2015; 2015:759495.
  9. Kumar S, Stecher G, Tamura K. MEGA7: Molecular evolutionary genetics analysis version 7.0 for bigger datasets. *Mol Biol Evol.* 2016; 33:1870-1874.
  10. Yuki N, Hartung HP. Guillain-Barre syndrome. *N Engl J Med.* 2012; 366:2294-2304.
  11. Zheng X, Yu L, Xu Q, Gu S, Tang L. Guillain-Barre syndrome caused by hepatitis E infection: Case report and literature review. *BMC Infect Dis.* 2018; 18:50.
  12. Stevens O, Claeys KG, Poesen K, Saegeman V, Van Damme P. Diagnostic challenges and clinical characteristics of hepatitis E virus-associated Guillain-Barre syndrome. *JAMA neurol.* 2017; 74:26-33.
  13. Ji SB, Lee SS, Jung HC, Kim HJ, Kim HJ, Kim TH, Jung WT, Lee OJ, Song DH. A Korean patient with Guillain-Barre syndrome following acute hepatitis E whose cholestasis resolved with steroid therapy. *Clin Mol Hepatol.* 2016; 22:396-399.
  14. Fukae J, Tsugawa J, Ouma S, Umezu T, Kusunoki S, Tsuboi Y. Guillain-Barre and Miller Fisher syndromes in patients with anti-hepatitis E virus antibody: A hospital-based survey in Japan. *Neurol Sci.* 2016; 37:1849-1851.
  15. Lei JH, Tian Y, Luo HY, Chen Z, Peng F. Guillain-Barre syndrome following acute co-super-infection of hepatitis E virus and cytomegalovirus in a chronic hepatitis B virus carrier. *J Med Virol.* 2017; 89:368-372.
  16. Higuchi MA, Fukae J, Tsugawa J, Ouma S, Takahashi K, Mishiro S, Tsuboi Y. Dysgeusia in a patient with Guillain-Barre syndrome associated with acute hepatitis E: A case report and literature review. *Intern Med.* 2015; 54:1543-1546.
  17. Perrin HB, Cintas P, Abravanel F, *et al.* Neurologic disorders in immunocompetent patients with autochthonous Acute Hepatitis E. *Emerg Infect Dis.* 2015; 21:1928-1934.
  18. van den Berg B, van der Eijk AA, Pas SD, Hunter JG, Madden RG, Tio-Gillen AP, Dalton HR, Jacobs BC. Guillain-Barre syndrome associated with preceding hepatitis E virus infection. *Neurology.* 2014; 82:491-497.
  19. Chen XD, Zhou YT, Zhou JJ, Wang YW, Tong DM. Guillain-Barre syndrome and encephalitis/encephalopathy of a rare case of Northern China acute severe hepatitis E infection. *Neurol Sci.* 2014; 35:1461-1463.
  20. Scharn N, Ganzenmueller T, Wenzel JJ, Dengler R, Heim A, Wegner F. Guillain-Barre syndrome associated with autochthonous infection by hepatitis E virus subgenotype 3c. *Infection.* 2014; 42:171-173.
  21. Woolson KL, Forbes A, Vine L, *et al.* Extra-hepatic manifestations of autochthonous hepatitis E infection. *Aliment Pharmacol Ther.* 2014; 40:1282-1291.
  22. Comont T, Bonnet D, Sigur N, Gerdelat A, Legrand-Abravanel F, Kamar N, Alric L. Acute hepatitis E infection associated with Guillain-Barre syndrome in an immunocompetent patient. *Rev Med Interne.* 2014; 35:333-336. (in French)
  23. Santos L, Mesquita JR, Rocha Pereira N, Lima-Alves C, Serrao R, Figueiredo P, Reis J, Simoes J, Nascimento M, Sarmento A. Acute hepatitis E complicated by Guillain-Barre syndrome in Portugal, December 2012--a case report. *Euro Surveill.* 2013; 18. pii: 20563.
  24. Sharma B, Nagpal K, Bakki Sanmegowda R, Prakash S. Hepatitis E with Gullain-Barre syndrome: Still a rare association. *J Neurovirol.* 2013; 19:186-187.
  25. Geurtsvankessel CH, Islam Z, Mohammad QD, Jacobs BC, Endtz HP, Osterhaus AD. Hepatitis E and Guillain-Barre syndrome. *Clin Infect Dis.* 2013; 57:1369-1370.
  26. Maurissen I, Jeurissen A, Strauven T, Sprengers D, De Schepper B. First case of anti-ganglioside GM1-positive Guillain-Barré syndrome due to hepatitis E virus infection. *Infection.* 2012; 40:323-326.
  27. Del Bello A, Arne-Bes MC, Lavayssiere L, Kamar N. Hepatitis E virus-induced severe myositis. *J Hepatol.* 2012; 57:1152-1153.
  28. Tse AC, Cheung RT, Ho SL, Chan KH. Guillain-Barre syndrome associated with acute hepatitis E infection. *J Clin Neurosci.* 2012; 19:607-608.
  29. Cronin S, McNicholas R, Kavanagh E, Reid V, O'Rourke K. Anti-glycolipid GM2-positive Guillain-Barre syndrome due to hepatitis E infection. *Ir J Med Sci.* 2011; 180:255-257.
  30. Loly JP, Rikir E, Seivert M, Legros E, Defrance P, Belaiche J, Moonen G, Delwaide J. Guillain-Barre syndrome following hepatitis E. *World J Gastroenterol.* 2009; 15:1645-1647.
  31. Khanam RA FM, Basunia RA, Ahsan AA. Guillain-Barré syndrome associated with acute HEV hepatitis. *Med Coll J.* 2008; 1:32-34.
  32. Kumar R, Bhoi S, Kumar M, Sharma B, Singh BM, Gupta BB. Guillain-Barré syndrome and acute hepatitis E: A rare association. *JACM.* 2002; 4:389-391.

(Received September 12, 2018; Revised December 7, 2018; Accepted December 18, 2018)

# West Nile virus encephalitis in a young immunocompetent female in Omaha Nebraska

Azka Latif\*, Vikas Kapoor, Erin Simmons, Jai Parekh, Venkata Andukuri

CHI Health, Creighton University, Omaha, NE, USA.

## Summary

One of the most common cause of arbovirus encephalitis in the United States of America (USA) is West Nile virus (WNV). In immunocompetent hosts, 70-80% of infected individuals have subclinical disease. However, in less than 1% of people infected by WNV it can become fulminant neuroinvasive disease associated with neurological morbidity. Herein, we discuss a case of neuroinvasive WNV disease with non-specific symptoms in an immunocompetent young female in Omaha. Our patient survived the acute phase of WNV encephalitis but has extended recovery to daily functioning. We also reviewed literature on WNV cases in immunocompetent individuals and to the best of our knowledge only 3 cases have been reported to date. The difference between reported cases and our case is her younger age, bilateral upper and lower extremity paralysis, 30 day hospitalization with significant morbidity leading to a prolonged stay at rehabilitation facility with residual cognitive and gross motor impairment. Usually WNV is not considered a differential in immunocompetent individuals which leads to delay in diagnosis, management and therefore increases mortality and morbidity. Therefore purpose of our case report is to raise awareness of atypical presentations of WNV infection in immunocompetent individuals in non-endemic area to emphasize the importance of early diagnosis and management.

**Keywords:** West Nile virus, encephalitis, neuroinvasive disease, arbovirus

## 1. Introduction

One of the most common cause of arbovirus encephalitis in the United States of America (USA) is West Nile virus (WNV) (1). Its distribution in North America is increasing, gradually spreading throughout the entire continental USA. Ever since the outbreak of WNV in New York in 1999, there have been 46,086 reported cases of WNV including 21,574 of neuroinvasive disease reported through 2016. The total number of deaths reported to the Centers for Disease Control and Prevention (CDC) from 1999 to 2016 are 1,888 (9%) and 129 (1%) due to neuroinvasive and non-neuroinvasive disease respectively (2).

In immunocompetent hosts, 70-80% of infected

individuals have subclinical disease. However, in less than 1% of people infected by WNV it can become fulminant neuroinvasive disease associated with significant neurological morbidity (3). Neurological manifestations most commonly reported include meningitis, encephalitis and acute flaccid paralysis. Factors contributing to life threatening disease with WNV include: age > 50 years (4), multiple comorbidities (5), pregnancy and transplantation (6). Common systemic presenting symptoms are fever, chills, nausea, vomiting, headache, macular and papular rash. Neurologic manifestations include nuchal rigidity, photophobia, acute focal weakness, altered deep tendon reflex. The initial presentation of severe disease with WNV is indistinguishable from other causes of meningoencephalitis, which may lead to delay in appropriate diagnostic testing as described below in our case. Initial testing for WNV with IgG/IgM with Polymerase chain reaction (PCR) is often negative due to its short viremic phase (6). The mortality associated with WNV neuroinvasive disease is 8% (7). Significant risk factors for death are those described above; older

Released online in J-STAGE as advance publication January 31, 2019.

\*Address correspondence to:

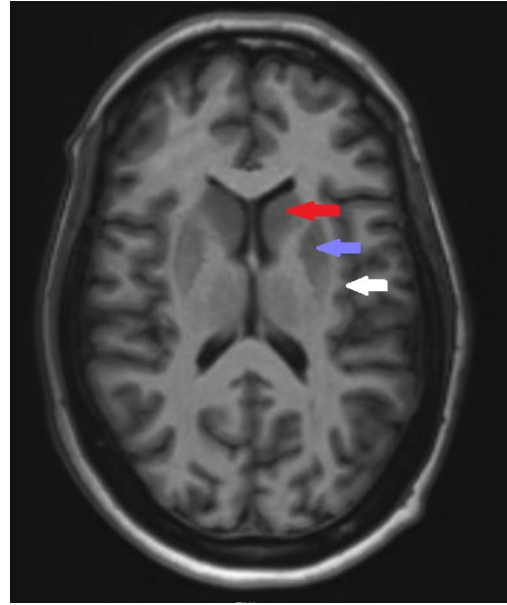
Dr. Azka Latif, CHI Health, Creighton University, 7500 Mercy Road, Omaha, NE 68124, USA.

E-mail: azkatalatif@creighton.edu

age, pre-existing comorbidities, and a compromised immune system. During a largest WNV outbreak in USA out of 221 hospitalized patients, 18% of patients who had encephalitis died, 46% were discharged to acute rehabilitation, 15% were discharged home with assistance, and only 20% successfully return home without assistance (8). Unlike the majority of individuals with WNV infection who are either asymptomatic or develop a self-limited flu-like illness, herein we describe a patient who developed the most severe form of symptomatic illness.

## 2. Case Report

Our patient is a 35-year-old immunocompetent African American female with a history of alcohol abuse disorder who presented to emergency department with 4 days of fever, nausea and abdominal pain. She received intravenous fluids and was discharged. Subsequently she began to experience headache, fevers, and diplopia 2-3 days later. She was hemodynamically stable with an unremarkable mental status exam. Physical examination was benign, with no nuchal rigidity or focal neurological deficits. Initial laboratory evaluation demonstrated a white blood cell count (WBC) of  $4.6 \times 10^3$  cells/uL, lactic acid level of 4.5 mmol/L, aspartate aminotransferase 516 u/L, alanine aminotransferase 229 u/L, phosphorus 2.0 mg/dL, magnesium 1.0 mg/dL. Noncontrast head computed tomography (CT) head was unremarkable. Magnetic resonance imaging (MRI) of the brain with contrast demonstrated T2 and FLAIR signal hyperintensity in the bilateral caudate nuclei, right/left putamen, deep and subcortical white matter of the bilateral parietal lobes (Figure 1). Cerebrospinal fluid analysis (CSF) yielded 13 red blood cells/uL, 183 WBC/uL with a differential of 64% neutrophils, 35% lymphocytes, and 1% monocytes, glucose 56 mg/dL, and protein 116 mg/dL. CSF culture, viral (Herpes simplex, Human herpes, Human parechovirus, Varicella zoster virus) and fungal (*Cryptococcus neoformans/gattii*) PCR were negative. She was treated empirically for bacterial meningitis with antimicrobials (Vancomycin + ciprofloxacin) and with acyclovir for herpes encephalitis. On hospitalization day 4, the patient became acutely hypoxic with worsening altered mental status. She was subsequently intubated and transferred to the intensive care unit. A repeat MRI of the brain on day 5 showed no changes from the previous MRI. After excluding other causes of altered mental status (*i.e.* metabolic encephalitis, fungal, viral, or bacterial meningoencephalitis) CSF IgM antibodies for WNV came back positive on day 6. The patient was treated symptomatically with intravenous fluids, respiratory support and prevention of secondary infections throughout the hospital course. She remained unresponsive for 11 days and progressively became more alert over the course of the 2 weeks. On day 18 of



**Figure 1.** Axial T2-weighted FLAIR magnetic resonance image of the brain at the level of caudate (red arrow), putamen (blue arrow) and white matter of parietal lobe (white arrow).

hospitalization patient was extubated and was discharged to inpatient acute rehabilitation unit on day 31 with cognitive impairment and residual paraparesis. Follow up with the patient revealed that after several months of physical therapy she is still dependent on walker for activities of daily life.

## 3. Discussion

WNV accounted for 231 cases as of 21 August 2018, with South Dakota reporting the highest number nationally. The total number of cases reported to the CDC in Nebraska is 14 (2). However, the total number of deaths in Nebraska in 2018 reported to the Nebraska Department of Health and Human Services is 2. Interestingly, 36% of seropositive individuals in Nebraska are aged 26-50 and 69% are of male gender (9). Our patient had no history of recent travel and sick contacts.

Despite many published reports of WNV disease in transplant recipients, to the best of our knowledge there has been only three cases reported in < 45-year-old immunocompetent adults without comorbidities. Mictail *et al.* 2011, reported a case of WNV meningitis in a 39-year-old women in NYC who presented with headache and spluttering. However, she was discharged after 5 days of hospitalization without residual symptoms (10). Similarly, the 2nd reported case is from Spain, reported by Kaptoul *et al.* 2007, in a healthy 21-year-old male who presented with fever, headache, nausea and vomiting. This patient was also discharged on day 7 of hospitalization without symptoms (11). The third is a 21-year-old female from Tuscany, Italy, who presented with fever, nausea, vomiting, nuchal

**Table 1. Reported cases of WNV encephalitis in < 45 year old individuals**

Author	Year	Age	Sex	Country	Presenting complaint	Management	Length of hospital stay	Residual symptoms
Kaptoul <i>et al.</i>	2007	21	Male	Spain	Fever, N/V, headache, hallucinations	NR	7 days	none
Mictail <i>et al.</i>	2011	39	Female	USA, NYC	Headache, spluttering	IVF	5 days	none
Cusi <i>et al.</i>	2011	21	Female	Italy, Tuscany	Fever, N/V nuchal rigidity, photophobia	NR	10 days	none
Latif <i>et al.</i>	2018	35	Female	USA, NE	Fever, N/V, diplopia	Symptomatic management with intubation, airway protection, IVF,	30 days	Cognitive impairment and residual paraparesis

N/V, nausea/vomiting; IVF, intravenous fluids; NR, not reported.

rigidity and photophobia. Her symptoms improved within 5 days and she was discharged after 10 days of hospitalization without residual symptoms (12). The subject of our current case presented with atypical symptoms which were initially thought to be secondary to alcohol withdrawal and delirium tremens. She remained on CIWA protocol for alcohol withdrawal for the initial 2-3 days. While she was young and had no comorbidities, her history of alcohol abuse with protein calorie malnutrition may have put her at increased risk of neuroinvasive WNV disease. Additionally, the severity and duration of clinical sequelae of WNV meningoencephalitis was prolonged in our patient. She survived the acute phase of WNV encephalitis but has extended recovery to daily functioning when compared to other reported cases to date. Similarities between cases reported earlier and our case include young age, immune competence, and no significant comorbidities. Above described patient were discharged from hospital without cognitive or physical impairment, however our patient even after several months of acute rehabilitation is still walker dependent (Table 1).

Furthermore, clear guidelines for management of life-threatening WNV disease are lacking (13). There have been review articles which tried to summarize some potential treatments (14-16). However, even the Centers for Disease Control's MNV disease therapeutics revised in February 2018 review has indicated the same. The treatment is mainly supportive. Experimental therapies such as ribavirin, human intravenous immunoglobulin and interferon-alpha have been described in the literature. However, the data supporting their use is limited, which poses a dilemma for physicians who are treating patients with neuroinvasive WNV disease. The purpose of this case report is to raise awareness of atypical presentations of WNV infection in immunocompetent individuals in non-endemic area which leads to delay in diagnosis and management.

#### 4. Conclusion

Given the increasing prevalence of WNV disease in the

USA, testing patients' CSF for additional studies include WNV infections in febrile immunocompetent individuals presenting with non-specific symptoms in summers even in non-endemic areas should be considered. Because of the significant risk of mortality and morbidity of WNV future research should focus on double-blind prospective clinical trials to assess the efficacy of ribavirin, human intravenous immunoglobulin, and interferon-alpha in the treatment of neuroinvasive disease. Doing so may yield promising results for those affected by neuroinvasive WNV disease.

#### References

- Lindsey NP, Lehman JA, Staples JE, Fischer M; Division of Vector-Borne Diseases, National Center for Emerging and Zoonotic Infectious Diseases, CDC. West Nile virus and other arboviral diseases – United States, 2013. *MMWR Morb Mortal Wkly Rep.* 2014; 63:521-526.
- Centers for Disease Control and Prevention, CDC. Final Cumulative Map and Data. <https://www.cdc.gov/westnile/statsmaps/cumMapsData.html> (Accessed September 20, 2018)
- Murray KO, Walker C, Gould E. The virology, epidemiology, and clinical impact of West Nile virus: A decade of advancements in research since its introduction into the Western Hemisphere. *Epidemiol Infect.* 2011; 139:807-817.
- Carson PJ, Borhardt SM, Custer B, Prince HE, Dunn-Williams J, Winkelman V, Tobler L, Biggerstaff BJ, Lanciotti R, Petersen LR, Busch MP. Neuroinvasive disease and West Nile virus infection, North Dakota, USA, 1999-2008. *Emerg Infect Dis.* 2012; 18:684-686.
- Martindale JL, Macias Konstantopoulos WL. Locally acquired West Nile encephalitis. *J Emerg Med.* 2012; 43:e435-e438.
- Winston DJ, Vikram HR, Rabe IB, Dhillon G, Mulligan D, Hong JC, Busuttill RW, Nowicki MJ, Mone T, Civen R, Tecele SA, Trivedi KK, Hocevar SN; West Nile Virus Transplant-Associated Transmission Investigation Team. Donor-derived West Nile virus infection in solid organ transplant recipients: Report of four additional cases and review of clinical, diagnostic, and therapeutic features. *Transplantation.* 2014; 97:881-889.
- Centers for Disease Control and Prevention (CDC). West



- Nile virus activity-United States, 2009. MMWR Morb Mortal Wkly Rep. 2010; 59:769-772.
8. Watson JT, Pertel PE, Jones RC, Siston AM, Paul WS, Austin CC, Gerber SI. Clinical characteristics and functional outcomes of West Nile Fever. *Ann Intern Med.* 2004; 141:360-365.
  9. Nebraska Department of Health and Human Services. West Nile Virus Surveillance Program. <http://dhhs.ne.gov/publichealth/Pages/wnv.aspx> (Accessed September 20, 2018)
  10. Mickail N, Klein NC, Cunha BA. West Nile virus aseptic meningitis and stuttering in woman. *Emerg Infect Dis.* 2011; 17:1567-1568.
  11. Kaptoul D, Viladrich PF, Domingo C, Niubó J, Martínez-Yélamos S, De Ory F, Tenorio A. West Nile virus in Spain: Report of the first diagnosed case (in Spain) in a human with aseptic meningitis. *Scand J Infect Dis.* 2007; 39:70-71.
  12. Cusi MG, Roggi A, Terrosi C, Gori Savellini G, Toti M. Retrospective diagnosis of West Nile virus infection in a patient with meningoencephalitis in Tuscany, Italy. *Vector Borne Zoonotic Dis.* 2011; 11:1511-1512.
  13. Kimberlin DW, Brady MT, Jackson MA, Long SS. Red Book, (2015): 2015 Report of the Committee on Infectious Diseases: *Am Acad Pediatrics.* 2015.
  14. Diamond MS. Progress on the development of therapeutics against West Nile virus. *Antiviral Res.* 2009; 83:214-227.
  15. Lim SP, Shi PY. West Nile virus drug discovery. *Viruses.* 2013; 5:2977-3006.
  16. Beasley DW. Vaccines and immunotherapeutics for the prevention and treatment of infections with West Nile virus. *Immunotherapy.* 2011; 3:269-285.

(Received October 10, 2018; Revised December 22, 2018; Accepted January 2, 2019)

# Leber's hereditary optic neuropathy: Severe vascular pathology in a severe primary mutation

Samuel Asanad<sup>1,2,\*</sup>, Elana Meer<sup>3</sup>, Jack J. Tian<sup>1</sup>, Michele Fantini<sup>1,4</sup>, Marco Nassisi<sup>1</sup>, Alfredo A. Sadun<sup>1,2</sup>

<sup>1</sup> Doheny Eye Institute, Los Angeles, CA, USA;

<sup>2</sup> Department of Ophthalmology, David Geffen School of Medicine at University of California Los Angeles, Los Angeles, CA, USA;

<sup>3</sup> Perelman School of Medicine, University of Pennsylvania, Philadelphia, PA, USA;

<sup>4</sup> Department of Ophthalmology, University of Udine, Udine, Italy.

## Summary

The purpose of the present article was to evaluate the previously unreported vascular alterations in Leber's Hereditary Optic Neuropathy (LHON) 3460 mitochondrial DNA (mtDNA) mutation. Among the three primary mtDNA mutations, namely 11778, 14484, and 3460, LHON 3460 is the most rare and historically recognized as having the poorest visual prognosis. Optical coherence tomography angiography (OCTA) is a novel imaging modality providing high-resolution microcirculation maps and enhancing visualization of the optic disc and peripapillary capillary beds. We herein exploit the advantages of OCTA, for the first time, to assess the optic nerve head and peripapillary microvasculature changes in an affected patient and compare these vascular changes with an asymptomatic carrier for LHON 3460, serving as a control. Vascular changes in LHON 11778 and 14484 have classically shown microvasculature attenuation localized specifically to the temporal peripapillary quadrant. In the present case, however, OCTA in LHON 3460, the most severe of the three mutational subtypes, illustrated significant vascular attenuation involving the nasal peripapillary region in addition to the temporal peripapillary microvascular changes classically seen in LHON. Our findings suggest that vascular measures may serve useful for objectively assessing mitochondrial disease. Further OCTA studies involving the nasal peripapillary region may be warranted to further understand vascular pathogenesis in LHON.

**Keywords:** Leber's hereditary optic neuropathy, optical coherence tomography angiography, peripapillary microvasculature, vascular biomarkers

## 1. Introduction

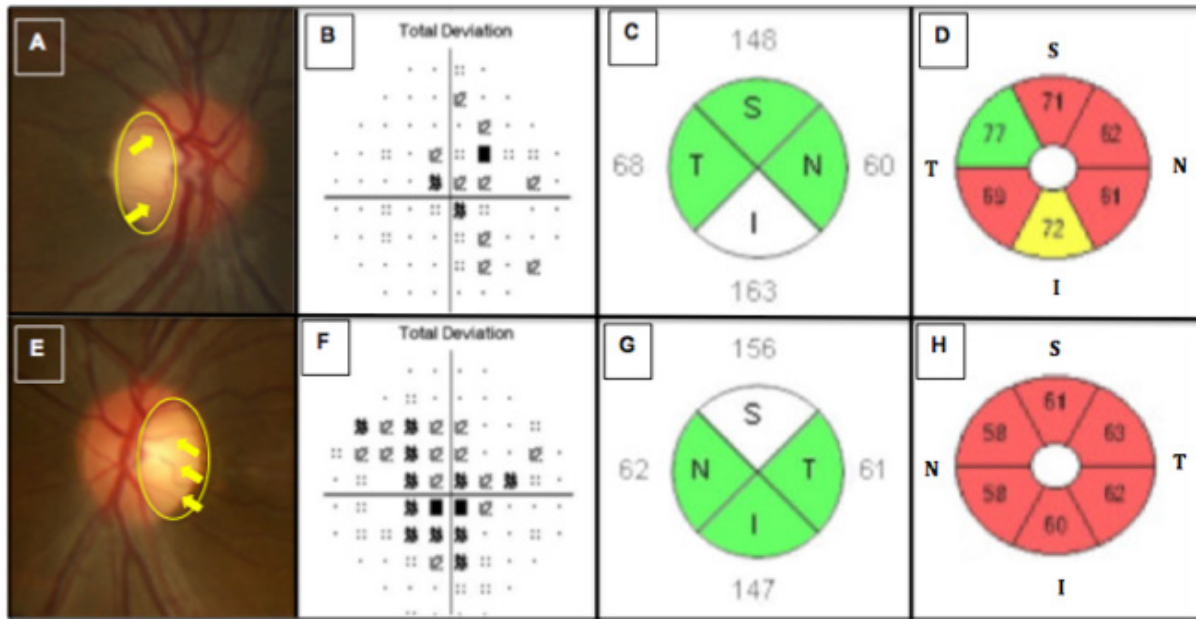
Vascular pathology in Leber's hereditary optic neuropathy (LHON) has been previously shown (1-3). These studies have looked at LHON across all mutational subtypes as a whole without assessing the severity of vascular attenuation attributed to the individual subtypes of LHON mitochondrial DNA

(mtDNA) mutations. Among the three primary mtDNA mutations, namely 11778, 14484, and 3460, LHON 3460 is the most rare and historically recognized as having the poorest visual prognosis (4). Individual reports of vascular changes in LHON 11778 and 14484 have been shown (5-7), however, an isolated vascular evaluation of the LHON 3460 primary mutation variant is lacking. Fundus photographs or fluorescein angiography have historically been used to describe oculo-vascular alterations in LHON (8-12). Optical coherence tomography angiography (OCTA), a novel imaging modality, can be used to noninvasively evaluate the peripapillary retinal and vascular circulations without the need for dye injection (13). Our laboratory has recently shown that assessing vascular changes in mitochondrial optic neuropathies using OCTA may

Released online in J-STAGE as advance publication January 31, 2019.

\*Address correspondence to:

Dr. Samuel Asanad, Department of Ophthalmology, David Geffen School of Medicine at University of California Los Angeles, 10833 Le Conte Ave, Los Angeles, CA 90095, USA. E-mail: sasanad@mednet.ucla.edu



**Figure 1.** Shows images of the right and left eyes in the LHON patient. Disc photographs (A, E) show temporal pallor (yellow circle) and peripapillary telangiectatic blood vessels along with vascular tortuosity (yellow arrows) for the right (A) and left eyes (E), respectively. Humphrey visual field testing revealed cecentral scotomas more severe in the left (F) than in the right eye (B), having mean deviations (MD) of -3.82 and -2.75, respectively. Spectral-Domain optical coherence tomography (SD-OCT) imaging of the peripapillary nerve fiber layer (pRNFL) (C,G) showed relative axonal swelling, most pronounced in the inferior and superior quadrants of the right (C) and left (G) eyes, respectively. SD-OCT imaging of the macular retinal ganglion cell and inner plexiform layers (RGC-IPL) (D,H) revealed diffuse ganglion cell atrophy, more severe in the primarily involved left eye (H) than the secondarily involved right eye (D).

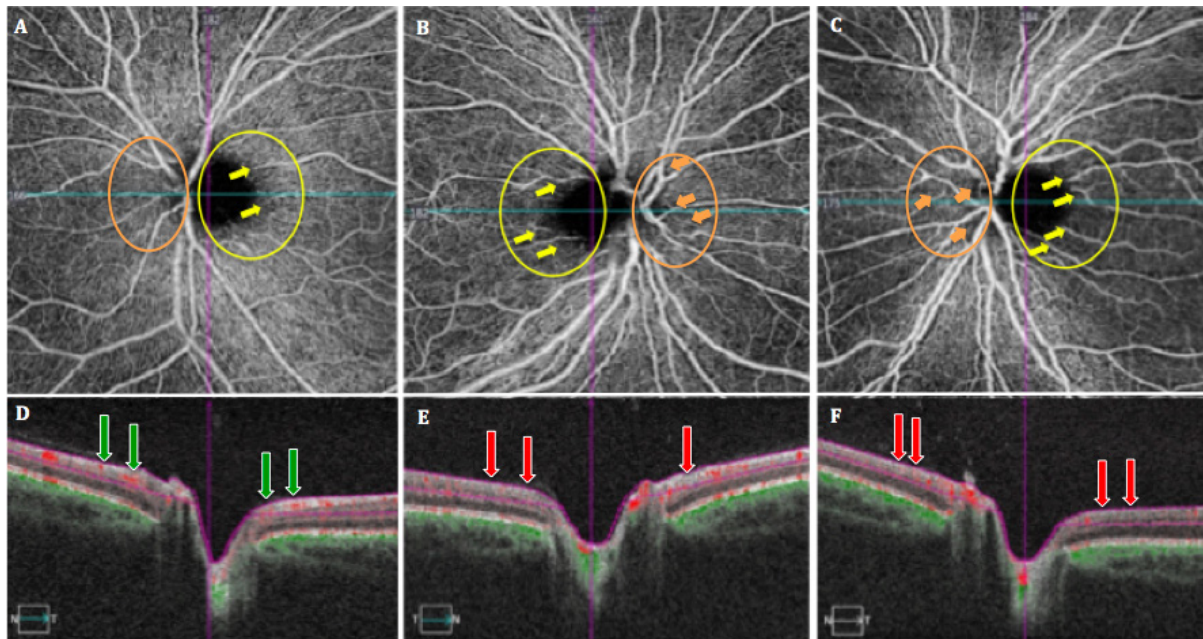
offer several advantages including supplementing our understanding of LHON pathophysiology (2,3). In contrast to 11778 and 14484, there are currently no clinical trials for the 3460 mtDNA mutation, the most severe of the three primary LHON mutations (4). Therefore, further evaluation of vascular parameters in mitochondrial optic neuropathies may be warranted to serve as an objective measure of disease progression, and monitoring the efficacy of purported therapies. Given the severe nature of the 3460 mtDNA mutation, we hypothesized that vascular attenuation would similarly be more severe in LHON 3460 expanding beyond the classically observed temporal peripapillary region. We hereby report the optic nerve head (ONH) and peripapillary microvasculature changes associated with LHON 3460 using an advanced imaging modality known as OCTA.

**2. Case Report**

A 22-year-old male with LHON, genetically confirmed for the 3460 mtDNA mutation, presented to the Doheny Eye Center in September 2018 with a 2-month history of vision loss beginning with the left eye, followed by vision loss in the right eye one month later. Family history was significant for bilateral vision loss in the mother's cousin at age 30. The patient endorsed alcohol consumption amounting to two to three bottles of beer per day. The patient also had a one-year history of exposure to kitchen smoke, having an occupation as a

restaurant server. The patient began Idebenone 250 mg PO TID and was scheduled for a 6-month follow up.

Best-corrected visual acuities (BCVA) were 20/200 in the right eye (OD) and 20/400 in the left eye (OS). Fundus examination revealed temporal pallor, peripapillary telangiectasias, and pseudo-edema in both eyes (OU) (Figures 1 A and 1E). Pupils were equal and reactive to light with no afferent pupillary defects. The patient exhibited dyschromatopsia on Ishihara plate testing, scoring 5/14 OD and 2/14 OS. Humphrey visual field (HVF) testing showed mild, bilateral cecentral scotomas (Figures 1B and 1F). Structural OCT displayed bilateral retinal nerve fiber layer (RNFL) pseudoedema (Figures 1C and 1G) and retinal ganglion cell complex (RGCC) thinning (Figures 1D and 1H). OCTA images of the ONH and peripapillary superficial vasculature were obtained using Spectral Domain-OCT (Cirrus HD-OCT, software V.6.0; Carl Zeiss Meditec, Inc., Dublin, CA, USA; the scan size of the optic nerve head was 6 × 6 mm). The same set of images were acquired for the patient's 38-year-old mother, sharing the mtDNA 3460 mutation, though asymptomatic with no significant past medical history, thus serving as a control and compared (Figure 2). Close inspection of the superficial vascular networks demonstrated visible attenuation of the temporal microvascular networks of the ONH and peripapillary area (yellow circles) along with peripapillary telangiectatic blood vessels and vascular tortuosity (yellow arrows) greater for the patient's right (Figure 2B) and left eyes (Figure



**Figure 2.** Shows optical coherence tomography angiography (OCTA) images (A-C) of the superficial vascular networks for the peripapillary nerve fiber layer (pRNFL) in the asymptomatic LHON mtDNA3460 carrier (patient's mother) (A), and affected LHON mtDNA 3460 patient right (B) and left (C) eyes. OCT cross-sections (D-F) show overlaying retinal flow (red) on OCT reflectance (gray scale).

2C) relative to the asymptomatic mother (Figure 2A). Intriguingly, however, vascular attenuation was also seen in the nasal peripapillary region as well (orange circles). OCT cross-sections (Figures 2D and 2F) overlaying retinal flow showed significant perfusion defects in the temporal and nasal peripapillary nerve fiber layer in the affected patient (Figures 2B and 2C: red arrows) relative to the asymptomatic mother, where perfusion was preserved in these corresponding areas (Figure 2D: green arrows).

### 3. Discussion

OCTA provides high-resolution, noninvasive visualization of the ONH and peripapillary microvasculature (13,14). We hereby characterize the vascular alterations associated with LHON 3460, the most severe of the three primary mtDNA mutations, as seen in an affected patient and compared with an asymptomatic carrier, serving as a control. Peripapillary vascular alterations, classically observed on funduscopy, have been referred to as hallmarks of LHON (9-11,15). OCTA of our affected LHON 3460 patient similarly exhibited these hallmark features of circumpapillary microangiopathy, dilated tortuous vasculature, and significant capillary dropout in the temporal region, corresponding with the small axons of the papillomacular bundle (PMB) (15,16). Similar vascular changes have been reported in LHON 11778 and 14484 (15-17). In contrast to 11778 and 14484 mutations, OCTA in our affected 3460 mtDNA patient illustrated significant vascular attenuation involving the nasal peripapillary region when compared

with the asymptomatic carrier, the temporal and nasal peripapillary microvasculature remained intact. In addition, nasal perfusion defects were more severe for the subacutely affected left eye (Figures 2C and 2F) compared to the acutely affected right eye (Figures 2B and 2E). Our laboratory recently investigated the vascular parameters in late disease stages in patients with chronic LHON (2). In the current case, however, we report the presence of nasal peripapillary vascular pathology even in the early stages of disease. These nasal peripapillary defects have not been observed in previously reported cases of in LHON 11778 and 14484 (5,7), which are classically referred to as less severe subtypes of LHON and exhibit vascular attenuation solely in the temporal peripapillary region. Further, OCTA of the asymptomatic LHON 3460 carrier revealed circumpapillary microangiopathy. This is consistent with previous studies and further confirms the subclinical vascular changes historically observed funduscopically in asymptomatic carriers (11,17).

Our findings demonstrate that the poor disease course characteristic of LHON 3460 is similarly reflected in the severity of vascular pathology. In our case of LHON 3460, vascular attenuation extended beyond the temporal peripapillary region and also involved the nasal peripapillary area. This supports the preferential involvement of the small axons comprising the PMB. However, the present study also illustrates that in cases of severe mitochondrial dysfunction such as in LHON 3460, surrounding peripapillary areas may also be secondarily involved. In conclusion, vascular changes may serve as useful objective measures of disease. To

date, clinical trials are solely in place for LHON 11778, the most common and least severe mutational subtype (4,15). Additional OCTA studies assessing the severity of vascular changes attributed to LHON mutational subtypes individually may be warranted to further understand LHON pathophysiology and navigate future directions for potential treatments of severe disease.

## References

- Balducci N, Cascavilla ML, Ciardella A, La Morgia C, Triolo G, Parisi V, Bandello F, Sadun AA, Carelli V, Barboni P. Peripapillary vessel density changes in Leber's hereditary optic neuropathy: A new biomarker. *Clin Exp Ophthalmol*. 2018; 46:1055-1062.
- Borrelli E, Balasubramanian S, Triolo G, Barboni P, Sadda SR, Sadun AA. Topographic macular microvascular changes and correlation with visual loss in chronic Leber hereditary optic neuropathy. *Am J Ophthalmol*. 2018; 192:217-228.
- Ghasemi Falavarjani K, Tian JJ, Akil H, Garcia GA, Sadda SR, Sadun AA. Swept-source optical coherence tomography angiography of the optic disk in optic neuropathy. *Retina*. 2016; 36 Suppl 1:S168-S177.
- Yu-Wai-Man P, Chinnery PF. Leber Hereditary Optic Neuropathy. *GeneRev*. 2016. <https://www.ncbi.nlm.nih.gov/books/NBK1174/> (accessed November 10 2018).
- De Rojas JO, Rasool N, Chen RWS, Horowitz J, Odel JG. Optical coherence tomography angiography in Leber hereditary optic neuropathy. *Neurology*. 2016; 87; 2065-2066.
- Gaier ED, Gittinger, JW, Cestari DM, Miller JB. Peripapillary capillary dilation in Leber hereditary optic neuropathy revealed by optical coherence tomographic angiography. *JAMA Ophthalmol*. 2016; 134:1332-1334.
- Matsuzaki M, Hiramami Y, Uyama H, Kurimoto Y. Optical coherence tomography angiography changes in radial peripapillary capillaries in Leber hereditary optic neuropathy. *Am J Ophthalmol Case Rep*. 2018; 9:51-55.
- Nikoskelainen EK, Huoponen K, Juvonen V, Lamminen T, Nummelin K, Savontaus ML. Ophthalmologic findings in Leber hereditary optic neuropathy, with special reference to mtDNA mutations. *Ophthalmology* 1996;103:504-514.
- Nikoskelainen E, Hoyt WF, Nummelin K. Ophthalmoscopic findings in Leber's hereditary optic neuropathy. I. Fundus findings in asymptomatic family members. *Arch Ophthalmol*. 1982; 100:1597-1602.
- Nikoskelainen E, Hoyt WF, Nummelin K. Ophthalmoscopic findings in Leber's hereditary optic neuropathy: II. The fundus findings in the affected family members. *Arch Ophthalmol*. 1983; 101:1059-1068.
- Nikoskelainen E, Nummelin K, Hoyt WF, Schatz H. Fundus findings in Leber's hereditary optic neuroretinopathy III. Fluorescein angiographic studies. *Arch Ophthalmol*. 1984; 102:981-989.
- Jia Y, Tan O, Tokayer J, Potsaid B, Wang Y, Liu JJ, Kraus MF, Subhash H, Fujimoto JG, Hornegger J, Huang D. Split-spectrum amplitude-decorrelation angiography with optical coherence tomography. *Opt Express*. 2012; 20:4710-4725.
- Wang X, Jia Y, Spain R, Potsaid B, Liu JJ, Baumann B, Hornegger J, Fujimoto JG, Wu Q, Huang D. Optical coherence tomography angiography of optic nerve head and parafovea in multiple sclerosis. *Br J Ophthalmol*. 2014; 98:1368-1373.
- Akil H, Falavarjani KG, Sadda SR, Sadun AA. Optical coherence tomography angiography of the optic disc; an overview. *J Ophthalmic Vis Res*. 2017; 12:98-105.
- Sadun AA, La Morgia C, Carelli V. Mitochondrial optic neuropathies: Our travels from bench to bedside and back again. *Clin Exp Ophthalmol*. 2013; 41:702-712.
- Pan BX, Ross-Cisneros FN, Carelli V, Rue KS, Salomao SR, Moraes-Filho MN, Moraes MN, Berezovsky A, Belfort R Jr, Sadun AA. Mathematically modeling the involvement of axons in Leber's hereditary optic neuropathy. *Invest Ophthalmol Vis Sci*. 2012; 53:7608-7617.
- Sadun AA, Salomao SR, Berezovsky A, Sadun F, DeNegri AM, Quiros PA, Chicani F, Ventura D, Barboni P, Sherman J, Sutter E, Belfort R Jr, Carelli V. Subclinical carriers and conversion in leber's hereditary optic neuropathy: A prospective psychosocial study. *Trans Am Ophthalmol Soc*. 2006; 104:51-61.

(Received November 19, 2018; Revised January 3, 2019; Accepted January 7, 2019)

# Anesthesia management of arthroscopic ankle arthrodesis for a hemophilia patient after living-donor liver transplantation

Reiko Shibata\*, Ryo Orii, Rie Ako

Department of Anesthesia, Research Hospital, The Institute of Medical Science, The University of Tokyo, Tokyo, Japan.

## Summary

Hemophilia is an X-linked recessive inherited coagulation disorder. We report the anesthesia management of a hemophilia patient who underwent arthroscopic ankle arthrodesis after living-donor liver transplantation due to cirrhosis. The 35-year-old male patient with hemophilia B was diagnosed with cirrhosis due to hepatitis C virus at the age of 23 years and underwent biologically-related partial liver transplantation at the age of 29 years. As a result, the activity of factor IX activity became normal and blood product treatment became unnecessary, but the patient required long-term immunosuppression. Perioperative coagulation factor activity monitoring was performed and an immunosuppressive drug that had been preoperatively administered were continued. General anesthesia was administered by inhalation. There was no significant fluctuation in perioperative factor IX activity. This case illustrates that even in patients with hemophilia B after living-donor liver transplantation undergoing an orthopedic surgical procedure, anesthesia management can safely be performed without perioperative coagulation factor replacement.

**Keywords:** Hemophilia, living-donor liver transplantation, hemostatic management

## 1. Introduction

Hemophilia is an X-linked genetic bleeding disorder. Hemophilia A is caused by coagulation factor VIII abnormality, and hemophilia B is caused by factor IX abnormality (1). Careful perioperative hemostatic management is required for patients with hemophilia. Coagulation factor replacement therapy and hemostatic monitoring are usually recommended (2).

We report the experienced anesthesia management of an orthopedic surgery patient with hemophilia B who had undergone living-donor liver transplantation for cirrhosis due to the hepatitis C virus (HCV) infection. The patient's liver function was normal and his factor IX coagulation activity was high and more than 180%. He had been taking an immunosuppressive drug since the time of his liver transplantation. We performed hemostatic

monitoring and perioperative management. The patient did not require coagulation factor replacement therapy. There were no complications such as postoperative bleeding and infection. We report the details of the case to augment the limited existing literature and describe the experience with anesthesia management in this setting.

## 2. Case Report

The patient was a 35-year-old male, 172 cm tall and 110 kg in weight. Hematoma first appeared at the age of 2 years old and severe hemophilia B (factor IX deficiency) was diagnosed at 5 years old, treated with blood preparation replacement therapy. Cirrhosis caused by hepatitis C virus infection and bulky splenomegaly were diagnosed at 23 years old with repeated variceal hemorrhage and refractory ascites. The patient received viral treatment with interferon and ribavirin, but no effect was found and the patient developed liver function. At the age of 29 years, he underwent living-donor transplantation from a healthy donor. Factor IX replacement therapy was used for hemostatic management during liver transplantation and the patient required coagulation factor replacement therapy until postoperative day 2. There were no major complications

Released online in J-STAGE as advance publication February 22, 2019.

\*Address correspondence to:

Dr. Reiko Shibata, Department of Anesthesia, Research Hospital, The Institute of Medical Science, The University of Tokyo, 4-6-1, Shirokanedai, Minato-ku, Tokyo 108-8639, Japan.

E-mail: p-reirei@ims.u-tokyo.ac.jp

**Table 1. Perioperative liver function and coagulation study**

Items	5/12	6/17	6/23	6/29 (operation day)	6/30	7/2	7/6	7/13
AST (U/L)	27	24		68	32.7	24	29	29
ALT (U/L)	21	18		32	27	21	24	24
T-bil (mg/dL)	0.8	1.5			0.9	0.7	0.6	0.7
Plt ( $\times 10^4$ )	12.3	35.7		33.6	33.2	35.0	46.1	39.0
PT (sec.)	12.3		12.4	12.9	13.4	13.4	12.5	13.1
PT (%)	86		85	78	73	83	78	76
PT-INR	1.08		1.09	1.18	1.18	1.10	1.13	1.15
APTT (sec.)	24.7		26.9	25.8	25.8	26.6	26.3	26.6
Fib (mg/dL)	476		573	487	487	640	617	600
D-dimer	1.1							
Factor IX	181.3		151.5		167.7	178.9	172.1	1,635

AST, aspartate aminotransferase; ALT, alanine aminotransferase; T-bil, total bilirubin; Plt, platelet; PT, prothrombin time; INR, International normalized ratio; APTT, activated partial thromboplastin time; Fib, Fibrinogen.

during the perioperative period. Oral administration of immunosuppressive drugs was started, but no coagulation factor products were required.

However, the patient developed worsening arthropathy and had difficulty in walking at about 33 years of age. At 35 years old, he was referred to our hospital's department of joint surgery and arthroscopic ankle joint arthrodesis was scheduled. On perioperative examination, no abnormality was observed in blood biochemical examination and physiological testing. The preoperative factor IX activity was as high as 181.3%.

The patient took tacrolimus for immunosuppression, nifedipine for hypertension, uruso for hepatoprotection, furosemide and azosemide for edematous prevention. He was hospitalized 14 days before the operation for preoperative examination and rehabilitation. We planned general anesthesia by subconscious bronchoscopic endotracheal intubation because of obesity.

In the early morning of the operation day, nifedipine and tacrolimus was orally administered. The patient was sedated with fentanyl and midazolam and endotracheal intubation was performed with propofol under bronchoscopy. Anesthesia was maintained with desflurane and remifentanyl. The surgery was completed without a change in circulatory dynamics in particular using a tourniquet. The operation time was 226 minutes, and the anesthesia time was 339 minutes, bleeding volume was 57 ml. We administered non-steroidal anti-inflammatory drugs for postoperative analgesia.

Table 1 shows the results of perioperative liver function and coagulation system testing. Both preoperatively and postoperatively, factor IX activity was more than 150%. Bleeding was not observed and blood product support was not required. After recovery without notable complications and rehabilitation, the patient left the hospital on the 32nd postoperative day. Routine postoperative follow-up at our hospital was scheduled.

### 3. Discussion

Hemophilia is an X-linked recessive inheritance-

related coagulation disorder. Affected individuals have a deficiency or activity reduction of factor VIII or factor IX. Hemophilia A is attributed to factor VIII deficiency, and hemophilia B to abnormalities of IX (1). In Japan, the Nationwide Survey on Coagulation Disorders 2017 reported 5,326 patients with hemophilia A and 1,129 patients with hemophilia B (1). Individuals with hemophilia may develop arthropathy causing remarkable physical function deterioration due to severe deformation and contracture involving multiple joints due to repetitive intra-articular bleeding. Therefore, surgical treatment such as artificial joint replacement or arthroscopy synovial resection may be complicated by post-operative bleeding and viral infection (2-4).

HCV infection in hemophilia patients is due to the administration of non-heated concentrate formulations used before 1986. Individuals who used unheated preparations before the current heated formulations were approved have a nearly 100% rate of infection (5). Also, many patients are coinfecting with human immunodeficiency virus. It has been reported that the progression to chronic liver disease is faster in individuals with concomitant HCV and human immunodeficiency viral infection (6,7). Interferon and antiviral drugs have been used to treat HCV, but they do not completely cure the infection and many patients progress to cirrhosis and liver cancer.

Living-donor liver transplantation may be performed for these patients. If the donor does not have hemophilia, the transplanted liver will produce the coagulation factor previously deficient in the recipient with hemophilia, and the recipient may no longer need treatment with coagulation factor preparations. However, it has been reported that coagulation factor production may be insufficient when the liver donor is deceased or is a hemophilia carrier (8). In our case, as in others, immunosuppressive treatment was continued during the perioperative period. Tacrolimus, which is commonly used in this setting, mainly suppresses interleukin-2 cytokine production from T-helper cells (9). The Nationwide Survey on Coagulation Disorders

**Table 2. Stage of hepatic disease in individuals with hemophilia**

Items	Hepatitis	Cirrhosis	Liver cancer	Hepatic failure	Liver transplantation
Hemophilia A	1,029	92	56	1	8
Hemophilia B	224	54	17	0	3
Total	1,253	146	73	1	11

The original source of data is Project entrusted by Ministry of Health, Labor and Welfare. Nationwide Survey on Coagulation Disorders 2017. Published by Japan Foundation for AIDS Prevention (1).

**Table 3. The characteristics of 184 hemophilic patients who underwent surgery in our hospital (2006-2015)**

Characteristics	Cases (%)
Hemophilia cases underwent surgery	
THA or re THA	23 (12.5)
TKA or re TKA	82 (44.6)
TEA	2 (1.1)
TAA	1 (0.5)
Arthroscopic surgery	34 (18.5)
Other	42 (22.8)
Age median (range) years	41 (13-72)
Sex	
Male	182 (98.9)
Female	2 (1.1)
Diagnosis	
Hemophilia A	142 (77.2)
Hemophilia B	40 (21.7)
Factor VII deficiency	1 (0.5)
Von Willebrand disease	1 (0.5)
Infections disease	
HCV(-) HIV(-)	27 (14.7)
HCV(+) HIV(-)	109 (59.2)
HCV(-) HIV(+)	1 (0.5)
HCV(+) HIV(+)	47 (25.5)
Preoperative infection	
-	174 (94.6)
+	10 (5.4)

THA or re THA, Total Knee Arthroplasty or re Total Knee Arthroplasty; TKA or re TKA, Total Knee Arthroplasty or re Total Knee Arthroplasty; TEA, Total Elbow Arthroplasty; TAA, Total Ankle Arthroplasty.

2017 in Japan shows the stage of the liver disease in individuals with blood coagulation disorder (Table 2). 11 cases of liver transplantation were reported.

Most patients with hemophilia require perioperative hemostatic management with supplementation of the deficient coagulation factor according to the extent of surgery and related treatments; in these patients, we apply the hemostatic treatment guidelines for patients with congenital hemophilia by The Japanese society on Thrombosis and Hemostasis (10). For arthroscopic surgery, the clotting factor target peak level should be maintained at 100% or more, and additional infusion should generally be continued intravenously to maintain a minimum factor level of at least 80% (1). Our hospital has handled a large number of hemophilia cases; from 2006 to 2015, 184 patients with hemophilia underwent surgery at our facility (Table 3) (11).

In this case, liver function was normal because the patient, who had developed hepatic failure due to complications of HCV infection, received a segmental

liver transplant from a living-donor who did not have hemophilia. The transplanted liver generated sufficient coagulation factors and normalized the recipient's hemostatic function. However, hemophilic arthropathy progressed and made walking difficult without a cane. For this reason, arthroscopic arthrodesis was scheduled. On preoperative examination, the patient's factor IX activity was 180%. Perioperative hemostasis monitoring was performed but coagulation factor replacement therapy was not needed. We did not observe problems during the operation. Neither bleeding nor infection occurred during the perioperative period, and liver function remained normal.

This is the first report of orthopedic surgery in our knowledge, but there have been no previous reports of anesthesia experiences for patients with hemophilia and cirrhosis who have undergone partial living-donor liver transplantation. In this patient with hemophilia B status-post living-donor liver transplantation, we were able to safely perform anesthesia management for the elective orthopedic surgery without coagulation factor supplementation (12).

## References

1. Project entrusted by Ministry of Health, Labor and Welfare. Nationwide Survey on Coagulation Disorders 2017. Published by Japan Foundation for AIDS Prevention. [http://api-net.jfap.or.jp/library/alliedEnt/02/images/h29\\_research/h29\\_research.pdf](http://api-net.jfap.or.jp/library/alliedEnt/02/images/h29_research/h29_research.pdf) (accessed on November 1, 2018) (in Japanese)
2. Mehta KD, Ragni MV. Bleeding and liver transplantation outcomes in haemophilia. *Haemophilia*. 2017; 23:230-237.
3. Bergstrom K, Stevens A, Srivaths L, Economides J, Yee DL. Hemophilia B acquired from liver transplantation: A case report and literature review. *Haemophilia*. 2015; 21:e328-e330.
4. Baker JF, Maleki F, Broderick JM, McKenna J. Arthroscopic ankle arthrodesis for end-stage hemophilic arthropathy of the ankle. *Haemophilia*. 2014; 20:e97-e99.
5. Yotuyanagi H. Treatment of hepatitis, cirrhosis, the liver cancer in patients with hemophilia. *Frontiers in Haemophilia*. 2016; 3:23-27. (in Japanese)
6. Eguchi S, Sayama A, Hidaka M, Takatsuki M, Muraoka I, Tomonaga T, Kanamatu T. Liver transplantation for patients with human immunodeficiency virus and hepatitis C virus coinfection with special reference to hemophilic recipients in Japan. *Surg Today*. 2011; 41:1325-1331.
7. Tsukada K, Sugawara Y, Kaneko J, Tamura S, Tachikawa N, Morisawa Y, Okugawa S, Kikuchi Y, Oka S, Kimura



- S, Yatomi Y, Makuuchi M, Kokudo N, Koike K. Living donor liver transplantations in HIV-and hepatitis C virus-coinfected hemophiliacs: Experience in a single center. *Transplantation*. 2011; 91:1261-1264.
8. Togashi J, Akamatsu N, Tanaka T, Sugawara Y, Tsukada K, Kaneko J, Arita J, Sakamoto Y, Hasegawa K, Kokudo N. Living donor living transplantation for hemophilia with special reference to the management of perioperative clotting factor replacement. *Liver Transpl*. 2016; 22:366-370.
  9. Suzuki.S. Basis of post-transplantation immunosuppressive therapy. *IRYO*. 1999; 53:205-210. (in Japanese)
  10. Fujii T, Amano A, Atumi T *et al*. A guideline for management of hemophilia patients without inhibitor in Japan: Revised edition 2013. The Japanese Society on Thrombosis and Hemostasis. 2013; pp.1-21. (in Japanese)
  11. Hirose J, Takedani H, Nojima M, Koibuchi T. Risk factors for postoperative complications of orthopedic surgery in patients with hemophilia: Second report. *J Orthop*. 2018; 15:558-562.
  12. Ono K, Hirose J, Chang SH, Kubota M, Kinkawa J, Noguchi M, Takedani H. Orthotropic live transplantation for cirrhosis from hepatitis C virus leads to correction of factor IX deficiency allowing for ankle arthroplasty without factor replacement in a patient with moderate hemophilia B. *Blood Coagul Fibrinolysis*. 2018; 29:131-134.

(Received November 28, 2018; Revised January 30, 2019; Accepted February 4, 2019)

# Budd-Chiari Syndrome in Behçet's Disease successfully managed with immunosuppressive and anticoagulant therapy: A case report and literature review

Christian Mario Amodeo Oblitas<sup>1</sup>, Francisco Galeano-Valle<sup>1,2,3,\*</sup>, Neera Toledo-Samaniego<sup>1</sup>, Blanca Pinilla-Llorente<sup>4</sup>, Jorge Del Toro-Cervera<sup>1,2,3</sup>, Arturo Álvarez-Luque<sup>5</sup>, Alejandra García-García<sup>1</sup>, Pablo Demelo-Rodríguez<sup>1,2,3,6</sup>

<sup>1</sup> Venous Thromboembolism Unit, Department of Internal Medicine, Hospital General Universitario Gregorio Marañón, Madrid, Spain;

<sup>2</sup> Instituto de Investigación Sanitaria Gregorio Marañón, Madrid, Spain;

<sup>3</sup> Universidad Complutense de Madrid, Madrid, Spain;

<sup>4</sup> Department of Internal Medicine, Hospital General Universitario Gregorio Marañón, Madrid, Spain;

<sup>5</sup> Vascular & Interventional Radiology Unit, Hospital General Universitario Gregorio Marañón, Madrid, Spain;

<sup>6</sup> Universidad CEU San Pablo, Madrid, Spain.

## Summary

Behçet's Disease (BD) is a rare, chronic and recurrent inflammatory multisystemic condition of unknown origin that can affect any tissue. The vascular system is involved in 5-40% of cases of BD, including venous and arterial beds and it has a relapsing course. Budd-Chiari syndrome (BCS) is a rare complication of BD with a frequency of < 5% among patients with vascular involvement and is more frequent in men (89.5%). Two clinical presentation groups of BCS related to BD have been described: the "symptomatic" form and the "silent" form. We present a case of BD in a young woman presented as symptomatic severe BCS with rapid progression of coagulopathy reaching a spontaneous INR of 1.74 and increased ascites by ultrasound control. BD was confirmed through clinical history. The patient was treated with a high-dose pulse of corticosteroids and cyclophosphamide with a strikingly favorable response in the first forty-eight hours. Although several studies have demonstrated a survival improvement with the use of transjugular intrahepatic portosystemic shunt in patients with severe BCS, it was discarded due to the lack of evidence of this procedure in patients with BD and the fact that it could trigger a vascular pathergy phenomenon. Vascular BD should be suspected in recurrent venous and/or arterial thrombosis since it is associated with high morbidity and mortality. Immunosuppressive treatment is critical for the management of vascular involvement in BD. However, the role of anticoagulation is debatable. We suggest an algorithm for the management of BCS associated with BD.

**Keywords:** Behçet's disease, Budd-Chiari syndrome, immunosuppressants, anticoagulation, transjugular intrahepatic portosystemic shunt

## 1. Introduction

Behçet's Disease (BD) is a rare, chronic and recurrent

Released online in J-STAGE as advance publication February 22, 2019.

\*Address correspondence to:

Dr. Francisco Galeano-Valle, Hospital General Universitario Gregorio Marañón, C/. Doctor Esquerdo, 46, 28007, Madrid, Spain.

E-mail: paco.galeano.valle@gmail.com

inflammatory multisystemic condition classified as vasculitis of unknown origin that can affect any tissue of the economy (mucocutaneous, ocular, cardiovascular arterio-venous, central nervous system, gastrointestinal, joint, among others). An aberrant response of different immunological pathways in relation to triggers (infectious or environmental) in predisposed subjects has been postulated in the pathogenesis of the disease, typically the human leukocyte antigen (HLA) class I gene: HLA-B51. BD is sometimes referred to as the "Silk

Route disease" because it is mainly distributed in those regions. The mean age of onset is usually in the third decade and both genders are affected equally. To date there is no specific test to confirm the diagnosis of BD, which is based on clinical criteria (1-3).

BD is unique among other vasculitis as it usually affects the venous rather than the arterial vessels. BD shows a tendency to thrombosis associated with vascular inflammation. In fact, lower extremity vein thrombosis (LEVT) can be considered as the hallmark of the vascular involvement. Vascular involvement is an early manifestation of BD that affects predominantly men, and its prevalence shows a wide range (5-40%) in the published literature (1,4).

Budd-Chiari syndrome (BCS) is a rare complication in BD with a frequency of < 5% among patients with vascular involvement. It is developed due to thrombosis of suprahepatic veins and/or inferior vena cava (IVC), and has two different clinical presentations: a symptomatic presentation, with a high mortality (up to 60%) and manifested as abdominal pain, ascites and collateral circulation on the abdominal wall; and a silent presentation, with a better prognosis (10% mortality) and manifested without ascites but with efficient collateral formation (5).

Immunosuppressants, with or without glucocorticoids, are essential in the management of vascular involvement in BD. They have been shown to reduce the relapse rate and to prolong survival in several retrospective studies. In patients with BD, conditions associated with higher mortality as BCS require an early and aggressive medical treatment, including cyclophosphamide and glucocorticoid pulses. In resistant cases, anti-tumor necrosis factor (TNF) agents could also be effective (5,6). Whether to add anticoagulants to prevent recurrent thrombosis has been debated (5,7). Several retrospective studies showed the inefficacy of anticoagulation alone or added to immunosuppressants in preventing recurrences (8) and it could increase the risk of aneurysmal rupture (6,9,10). In the last decade, several studies have demonstrated a survival improvement with the use of transjugular intrahepatic portosystemic shunt (TIPS) in patients with severe BCS, remarking the use of TIPS as a definitive treatment prior to liver transplantation, and not only as a bridging treatment (11,12). However, there is scarce evidence regarding the efficacy and safety of this procedure in patients with BCS in the setting of BD and the fact that it could trigger a vascular pathergy phenomenon should be considered (5,10,13).

We present a case of BD in a young woman presented as symptomatic BCS successfully managed with immunosuppressive and anticoagulant therapy. Consequently, we review the management and prognostic implications and suggest an algorithm for the management of BCS associated with BD.

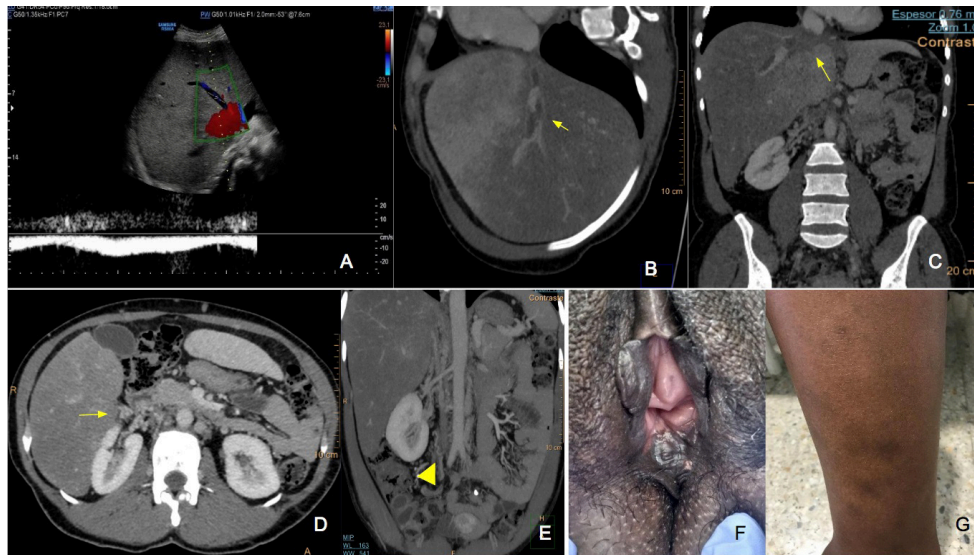
## 2. Case Report

A 29-year-old woman from Equatorial Guinea had a history of malaria one year before, long-term treatment with oral contraceptives, without toxic habits or cardiovascular risk factors. In April 2018, she presented to our emergency department with a 7-day history of diffuse abdominal pain, nausea and vomiting. In addition, the patient reported cough without expectoration, fever and dyspnea on moderate exertion. Physical examination revealed blood pressure 104/68 mm Hg, heart rate 96 bpm, oxygen saturation 98%, temperature 38.2°C. Lung auscultation disclosed crackles on the right base; abdomen was distended and painful to deep palpation focused on the upper right quadrant, with no signs of peritoneal irritation; pitting edema was found in both lower limbs. Laboratory tests showed hemoglobin 7.6 g/dL with a mean corpuscular volume of 73 fl, 8,200 leukocytes/uL, 140,000 platelets/ $\mu$ L, international normalized ratio (INR) of 1.53, fibrinogen 433 mg/dL, alanine aminotransferase 188 IU/L, gamma-glutamyl transferase 455 IU/L, alkaline phosphatase 355 IU/L, total bilirubin 0.5 mg/dL and creatinine 0.56 mg/dL. The urinalysis was normal. Doppler-ultrasound (US) of both lower limbs and abdominal computed tomography (CT) scan revealed extensive bilateral deep vein thrombosis involving IVC and both common iliac veins with extension to femoral veins, signs of ischemia of the right hepatic lobe, mild ascites and thrombosis of the right suprahepatic vein (SV) (Figures 1A-1E). Echocardiogram was remarkable for normal biventricular function with normal ejection fraction, with the presence of minimal pericardial effusion. An upper endoscopy did not show pathological findings.

The patient was admitted to the intermediate care unit; unfractionated heparin and diuretics were started. Initial evolution was poor, with rapid progression of coagulopathy reaching a spontaneous INR of 1.74 and increased ascites by ultrasound control. Considering the extension and atypical location of the thrombosis, and the presence of fever, differential diagnosis was broad and included infectious, autoimmune and malignant causes, mainly hematological.

Other tests were performed. Human immunodeficiency virus, hepatitis C virus and blood cultures were negative. A thick drop test and Plasmodium antigen ruled out the presence of acute infection by *Plasmodium spp.* A pulmonary arteries angio-CT showed no signs of pulmonary embolism. Antinuclear antibodies, neutrophil cytoplasmic antibodies and antiphospholipid antibodies were negative and the immunoglobulin count was normal. Hematological findings were compatible with iron deficiency anemia and Coombs tests were negative.

Taking into account the clinical picture, especially the extension and the atypical location of thrombosis, BD was suspected and clinical history was extended. The patient recognized recurrent painful oral and genital ulcers for the last 10 years, and intermittently painful



**Figure 1.** (A), Hepatic doppler-ultrasound revealed thrombosis and absence of flow involving the right suprahepatic vein and partially the inferior vena cava; (B), Oblique coronal CT scan image showed thrombosis of the right hepatic vein and low attenuation of the right hepatic lobe in the venous phase; (C), Coronal CT image shows inferior vena cava chronic thrombosis and right hepatic vein thrombosis with thrombus head leaning out into the cava; (D), Axial CT scan shows low attenuation in the right hepatic lobe as an ischemic finding and chronic juxtarenal inferior vena cava thrombosis with hemiazygos hypertrophy; (E), Coronal CT scan image shows complete inferior vena cava thrombosis; (F), The gynecological examination revealed a well-defined painful ulcer in the left lower vaginal lip; (G), Intermittently painful pretibial nodules with residual hyperpigmentation for the last 2 years that resembled erythema nodosum.

pretibial nodules with residual hyperpigmentation for the last 2 years that resembled erythema nodosum. The gynecological examination revealed a well-defined painful ulcer in the left lower vaginal lip (Figures 1F and 1G). The patient met criteria for BD with vascular involvement, associated with BCS. Pathergy test was negative.

The patient was treated with high-dose pulse of corticosteroids and cyclophosphamide with a strikingly favorable response in the first forty-eight hours after the beginning of immunosuppressive therapy, including defervescence, improvement of ascites and edema in lower limbs, as well as correction of coagulopathy (INR 1.15). Previous to immunosuppressive therapy, serology tests to assess chemoprophylaxis were gathered: anti-HBs negative and anti-HBc positive, with DNA quantification for hepatitis B virus of 17 IU/mL (1.23 log), and interferon gamma release assay test was positive. Lamivudine and isoniazid were started as prophylaxis.

The patient received seven cycles of cyclophosphamide every fifteen days. An abdominal US performed one month later showed significant recovery of the venous blood flow in the right suprahepatic vein, without ascites. Besides, an US of both lower limbs disclosed partial recanalization in both iliac and femoral veins. Nine months later, she progressed favorably with occasional appearance of genital ulcers without other complications, and with good tolerance to oral treatment: she is currently treated with prednisone, azathioprine and colchicine. In addition, anticoagulant treatment with acenocoumarol has been maintained.

### 3. Discussion

The vascular system is involved in 5-40% of cases of BD, including venous and arterial beds and it has a relapsing course. BD is unique among other vasculitis as it usually affects veins rather than arteries and it has significant thrombotic tendency associated with vascular inflammation, which cannot be explained by thrombophilic factors. LEVT is the most common type of vascular involvement. On the other hand, some rare presentations of vascular affection as pulmonary artery aneurysms, cardiac involvement and BCS are associated with a significant morbidity and mortality (4,5,10).

BCS is defined as an outflow obstruction at one or several levels from small hepatic venules to the IVC junction with right atrium, as a result of thrombosis or secondary fibrosis of the mentioned territory. BCS can be primary or secondary-due to compression or external invasion of the venous system-, and its presentation varies from asymptomatic, subacute-chronic or acute-fulminant states (14-16). Clinically, patients usually present with abdominal pain, fever, ascites, hepatosplenomegaly, collateral circulation and lower limb edema; other more severe findings include upper gastrointestinal bleeding and hepatic encephalopathy. Jaundice is not frequent, but the increase in direct bilirubin levels is a poor prognosis factor. In addition, BCS has been associated with an increased risk of long-term development of hepatocellular carcinoma. The diagnosis of BCS is based on clinical history, analytical data (impaired liver function and a serum albumin-ascites concentration

gradient  $\geq 1.1$ ), and by demonstrating obstruction to the flow of the hepatic venous territory by non-invasive imaging techniques: hepatic doppler ultrasound (first step), three-phase CT-scan and magnetic resonance imaging. The biopsy is relegated to unclear cases and it shows a centrilobular pattern predominance which is not exclusive of the disease. Among the most frequent causes of BCS are hematological conditions, predominantly myeloproliferative syndromes. A therapeutic strategy has been proposed to manage primary BCS and consists of anticoagulation, correction of risk factors, diuretics and prophylaxis for portal hypertension. Other procedures including angioplasty for short-length venous stenoses, TIPS or liver transplantation are reserved for refractory cases (12,15,16).

The association between BCS and BD has previously been described and is a rare complication of BD with a frequency between 2-5% in those patients with vascular involvement. However, in "endemic" areas of the disease, BD is one of the main causes of BCS. Some distinctive features have been described in BCS associated with BD including: younger age, higher frequency in males, IVC occlusion rather than isolated thrombosis of the hepatic veins, rare involvement of the portal system, better response to the immunosuppressive therapy compared to anticoagulation, and poor response to vascular interventions. Two clinical presentation groups of BCS related to BD have been described: the "symptomatic" form and the "silent" form. The former is presented with liver failure (ascites, increased bilirubin and prolonged INR) and is associated with 60% of mortality, and the later, with a better prognosis (10% of mortality) is manifested without ascites but with efficient collateral formation (5,17).

We performed a systematic review in PubMed using the terms "Budd-Chiari syndrome", "Behçet's disease" and "Behçet's syndrome" in English and Spanish languages on the 10th of January 2019 and 65 articles were found. We excluded case reports, review articles and case series of BD with incomplete information of the subgroup of patients with BCS. Therefore, ten articles were included (Table 1 and Table 2). The vast majority were men (89.5%) with a mean age between 18 and 41 years. The most common clinical features were ascites (46-100%), abdominal pain (40-100%), hepato-splenomegaly (29-100%), abdominal collateral circulation (25-100%), jaundice (19-100%) and fever (16-50%). Our patient had most of those symptoms (abdominal pain, fever and ascites). Interestingly, clinical findings of the patients are similar to our case report, however, the management has evolved over time. In other words, surgical management has decreased after the beginning of the use of immunosuppressants. Immunosuppressants and biological therapy are the most common therapeutic options in the last decade for BCS and BD (7,17-25).

Immunosuppressants, with or without glucocorticoids,

are essential in the management of vascular involvement in BD. They have been shown to reduce the relapse rate and to prolong survival in several retrospective studies. In patients with BD, conditions associated with higher mortality like BCS require an early and aggressive medical treatment, including cyclophosphamide and glucocorticoid pulses. In resistant cases, anti-tumor necrosis factor (TNF) agents could also be effective (1,4,6,8). Whether to add anticoagulants to prevent recurrent thrombosis has been debated (5,7). Several retrospective studies showed the inefficacy of anticoagulation alone or added to immunosuppressants in preventing recurrences (8). Anticoagulation could increase the risk of aneurysmal rupture (6,9,10). Nevertheless, the tolerance of anticoagulation therapy was satisfactory in patients with low bleeding risk after ruling out pulmonary artery aneurysms and it could be used in refractory venous thrombosis (4,6).

In the last decade, several studies have demonstrated a survival improvement with the use of angioplasty/stenting or TIPS in patients with BCS, remarking the use of TIPS as a definitive treatment prior to liver transplantation, and not only as a bridging treatment (11,12). However, there is very limited experience in patients with BCS and BD (only a few case reports). A case of a 45-y-o male with BD presented with acute BCS and was treated with percutaneous transluminal angioplasty showing a dramatic reduction of portal venous pressure. Immunosuppressive agents and anticoagulation were used for prevention of recurrent thrombosis (26). A case series reported 5 patients with BD and acute BCS showing reversal of liver damage and correction of hemodynamic disturbances, prolonged survival and good quality of life when side-to-side portacaval shunt was performed early in the course of BCS (22). There is no specific mention about the role of TIPS in the subgroup of BCS associated with BD in the latest update of the EULAR (European League Against Rheumatism) recommendations (6,12). In addition, it is important to note the risk of vascular pathergy phenomena after manipulating vessels in patients with BD, triggering vascular inflammation and consequently extension of the thrombosis (5,9,10). This is an important question that needs to be answered, taking into account the high mortality of BCS in the setting of BD and the management of BCS of any etiology includes TIPS for the most severe cases.

We suggest an algorithm for the management of BCS in the setting of BD (Figure 2). In case of BCS without a known etiology, every patient should undergo a quick revision of the clinical criteria for BD, especially if the patient is young (< 35 y-o). Once BD diagnosis is established, we should consider we are facing a case of vascular involvement of BD. BCS is a severe manifestation of vascular involvement of BD, and therefore it should be treated promptly and aggressively. The recommended treatment for BCS in


**Table 1. Clinical features of patients with Budd-Chiari syndrome associated with Behçet's disease (case series published in literature)**

Author (year) (ref.)	N	Mean age	Male (%)	Symptoms and Signs (%)							
				Abdominal pain	Ascitis	Jaundice	Hepato-splenomegaly	Fever	Abdominal collateral circulation	Portal thrombosis	
Seyahi <i>et al.</i> (2015) (17)	43	30	40/43 (93)	17/43 (40)	33/43 (77)	8/43 (19)	29/43 (71)	7/43 (16)	27/43 (63)	0/43	
Desbois <i>et al.</i> (2014) (7)	14	33	11/14 (79)	6/13 (46)	6/13 (46)	-	6/13 (46)	-	-	-	
Ben Ghorbel <i>et al.</i> (2008) (18)	7	29	7/7 (100)	-	6/7 (86)	1/7 (14)	7/7 (100)	-	7/7 (100)	-	
Seyahi <i>et al.</i> (2007) (19)	3	18	3/3 (100)	2/3 (67)	2/3 (67)	-	2/3 (67)	-	-	-	
Korkmaz <i>et al.</i> (2007) (20)	4	26	4/4 (100)	4/4 (100)	4/4 (100)	4/4 (100)	4/4 (100)	-	-	-	
Kuniyoshi <i>et al.</i> (2002) (21)	2	41	1/2 (50)	2/2 (100)	2/2 (100)	-	1/2 (50)	1/2 (50)	-	-	
Orloff <i>et al.</i> (1999) (22)	5	25	4/5 (80)	5/5 (100)	5/5 (100)	3/5 (60)	5/5 (100)	-	5/5 (100)	0/5 (0)	
Bayraktar (1997) (23)	14	37	12/14 (86)	-	10/14 (71)	-	4/14 (29)	-	2/8 (25)	4/14 (29)	
al-Dalaan <i>et al.</i> (1991) (24)	3	29	2/3 (67)	3/3 (100)	3/3 (100)	-	2/3 (67)	1/3 (33)	1/3 (33)	1/3 (33)	
Bismuth <i>et al.</i> (1990) (25)	20	29	19/20 (95)	3/-	19/20 (95)	9/20 (45)	2/-	-	1/3 (33)	0/20 (0)	

**Table 2. Management of patients with Budd-Chiari syndrome associated with Behçet's disease (case series published in literature)**

Author (year) (ref.)	N	Management								Mortality (%)
		AC	Colechicine	IS	anti-TNF	CS	Interventionist	Thrombolytic		
Seyahi <i>et al.</i> (2015) (17)	43	14/43	19/33	36/43	5/43	34/43	2/43 Angioplasty, 1/43 TIPS	5/43	20/43 (47)	
Desbois <i>et al.</i> (2014) (7)	14	14/14	1/14	12/14	4/14	12/14	2/14 Endovascular, 1/14 OLT, 1/14 Surgery♦	3/14	2/14 (14)	
Ben Ghorbel <i>et al.</i> (2008) (18)	7	7/7	-	2/7	0	6/7	0	-	1/7 (14)	
Seyahi <i>et al.</i> (2007) (19)	3	0	0	3/3	3/3	3/3	0	0	2/3 (67)	
Korkmaz <i>et al.</i> (2007) (20)	4	4/4	2/4	4/4	-	4/4	0	-	1/4 (25)	
Kuniyoshi <i>et al.</i> (2002) (21)	2	1/2	-	0	-	1/2	2/2 Surgery♦	-	1/2 (50)	
Orloff <i>et al.</i> (1999) (22)	5	5/5	-	-	-	-	5/5 SSPCS	-	1/5 (20)	
Bayraktar (1997) (23)	14	-	-	-	-	-	-	-	10/14 (71)	
al-Dalaan <i>et al.</i> (1991) (24)	3	3	-	1	-	3	2/3 Surgery♦	-	1/3 (33)	
Bismuth <i>et al.</i> (1990) (25)	20	15/20	15/20	-	-	15/20	5/20 Surgery♦	-	9/17 (52)	

♦Includes the following techniques: peritoneovenous shunt, mesocaval or mesoatrial shunting, portosystemic shunt. AC, anticoagulation; IS, immunosuppressants; anti-TNF, anti tumoral necrosis factor; CS, corticosteroids; OLT, orthotopic liver transplantation; SSPCS, side-to-side portacaval shunt; TIPS, transjugular intrahepatic portosystemic shunt.



**Figure 2. Algorithm for management of Budd-Chiari syndrome in Behçet's disease.** ♦Cyclophosphamide may be reserved for patients with extensive thrombosis or larger veins like IVC due to potential adverse events. \*Level of recommendation for anticoagulation is A1 in BCS according EASL guidelines, but level of recommendation for anticoagulation is III in BCS associated with BD according to EULAR guidelines. ▲There have been proposed three prognostic scores: the Rotterdam BCS score, the BCS-TIPS index score, and the revised Clichy score. ●Consider angioplasty/stenting as the first line decompressive procedure in patients with short hepatic vein stenosis or IVC stenosis. If there is no response TIPS is the treatment of choice (EASL 2015 for all causes of BCS). #Individualized decision is recommended due to the absence of specific evidence for BCS in the setting of BD; Consider the risk of vascular pathology phenomenon in BD. anti-TNF antibodies, anti tumoral necrosis factor antibodies; APS, antiphospholipid syndrome; BCS, Budd-Chiari syndrome; BD, Behçet disease; DVT, deep vein thrombosis; IBD, Inflammatory bowel disease; IVC, inferior vena cava; MPS, myeloproliferative syndrome; PNH, Paroxysmal nocturnal hemoglobinuria; TIPS, Transjugular intrahepatic portosystemic shunt.

BD is to start glucocorticoids and immunosuppressants. In case of no response, various options are possible, including anticoagulation and invasive procedures (Figure 2).

BD usually has a diagnosis delay of several years since the first medical visit. In our case, the presentation was an acute symptomatic BCS. The diagnostic process was quick and allowed a prompt therapeutic intervention.

Different therapeutic options were proposed, including anticoagulants, immunosuppressants and TIPS. We opted for intravenous heparin and a high-dose pulse of intravenous corticosteroids and intravenous cyclophosphamide and rejected TIPS due to the lack of evidence of this management in BD and the fact that could trigger a vascular pathergy phenomenon. Despite that our patient had an acute symptomatic presentation and liver failure, she fortunately showed a satisfactory and rapid response to the treatment.

In conclusion, acute BCS presented in the setting of BD is a severe condition with high mortality. Vascular involvement in BD is managed with immunosuppression. Other therapeutic options like anticoagulation or interventional vascular therapy have a secondary role and should be considered on an individual basis.

## References

1. Yazici H, Seyahi E, Hatemi G, Yazici Y. Behçet syndrome: A contemporary view. *Nat Rev Rheumatol*. 2018; 14:107-119.
2. Criteria for diagnosis of Behçet's disease. International Study Group for Behçet's Disease. *Lancet*. 1990; 335:1078-1080.
3. International Team for the Revision of the International Criteria for Behçet's Disease (ITR-ICBD). The International Criteria for Behçet's Disease (ICBD): A collaborative study of 27 countries on the sensitivity and specificity of the new criteria. *J Eur Acad Dermatol Venereol*. 2014; 28: 338-347.
4. Emmi G, Bettiol A, Silvestri E, Di Scala G, Becatti M, Fiorillo C, Prisco D. Vascular Behçet's syndrome: An update. *Intern Emerg Med*. 2018; Nov 29.
5. Seyahi E. Behçet's disease: How to diagnose and treat vascular involvement. *Best Pract Res Clin Rheumatol*. 2016; 30: 279-295.
6. Hatemi G, Christensen R, Bang D, *et al*. 2018 update of the EULAR recommendations for the management of Behçet's syndrome. *Ann Rheum Dis*. 2018; 77:808-818.
7. Desbois AC, Rautou PE, Biard L, Belmatoug N, Wechsler B, Resche-Rigon M, Zarrouk V, Fantin B, de Chambrun MP, Cacoub P, Valla D, Saadoun D, Plessier A. Behçet's disease in Budd-Chiari syndrome. *Orphanet J Rare Dis*. 2014 Sep13; 9:104.
8. Saleh Z, Arayssi T. Uptodate on the therapy of Behçet Disease. *Ther Adv Chronic Dis*. 2014; 5:112-134.
9. Wang H, Guo X, Tian Z, Liu Y, Wang Q, Li M, Zeng X, Fang Q. Intracardiac thrombus in patients with Behçet's disease: Clinical correlates, imaging features, and outcome: A retrospective, single-center experience. *Clin Rheumatol*. 2016; 35:2501-2507.
10. Galeano-Valle F, Demelo-Rodríguez P, Álvarez-Sala-Walther L, Pinilla-Llorente B, Echenagusia-Boyra MJ, Rodríguez-Abella H, Del-Toro-Cervera J. Intracardiac thrombosis in Behçet's Disease successfully treated with immunosuppressive agents: A case of vascular pathergy phenomenon. *Intractable Rare Dis Res*. 2018; 7:54-57.
11. Garcia-Pagán JC, Heydtmann M, Raffa S, *et al*. TIPS for Budd-Chiari syndrome: Long-term results and prognostic factors in 124 patients. *Gastroenterology*. 2008; 135:808-815.
12. European Association for the Study of the Liver. EASL Clinical Practice Guidelines: Vascular diseases of the liver. *J Hepatol*. 2016; 64:179-202.
13. Park MC, Hong BK, Kwon HM, Hong YS. Surgical outcomes and risk factors for postoperative complications in patients with Behçet's disease. *Clin Rheumatol*. 2007; 26:1475-1480.
14. Demelo-Rodríguez P, Del Toro-Cervera J. Platypnea-orthodeoxia syndrome and Budd-Chiari syndrome: An unreported association. *Med Clin (Barc)*. 2015; 144: 94-95. (in Spanish)
15. Valla DC. Primary Budd-Chiari syndrome. *J Hepatol*. 2009; 50:195-203.
16. Goel RM, Johnston EL, Patel KV, Wong T. Budd-Chiari syndrome: Investigation, treatment and outcomes. *Postgrad Med J*. 2015; 91: 692-697.
17. Seyahi E, Caglar E, Ugurlu S, Kantarci F, Hamuryudan V, Sonsuz A, Melikoglu M, Yurdakul S, Yazici H. An outcome survey of 43 patients with Budd-Chiari syndrome due to Behçet's syndrome followed up at a single, dedicated center. *Semin Arthritis Rheum*. 2015; 44:602-609.
18. Ben Ghorbel I, Ennaifer R, Lamloum M, Khanfir M, Miled M, Houman MH. Budd-Chiari syndrome associated with Behçet's disease. *Gastroenterol Clin Biol*. 2008; 32: 316-320.
19. Seyahi E, Hamuryudan V, Hatemi G, Melikoglu M, Celik S, Fresko I, Yurdakul S, Yazici H. Infliximab in the treatment of hepatic vein thrombosis (Budd-Chiari syndrome) in three patients with Behçet's syndrome. *Rheumatology (Oxford)*. 2007; 46: 1213-1214.
20. Korkmaz C, Kasifoglu T, Kebapçi M. Budd-Chiari syndrome in the course of Behçet's disease: Clinical and laboratory analysis of four cases. *Joint Bone Spine*. 2007; 74:245-248.
21. Kuniyoshi Y, Koja K, Miyagi K, Uezu T, Yamashiro S, Arakaki K, Mabuni K, Senaha S. Surgical treatment of Budd-Chiari syndrome induced by Behçet's disease. *Ann Thorac Cardiovasc Surg*. 2002; 8:374-380.
22. Orloff LA, Orloff MJ. Budd-Chiari syndrome caused by Behçet's disease: Treatment by side-to-side portacaval shunt. *J Am Coll Surg*. 1999; 188:396-407.
23. Bayraktar Y, Balkanci F, Bayraktar M, Calguneri M. Budd-Chiari syndrome: A common complication of Behçet's disease. *Am J Gastroenterol*. 1997; 92: 858-862.
24. al-Dalaan A, al-Balaa S, Ali MA, Huraib S, Amin T, al-Maziad A, al-Fadda M. Budd-Chiari syndrome in association with Behçet's disease. *J Rheumatol*. 1991; 18:622-626.
25. Bismuth E, Hadengue A, Hammel P, Benhamou JP. Hepatic vein thrombosis in Behçet's disease. *Hepatology*. 1990; 11:969-974.
26. Han SW, Kim GW, Lee J, Kim YJ, Kang YM. Successful treatment with stent angioplasty for Budd-Chiari syndrome in Behçet's disease. *Rheumatol Int*. 2005; 25:234-237.

(Received November 30, 2018; Revised January 17, 2019; Accepted February 2, 2019)



## A novel mutation in *CACNA1A* gene in a Saudi female with episodic ataxia type 2 with no response to acetazolamide or 4-aminopyridine

Hussein Algahtani<sup>1,\*</sup>, Bader Shirah<sup>2</sup>, Raghad Algahtani<sup>3</sup>, Mohammad H. Al-Qahtani<sup>4</sup>, Angham Abdulrahman Abdulkareem<sup>4</sup>, Muhammad Imran Naseer<sup>4</sup>

<sup>1</sup> King Abdulaziz Medical City/King Saud bin Abdulaziz University for Health Sciences, Jeddah, Saudi Arabia;

<sup>2</sup> King Abdullah International Medical Research Center/King Saud bin Abdulaziz University for Health Sciences, Jeddah, Saudi Arabia;

<sup>3</sup> King Saud bin Abdulaziz University for Health Sciences, Jeddah, Saudi Arabia;

<sup>4</sup> Center of Excellence in Genomic Medicine Research, King Abdulaziz University, Jeddah, Saudi Arabia.

### Summary

Episodic ataxia is a genetically heterogeneous neurological condition characterized by spells of incoordination and imbalance, often associated with progressive ataxia. Episodic ataxia type 2, caused by calcium voltage-gated channel subunit alpha1 A (*CACNA1A* MIM: 601011) mutation, is the most common form of episodic ataxia. It is characterized by recurrent attacks of imbalance associated with interictal nystagmus lasting hours to days and triggered by emotional stress or exercise. In this article, we report a novel heterozygous intronic variant c.5743+14A>G in the *CACNA1A* gene in a Saudi family. To the best of our knowledge, this variant has not been described in the literature or reported in public mutation databases. This report indicated that acetazolamide is not beneficial, and it may be even harmful to patients with episodic ataxia type 2 if used in later stages. In addition, treatment with 4-aminopyridine did not show any efficacy to improve walking or balance in our patient, which indicates the importance of early initiation of therapy before the later stages of the disease. Further research is needed to explore potential treatments for this challenging disease.

**Keywords:** *CACNA1A*, alpha-1A subunit, autosomal dominant cerebellar ataxia, novel Mutation, Saudi Arabia

### 1. Introduction

Episodic ataxia is a genetically heterogeneous neurological condition characterized by spells of incoordination and imbalance, often associated with progressive ataxia (1). Episodic ataxia type 2 has a wide range of expressivity among patients. The disease is characterized by paroxysmal attacks of ataxia, vertigo, and nausea that usually last hours to days. Associated symptoms of the attacks include dysarthria, dystonia, tinnitus, diplopia, headache, and hemiplegia (2). Approximately 50% of patients with this disease have

migraine headaches without loss of consciousness. Other less commonly reported manifestations include torticollis, intellectual disability, and psychiatric disorders. Initially, patients are usually asymptomatic between attacks, but with disease progression, they develop permanent cerebellar symptoms (3).

Mutations in the *CACNA1A* gene are associated with autosomal dominant neurological disorders including episodic ataxia, familial hemiplegic migraine, early infantile epileptic encephalopathy 42, and spinocerebellar ataxia 6 (4). More than 170 disease-causing variants in *CACNA1A* are reported in the Human Gene Mutation Database (HGMD). This includes missense variants (51.5%), nonsense variants (11.7%), splice variants (7.0%), small deletions (11.7%), small insertions (5.8%), gross deletions (9.4%), complex rearrangements (0.6%), and repeat variations (2.3%). Among these variants, 128 are implicated in ataxia phenotypes, mainly episodic ataxia (5).

\*Address correspondence to:

Dr. Hussein Algahtani, King Abdulaziz Medical City/King Saud bin Abdulaziz University for Health Sciences, P.O. Box: 12723, Jeddah 21483, Saudi Arabia. Contact No.: 00966556633130.  
E-mail: halgahtani@hotmail.com

Episodic ataxia type 2, caused by *CACNA1A* mutation, is the most common form of episodic ataxia. It is characterized by recurrent attacks of imbalance associated with interictal nystagmus lasting hours to days and triggered by emotional stress or exercise. The age of onset is usually in childhood or early adolescence (age range 2-32 years). Its prevalence has been estimated at lower than 1/100,000 (6).

The currently available treatments include acetazolamide and 4-aminopyridine (fampridine), which may reduce the frequency, severity, and duration of attacks but have no effect on the disease progression (6). In this article, we report a novel mutation in *CACNA1A* gene in a young Saudi lady with episodic ataxia type 2 with no response to acetazolamide or 4-aminopyridine.

## 2. Case Report

Proband III-2 is a 25-year-old Saudi woman presented with 9 years history of ataxia, imbalance, dysarthria, and difficulty swallowing. Initially, her symptoms were episodic with intermittent improvement between episodes. However, over the past five years, her disease became progressive. Her symptoms increased with time to the point that she needed a wheelchair due to inability to walk especially in dark rooms. There was no history of joint pain, skin rash, visual symptoms, mouth or genital ulcers, or gastrointestinal symptoms. The patient denied memory loss or psychiatric symptoms. Her past medical history was unremarkable including endocrine disorders, infections, sleep disorders, or trauma. Family history was positive for a similar condition. On examination, the patient was conscious and oriented with normal cognitive functions. She was dysarthric with scanning speech, and she had impaired saccadic eye movement. She also had impaired dorsal

column structure and pectus excavatum. The rest of her cranial nerve examination was normal. Motor examination showed 3/5 power in the upper limbs and 4/5 power in the lower limbs, and her reflexes were absent. Cerebellar examination showed dysmetria and dysdiadochinesia. She had difficulty walking without assistance. There were no associated skeletal deformities, and her fundus examination was normal. Gait examination showed wide-based gait with a tendency to fall to either side.

Extensive blood work including both routine and specific tests to rule out the cause of ataxia in this age group was negative. These include vitamin E level, vitamin B-12 level, blood smear for acanthocytes, viral serology, thyroid function test, serology for celiac disease, and lipoprotein electrophoresis. Genetic testing was sent, and the sequence analysis identified a heterozygous intron variant c.5743+14A>G in the *CACNA1A* gene, which is inherited in an autosomal dominant manner (Figure 1). This intronic variant has been identified in four heterozygous individuals in the Genome Aggregation Database (gnomAD,  $n > 120,000$  exomes and  $> 15,000$  genomes). Database curators have made every effort to exclude individuals with severe pediatric diseases from these cohorts. This variant is absent in the Greater Middle East (GME) Variome Project with 2,497 individuals analyzed. This variant has not been reported in public mutation databases or the literature. It is classified as a variant of uncertain significance according to the ACMG guidelines. According to the Human Splicing Finder *in silico* tool, this variant probably has no impact on splicing.

Additionally, our exome sequencing data showed a heterozygous carrier for three missense novel mutations in *POLG* gene (c.576G>T, p.(Glu192Asp)), *PNKP* (c.1160C>A, p.(Leu454Met)), and *ABCB7* (c.14C>T,

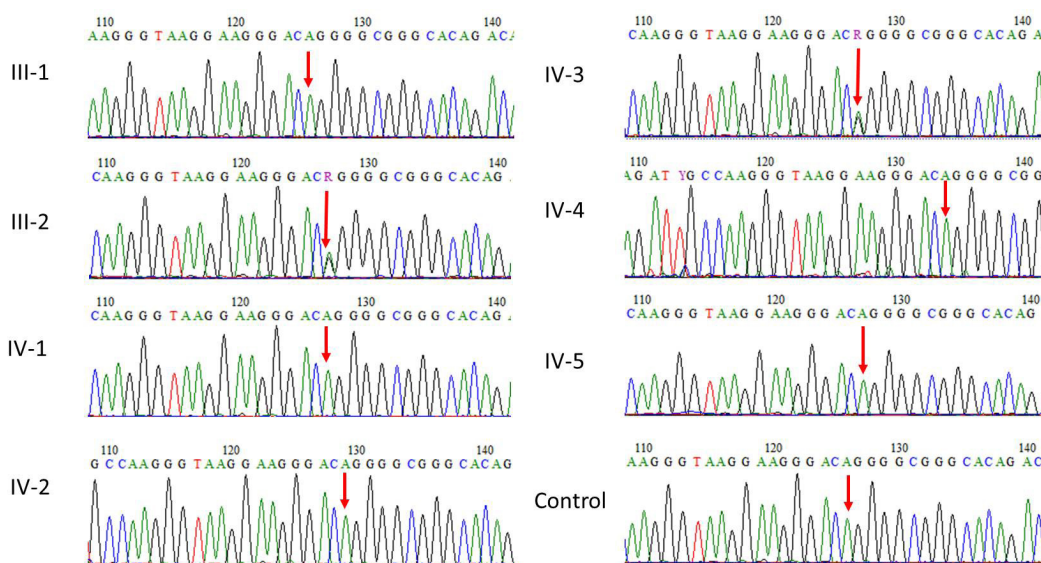


Figure 1. Sanger sequence analysis for validation of exome sequencing variant found in *CACNA1A* gene.

p.(Ala5Val)). The *PNKP* (c.1160C>A, p.(Leu454Met)) variant has previously been identified in clinical testing and classified as a variant of uncertain significance (ClinVar variation ID: 95478). To the best of our knowledge, the *POLG* gene (c.576G>T, p.(Glu192Asp)) and *ABCB7* (c.14C>T, p.(Ala5Val)) variants have not been reported in the literature or public mutation databases. As there is not enough data to support or rule out pathogenicity, these variants are classified as variants of uncertain significance. It has to be noted that both autosomal recessive and dominant inheritance patterns have been identified in the diseases caused by *POLG* mutations. *POLG*-related mitochondrial ataxia syndrome and mitochondrial DNA depletion syndromes are inherited in an autosomal recessive manner, but *POLG*-related progressive external ophthalmoplegia can also be inherited in an autosomal dominant manner. The disease caused by *PNKP* mutations is inherited in an autosomal recessive manner, and the disease caused by *ABCB7* mutations is inherited in an X-linked recessive manner. The patient is heterozygous for the identified variants.

The patient was also a heterozygous carrier for a pathogenic mutation in *TCTN1* (c.342-2A>G). This variant affects the acceptor splice site of intron 2. This variant has been identified as homozygous in patients with Joubert syndrome or Joubert-like

syndrome. Considering the current literature and the well-established role of the variant, it is classified as pathogenic. Our patient is heterozygous for the variant, and diseases caused by *TCTN1* mutations are inherited in an autosomal recessive manner. Thus, the identified variant is not sufficient to cause disease without another disease-causing variant in the same gene.

Magnetic resonance imaging (MRI) of the brain revealed moderate atrophy of the midbrain, pontine tegmentum, and vermis of the cerebellum with a mild degree of atrophic changes within the cord (Figure 2). Nerve conduction studies showed axonal sensory neuropathy with reduced SNAP amplitude in the bilateral median and ulnar nerves with absent unrecordable responses from the sural and superficial peroneal nerves bilaterally. In addition, low CMAP amplitude in both peroneal nerves was observed. Cardiac echocardiography was unremarkable with normal left ventricular size and systolic function. A 24-hour Holter monitor showed sinus bradycardia with marked sinus arrhythmia and a heart rate ranging from 37 to 122 beats per minute (average 69 beats per minute).

The detailed family pedigree was drawn after getting the detailed information from the parents as shown in Figure 3. Family and genetic counseling were offered

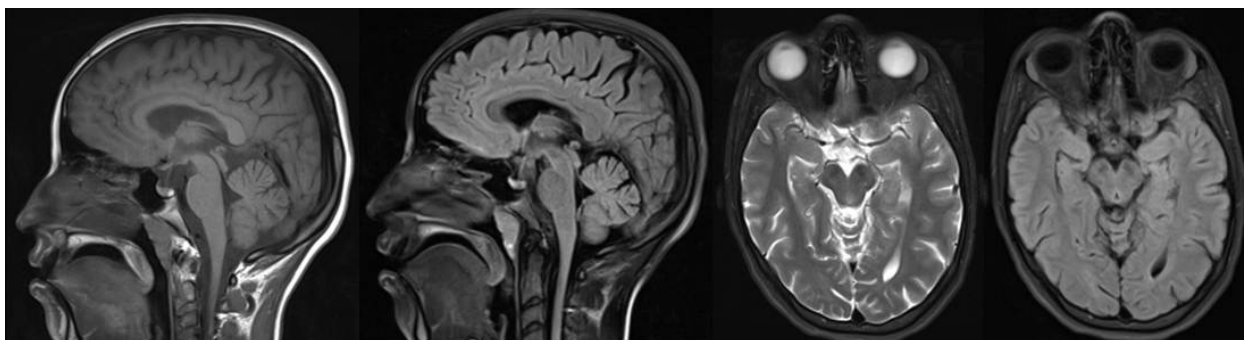


Figure 2. MRI of the brain showing moderate atrophy of the midbrain, pontine tegmentum, and vermis of the cerebellum with a mild degree of atrophic changes within the cord. MRI, magnetic resonance imaging.

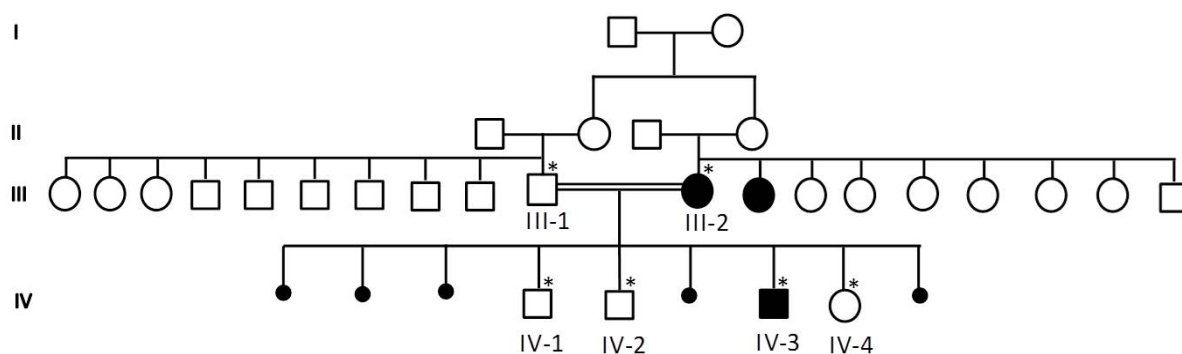


Figure 3. Family pedigree showing the details of the members of the family. The samples marked with asterisks were available for genetic testing.

through a genetic consultant. The patient was tried on both acetazolamide (up to 1 gram daily in two divided doses) and 4-aminopyridine with no improvement in her condition. In fact, she developed several side effects due to acetazolamide including paresthesias, polyuria, and drowsiness.

This study was approved by the Institutional Review Board (IRB) of King Abdullah International Medical Research Center (KAIMRC).

### 3. Discussion

Voltage-dependent calcium channels mediate the entry of calcium ions into excitable cells, and are also involved in a variety of calcium-dependent processes including muscle contraction, hormone or neurotransmitter release, and gene expression (7). Calcium channels are multisubunit complexes composed of alpha-1, beta, alpha-2/delta, and gamma subunits. The channel activity is directed by the pore-forming alpha-1 subunit, whereas the others act as auxiliary subunits regulating this activity. The distinctive properties of the calcium channel types are related primarily to the expression of a variety of alpha-1 isoforms, alpha-1A, B, C, D, E, and S (8).

The *CACNA1A* gene on chromosome 19p13.13 encodes the alpha-1A subunit, which is the pore-forming subunit of the voltage-dependent calcium channels. It is predominantly expressed in neuronal tissue, particularly Purkinje and granule cells of the cerebellum (9). These calcium channels mediate entry of calcium into the cells and regulate the pacemaking precision. These channels regulate the whole-cell calcium current density and the intrinsic excitability of Purkinje cells and granule cells, and exert major control over glutamate release at the parallel fiber onto Purkinje-cell synapses (10). Targeted deletions of *CACNA1A* in cerebellar granule cells or Purkinje cells result in altered cerebellar output by decreasing the excitatory drive on Purkinje cells or their ability to release neurotransmitters (10).

Our patient had clinical features similar to other patients with episodic ataxia type 2 caused by *CACNA1A* gene mutation but differed in the time of diagnosis. Most of the reported cases in the literature were diagnosed early in childhood when the disease was still episodic. Although early diagnosis does not seem to alter the natural history of the disease, it allows appropriate family counseling and planning and also leads to a better response to the available symptomatic treatment. Our patient did not have genetic testing to identify the responsible gene for many years due to unavailability of advanced genetic testing in most of the hospitals. With the current availability of molecular genetics in Saudi Arabia, the identification of responsible genes associated with a wide variety of diseases will be feasible. This progress is hoped to

eliminate delay in diagnosis of rare genetic diseases.

The whole exome sequencing performed on our patient identified several other variants in *POLG*, *PNKP*, *ABCB7*, and *TCTN1* genes. These variants are not related to the clinical phenotype of the patient. This is because she is a carrier for those identified variants and most of the disease caused by them are inherited in an autosomal recessive manner. Our patient's clinical phenotype does not fit the phenotype of diseases caused by mutations in these genes.

History and physical examination are of paramount importance in indicating a diagnosis of cerebellar ataxia. MRI of the brain is important in evaluating structural abnormalities and typically demonstrates atrophy of the cerebellar vermis (11). Genetic testing remains the only definitive diagnostic method to identify the responsible gene. Nuclear magnetic spectroscopy may demonstrate abnormal cerebellar intracellular pH levels and low cerebellar creatine. EMG typically shows absent myokymia, and single fiber EMG may demonstrate jitter and blocking (12).

Management of these patients mainly includes occupational and physical therapy for gait dysfunction and speech therapy. There is no currently available treatment that can cure the disease or alter the disease progression (13). Acetazolamide is an effective medication for controlling or reducing the frequency and severity of attacks, but it does not prevent the progression of the disease (14). In addition, recent studies showed that 4-aminopyridine (fampridine) might also be effective in reducing the frequency and duration of attacks. Prognosis is variable in these patients, but improvement in their condition is unlikely (15). We have recently reported our experience in the use of 4-aminopyridine in a patient with a rare hereditary ataxia with no response. This indicates that the management of patients with hereditary ataxias remains challenging (16).

The rate of consanguinity in Saudi Arabia is high ranging from 25% to 65%. This consanguinity favors the occurrence of genetic diseases, especially the diseases inherited in an autosomal recessive manner. It is important to educate the Saudi population about this fact to hopefully reduce the occurrence of rare and devastating diseases. We have previously reported several novel and rare mutations causing a wide variety of genetic neurological diseases in the Saudi community (16-24). This paper may be considered as an urgent call for action to address the consanguinity issue in Saudi Arabia.

In conclusion, we report a novel heterozygous intron variant c.5743+14A>G in the *CACNA1A* gene in a Saudi family. This report indicated that acetazolamide is not beneficial, and it may be even harmful to patients with episodic ataxia type 2 if used in later stages. In addition, 4-aminopyridine did not show any efficacy to improve walking or balance in our patient, which

indicates the importance of early initiation of therapy before the later stages of the disease. Further research is needed to explore potential treatments for this challenging condition.

## References

- Jen JC, Graves TD, Hess EJ, Hanna MG, Griggs RC, Baloh RW; CINCH investigators. Primary episodic ataxias: Diagnosis, pathogenesis and treatment. *Brain*. 2007; 130:2484-2493.
- Baloh RW. Episodic ataxias 1 and 2. *Handb Clin Neurol*. 2012; 103:595-602.
- Bertholon P, Chabrier S, Riant F, Tournier-Iasserve E, Peyron R. Episodic ataxia type 2: Unusual aspects in clinical and genetic presentation. Special emphasis in childhood. *J Neurol Neurosurg Psychiatry*. 2009; 80:1289-1292.
- Barros J, Damásio J, Tuna A, Alves I, Silveira I, Pereira-Monteiro J, Sequeiros J, Alonso I, Sousa A, Coutinho P. Cerebellar ataxia, hemiplegic migraine, and related phenotypes due to a CACNA1A missense mutation: 12-year follow-up of a large Portuguese family. *JAMA Neurol*. 2013; 70:235-240.
- Human Gene Mutation Database Professional 2017.2. <https://www.nihlibrary.nih.gov/resources/tools/human-gene-mutation-database-professional> (Accessed on December 6, 2018)
- Spacey S. Episodic Ataxia Type 2. In: Pagon RA, Adam MP, Bird TD *et al*: (eds) Seattle (WA): GeneReviews, 1993.
- Greenberg DA. Calcium channels in neurological disease. *Ann Neurol*. 1997; 42:275-282.
- Randall AD. The molecular basis of voltage-gated Ca<sup>2+</sup> channel diversity: Is it time for T?. *J Membr Biol*. 1998; 161:207-213.
- Rajakulendran S, Graves TD, Labrum RW, Kotzadimitriou D, Eunson L, Davis MB, Davies R, Wood NW, Kullmann DM, Hanna MG, Schorge S. Genetic and functional characterisation of the P/Q calcium channel in episodic ataxia with epilepsy. *J Physiol*. 2010; 588:1905-1913.
- Damaj L, Lupien-Meilleur A, Lortie A, Riou É, Ospina LH, Gagnon L, Vanasse C, Rossignol E. CACNA1A haploinsufficiency causes cognitive impairment, autism and epileptic encephalopathy with mild cerebellar symptoms. *Eur J Hum Genet*. 2015; 23:1505-1512.
- Mantuano E, Romano S, Veneziano L, *et al*. Identification of novel and recurrent CACNA1A gene mutations in fifteen patients with episodic ataxia type 2. *J Neurol Sci*. 2010; 291:30-36.
- Harno H, Heikkinen S, Kaunisto MA, Kallela M, Häkkinen AM, Wessman M, Färkkilä M, Lundbom N. Decreased cerebellar total creatine in episodic ataxia type 2: A 1H MRS study. *Neurology*. 2005; 64:542-544.
- Kotagal V. Acetazolamide-responsive ataxia. *Semin Neurol*. 2012; 32:533-537.
- Ilg W, Bastian AJ, Boesch S, Burciu RG, Celnik P, Claaßen J, Feil K, Kalla R, Miyai I, Nachbauer W, Schöls L, Strupp M, Synofzik M, Teufel J, Timmann D. Consensus paper: Management of degenerative cerebellar disorders. *Cerebellum*. 2014; 13:248-268.
- Hess E. A randomized trial of 4-aminopyridine in EA2 and related familial episodic ataxias. *Neurology*. 2011; 77:1996-1997.
- Algahtani H, Shirah B, Algahtani R, Naseer MI, Al-Qahtani MH, Abdulkareem AA. Ataxia with ocular apraxia type 2 not responding to 4-aminopyridine: A rare mutation in the SETX gene in a Saudi patient. *Intractable Rare Dis Res*. 2018; 7:275-279.
- Algahtani H, Shirah B. A novel mutation in the DNMT1 gene in a patient presenting with pure cerebellar ataxia. *J Genet Med*. 2017; 14:71-74.
- Algahtani H, Naseer MI, Al-Qahtani M, Abdulrahman SA, Boker F, Shirah B. Congenital insensitivity to pain with anhidrosis: A report of two siblings with a novel mutation in (TrkA) NTRK1 gene in a Saudi family. *J Neurol Sci*. 2016; 370:35-38.
- Algahtani H, Marzouk Y, Algahtani R, Salman S, Shirah B. Autosomal recessive cerebellar ataxia type 1 mimicking multiple sclerosis: A report of two siblings with a novel mutation in SYNE1 gene in a Saudi family. *J Neurol Sci*. 2017; 372:97-100.
- Algahtani H, Ghamdi S, Shirah B, Alharbi B, Algahtani R, Bazaid A. Biotin-thiamine-responsive basal ganglia disease: Catastrophic consequences of delay in diagnosis and treatment. *Neurol Res*. 2017; 39:117-125.
- Algahtani H, Ibrahim B, Shirah B, Aldarmahi A, Abdullah A. More than a decade of misdiagnosis of alternating hemiplegia of childhood with catastrophic outcome. *Case Rep Med*. 2017; 2017:5769837.
- Algahtani H, Alameer S, Marzouk Y, Shirah B. Urea cycle disorder misdiagnosed as multiple sclerosis: A case report and review of the literature. *Neuroradiol J*. 2018; 31:213-217.
- Algahtani H, Absi A, Bassuni W, Shirah B. Adult-onset hemophagocytic lymphohistiocytosis type 2 presenting as a demyelinating disease. *Mult Scler Relat Disord*. 2018; 25:77-82.
- Algahtani H, Shirah B, Alassiri AH, Habib BA, Almuhanna R, Ahamed MF. Limb-girdle muscular dystrophy type 2B: An unusual cause of proximal muscular weakness in Saudi Arabia. *J Back Musculoskelet Rehabil*. 2018; 31:999-1004.

(Received December 8, 2018; Revised February 20, 2019; Accepted February 24, 2019)

## Partial trisomy 9 (9pter->9q22.1) and partial monosomy 14 (14pter->14q11.2) due to paternal translocation t(9;14)(q22.1;q11.2) in a case of Dysmorphic features

Somprakash Dhangar, Seema Korgaonkar, Babu Rao Vundinti\*

National Institute of Immunohaematology (ICMR), K.E.M Hospital campus, Parel, Mumbai, India.

**Summary** Trisomy 9 including mosaic and partial trisomy is less frequently seen chromosomal abnormality in live born children. The pure or partial trisomy 9 frequently been reported in prenatal diagnosis and product of conception. However few studies reported partial trisomy 9 in live born children. In addition data on genotype and phenotype correlation of partial trisomy is not well understood except few case reports. Here we report a case of partial trisomy 9 and monosomy 14 with a 46,XY,der(9)t(9;14)(q22.1;q11.2)pat,-14 karyotype in a 5-year old dysmorphic child. The proband was confirmed as trisomic for 9pter->9q22.1 and monosomic for 14pter->q11.2 due to paternal t(9;14)(q22.1;q11.2) balanced translocation using a combination of conventional and molecular cytogenetic (fluorescence in situ hybridization, array-comparative genomic hybridization) techniques. The clinical features similar to pure trisomy 9 is due to duplication of the large region of chromosome 9. However, the present report of partial trisomy 9 and monosomy 14 is a novel case report and showing comparatively longer survival which have not been previously reported in the literature. The parent of the proband was counseled for the future pregnancies.

**Keywords:** Partial trisomy 9, partial monosomy 14, unbalanced translocation, developmental delay, dysmorphic features

### 1. Introduction

Trisomy 9 is one of the rare chromosomal abnormalities associated with complex phenotype involving multiple malformations of limbs, cardiac, renal and central nervous systems (1). The clinical severity in trisomy 9 is not precisely correlated with the extent of trisomic material (2). Prenatal growth retardation, postnatal mental retardation and early mortality are known to be associated with trisomy 9 (3). The trisomy 9 can classify as pure trisomy and partial trisomy 9 (4,5). The pure trisomy 9 can occurs due to different type of adjacent-2 segregation mechanism as well as non-disjunction of

chromosomes in one of the parent during gametogenesis (6). The partial trisomy includes somatic mosaicism and translocation. The phenotype associated with it relies on the number of cellular lines that are trisomic and the additional chromosome material translocated to different chromosomes (7,8). However, majority of the pure and partial trisomy 9 ends in spontaneous abortion (3,8).

The published literature of pure or partial trisomy 9 provides limited information mainly related to prenatal diagnosis, electively terminated pregnancies or autopsy cases and not on long time survivors of partial trisomy 9 (5,9,10). The developmental complications in partial trisomy 9 have been reported in few case studies (11). So far 150 cases of pure and partial trisomy 9 have been reported in the database of National organization for rare disorders (NORD) (12,13). However there is dearth of information regarding developmental status of pure or partial trisomy 9 cases in the literature.

Here, we report a novel case of partial trisomy 9 and monosomy 14 in a five year old child with dysmorphic features.

Released online in J-STAGE as advance publication February 25, 2019.

\*Address correspondence to:

Dr. Babu Rao Vundinti, National Institute of Immunohaematology (ICMR), 13<sup>th</sup> floor, new multistoried building, K.E.M Hospital campus, Parel, Mumbai 400012, India.  
E-mail: vbaburao@hotmail.com

## 2. Case Report

A 5-year old male child, the first born of a healthy non-consanguineous couple was referred to our clinic for chromosomal analysis due to delayed milestones and dysmorphic features. He had been born of full term normal delivery with moderately low birth weight. Mother's age was 33 years with no previous bad obstetric history and the father was 35 years old.

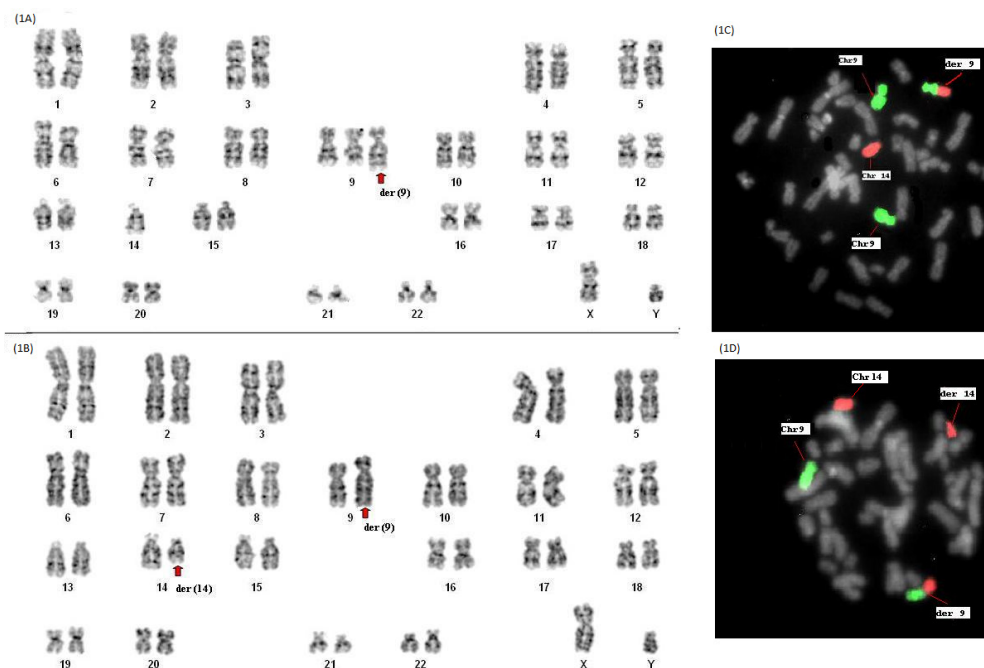
On clinical examination, the child had facial dysmorphic features like prominent forehead with mild macrocephaly, low hair line, slight downward slanting of the eyes with epicanthic folds, hypertelorism, low set ears, large pinnae, long face, bulbous nose, thin upper lip, long philtrum, high arched palate and webbed neck. The proband also had skeletal and limb anomalies including kyphoscoliosis rocker bottom feet, short middle interphalangeal elevated foot, clinodactyly of fifth finger and pilonidal sinus. Speech development was severely retarded and the gross and fine motor development was poor. The Social Quotient (SQ) was 80. The Magnetic resonance imaging (MRI) and Computer tomography (CT) scan of brain revealed generalized cerebral atrophy, dilated ventricles, and arachnoid cyst. The 2-Dimensional echocardiogram (2D-ECHO) reported tiny patent ductus arteriosus (PDA) with normal left ventricular output. Ultra sonography (USG) of abdomen revealed small size of both kidneys. Brainstem Evoked Response Audiometric (BERA) test revealed bilateral moderate to severe hearing loss. Ophthalmic examination showed telecanthus.

The study was carried out with the consent of one of the parent.

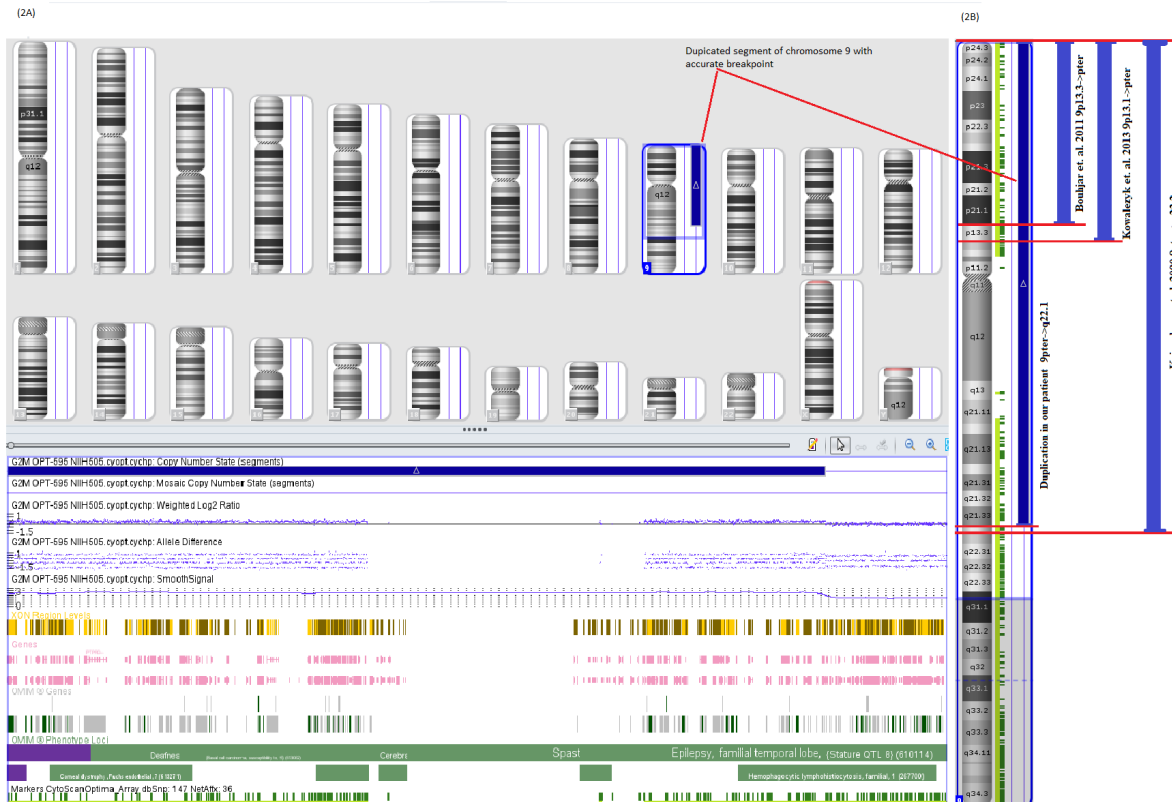
## 3. Cytogenetics

Peripheral blood cultures were set up at 37°C for 72 hours according to standard procedure (14). The cultures were stimulated with phytohaemagglutinin (PHA) arrested with colchicine (50 ug/mL) and treated with hypotonic solution (KCL- 0.56 g/100 mL). The cells were fixed in carnoy's solution (Methanol: Glacial acetic acid; 3:1). The chromosomal preparations obtained were subjected to GTG banding (15). At least 30 metaphases were scored and karyotype (approximately 400 band resolution) according to International System of Chromosome Nomenclature 2016 (ISCN 2016) (6). Applied Spectral Imaging software system (Inc. Carlsbad, USA) interfaced with Nikon 90i microscope (Japan) was used for analysis.

The chromosomal analysis of child revealed 46,XY,+der(9)t(9;14)(q22.1;q11.2)pat,-14 karyotype (Figure 1A). The karyotype of mother was normal while the father had balanced translocation 46,XY,t(9;14)(q22.1;q11.2) (Figure 1B). Fluorescence in situ hybridization (FISH) was carried out using centromere specific and whole chromosome painting probe (Kreatech, Leica biosystems, Germany) of chromosome 9 (Cat. No. KBI30009G) and 14 (Cat. No. KBI30014R). FISH results revealed partial trisomy 9 and monosomy 14 in proband (Figures 1C and 1D). The chromosome breakpoints further confirmed by array-CGH (CytoPrime



**Figure 1. Karyotype and FISH images of Proband and father of the affected child. (A),** GTG banded karyotype of proband showing 46,XY,+der(9)t(9;14)(q22.1;q11.2)pat,-14; **(B),** Balanced translocation showing 46,XY,t(9;14)(q22.1;q11.2) in father; **(C),** Whole chromosome painting (FISH) shows partial trisomy 9 [Green (9) and red (14)] in proband; **(D),** FISH image showing balanced translocation in father.



**Figure 2. Array-CGH findings. (A),** Array-CGH image showing duplication of chromosome 9, region 9pter->9q22.1 (Proband); **(B),** Array-CGH image showing duplicated region of chromosome 9 in our case and its comparison with previous studies.

microarray system with Chromosome Analysis Suite software designed by affymetrix). Array-CGH revealed arr[GRCh38] 9p24.3q22.1(203861\_87860633)x3 pat (Figures 2A and 2B). Array-CGH analysis shows a single copy gain of chromosome 9 at band 9p24.3->q22.1 which spans 87.657 Mbps genomic material consisting of 432 genes. The array-CGH result suggested partial trisomy 9.

#### 4. Discussion

Genomic imbalances due to chromosomal abnormalities are major cause of multiple congenital anomalies including dysmorphic features and developmental delay. The chromosomal abnormalities including balanced translocations, inversions and extra marker chromosomes passed through the parents cause unbalanced genomic changes in the fetus or children resulting in the abnormal phenotype (16).

Trisomy 9 is a fairly uncommon aneuploidy accounting for only 2.7% of all trisomy and mainly results in early miscarriages (17). Pure trisomy 9 presents a wide variety of congenital anomalies affecting most of the vital organs and limb extremities. However, the severity is highly variable from case to case (18,19). Partial trisomy 9 due to balanced translocation between chromosome 9 and other chromosomes of parents have been reported in literature (20,21). In

our case, chromosome analysis using GTG banding revealed der(9) chromosome and the karyotype was 46,XY,+der(9)t(9;14)(q22.1;q11.2)pat,-14. The array-CGH detected the accurate break point to be 9p24.3->q22.1 which could not be confirmed by conventional method. Total 432 genes are present in this breakpoint region and out of which 222 genes are found to be associated with Mendelian inheritance (22). It is evident that the der(9) chromosome came from father due to the presence of balanced translocation 46,XY,t(9;14)(q22.1;q11.2). The adjacent-2 segregation taking place during the gametogenesis in one of the parent may be the reason for the unbalanced genotype (6). Molecular cytogenetic analysis of proband using FISH revealed that the der(9) was indeed derived from the father and the child was trisomic for chromosome region 9pter->9q22.1 and monosomic for 14pter->14q11.2 region. Hence, the karyotype of proband was confirmed to be 46,XY,+der(9)t(9;14)(q22.1;q11.2)pat,-14.

In literature review we found that nine such cases with slightly similar breakpoint 9pter->9q22.2 have been reported (Table 1). However, the other partial trisomy related to region 9q12->9q32 also reported in the literature. The National organization for rare disorders (NORD) and Tracking Rare Incidence Syndromes (TRIS) project are the important database for rare diseases like trisomy 9. According to their database 150 cases of trisomy 9 has been reported so far. Of them only few



**Table 1. Correlation of clinical features and chromosome breakpoints in patients with 9p duplication**

Authors [Year] (ref.)	Region/loci duplicated	Reported clinical anomalies
<b>Our Patient</b>	9p24.3->q22.1	Macrocephaly, slight downward slanting of the eyes with epicanthic folds, hypertelorism, low set ears, large pinnae, long face, bulbous nose, thin upper lip, long philtrum, high arched palate and webbed neck, kyphoscoliosis, rocker bottom feet, short middle interphalangeal, clinodactyly of the fifth finger, pilonidal sinus, cerebral atrophy, dilated ventricles and arachnoid cyst, congenital heart disease, small size kidneys
Fryns J P <i>et al.</i> [1979] (29)	9p	Retardate psychomotor development, hypertelorism, antimagoloid slant, globular nose, protruding ears, dilated ventricles
Wilson GN <i>et al.</i> [1985] (2)	9pter->q22	Microcephaly, prominent nasal root, <b>bulbous nose, and downturned comers of the mouth</b>
Smart RD <i>et al.</i> [1988] (30)	9pter->q22.1	<b>Enlarged ventricles, facial dysmorphism</b>
Chih C P <i>et al.</i> [1999] (31)	9pter->q22	Enlarged cisternomegaly with <b>bilateral ventriculomegaly</b>
Von Kaisenberg CS <i>et al.</i> [2000] (32)	9pter->q22.2	<b>Dandy Walker malformation*</b> and cerebella vermis hypoplasia in fetus
Bouhjar IB <i>et al.</i> [2011] (27)	9p13.3->pter	<b>Typical dysmorphic features</b> but not mental retardation
Lyons JM <i>et al.</i> [2013] (33)	Partial 9p and partial monosomy Yq	<b>Neuro developmental delay, growth delay, dysmorphic features</b> , small genitalia
Kowalezyk M. <i>et al.</i> [2013] (28)	9p13.1->pter duplication with 9 p deletion	<b>Craniofacial anomalies, Dandy Walker malformation*, delayed development, mental retardation</b>
Brambila-Tapia AJ <i>et al.</i> [2014] (21)	Pure trisomy 9p13.1	<b>Psychomotor delay</b> , short stature, open anterior fontanelle, <b>dysplastic ears, facial dysmorphism</b> , Long and broad first toes, <b>CNS and skeletal alterations</b>

Bolding represents features in common with our patient. \*Partial anomalies present in our case.

**Table 2. Comparative clinical features and chromosome break points in patients with monosomy 14**

Authors [Year] (ref.)	Region/loci duplicated	Reported clinical anomalies
<b>Our Patient</b>	14pter-> 14q11.2	Macrocephaly, slight downward slanting of the eyes with epicanthic folds, hypertelorism, low set ears, large pinnae, long face, bulbous nose, thin upper lip, long philtrum, high arched palate and webbed neck, kyphoscoliosis, rocker bottom feet, short middle interphalangeal, clinodactyly of the fifth finger, pilonidal sinus, cerebral atrophy, dilated ventricles and arachnoid cyst, congenital heart disease, small size kidneys
Short E M <i>et al.</i> [1972] (25)	(14q-) deletion	<b>Delayed development</b> , Intellectual disability
Petek E <i>et al.</i> [2003] (24)	14q interstitial deletion	Small fontanelle, sloping forehead, microphthalmia, <b>malformed pinnae</b>
Prontera P <i>et al.</i> [2014] (26)	14q11.2 deletion	<b>Macrocephaly, facial dysmorphism</b> with Autism

Bolding represents features in common with our patient.

cases had longer survival more than 3-4 years (12,13). According to published literature majority of trisomy 9 cases involving breakpoint region 9pter->9q22.2 manifest clinical features such as webbed neck, rocker bottom feet, slanting eyes, growth retardation and delayed milestones (23). Similar clinical abnormalities were seen in this case, additionally classical anomalies like CNS involvement (cerebral atrophy, dilated

ventricles), and cardio vascular involvement (PDA) and renal impairment (hypoplastic kidneys) were also present. The presence of these anomalies makes the proband a classical case of partial trisomy 9 in terms of clinical diagnosis and management. Hence reporting of such cases is essential to characterize the disorder as well as to increase the awareness and knowledge in the medical community.

Moreover, partial monosomy 14pter->14q11.2 was also detected through conventional cytogenetics in the proband. Few cases of partial monosomy 14q11.2 have been reported in the literature (Table 2) and most of the anomalies overlap with trisomy 9 features (24,25). However we have not found any gain or loss in array-CGH results, showing involvement of heterochromatic region in the translocation. The reported studies shows recurrent 100 kb micro deletions in the chromosomal region 14q11.2 involving CHD1 gene are associated with autism and macrocephaly. Other study also suggested that the deletion of 114 kb in the region of 14q11.2 involving genes *SUPTT16H*, *CHD8*, *RAB2B* which are strongly associated with autism and facial dysmorphism (26). Hence cytogenetic analysis of the children with dysmorphic features is essential in view of autism spectrum disorder and its further management.

The cytogenetic screening of future pregnancies is important as there is a high risk of giving birth to chromosomally abnormal child, due to the presence of balanced translocation in the father which is likely to undergo abnormal meiotic segregation. Over the last decade recent advancement in molecular cytogenetic has proved to be an important tool for identification of complex chromosomal abnormalities including minor losses and gains with accurate breakpoint (27). The Copy number Variations (CNV's) are found to be associated with several disease conditions (28).

In conclusion, the present case of partial trisomy 9 and monosomy 14 is novel findings and showing comparatively longer survival which has not been previously reported in the literature. Further, the combination of conventional and advance molecular cytogenetic tools have proven to be essential in accurate identification of breakpoint in affected children. The present case reports will help in appropriate genetic counseling and prevention of genetic disease through prenatal diagnosis.

### Acknowledgements

The study was carried out with Institutional core grant.

### References

1. Feingold M, Atkins L. A case of trisomy 9. *J Med Genet.* 1973; 10:184-187.
2. Wilson GN, Raj A, Baker D. The phenotypic and cytogenetic spectrum of partial trisomy 9. *Am J Med Genet.* 1985; 20:277-282.
3. Yeo L, Waldron R, Lashley S, Day-Salvatore D, Vintzileos AM. Prenatal sonographic findings associated with nonmosaic trisomy 9 and literature review. *J Ultrasound Med.* 2003; 22:425-430.
4. Sepulveda W, Wimalasundera RC, Taylor MJ, Blunt S, Be C, De La Fuente S. Prenatal ultrasound findings in complete trisomy 9. *Ultrasound Obstet Gynecol.* 2003; 22:479-483.
5. Chitayat D, Hodgkinson K, Luke A, Winsor E, Rose T, Kalousek D. Prenatal diagnosis and fetopathological findings in five fetuses with trisomy 9. *Am J Med Genet.* 1995; 56:247-251.
6. McGowan-Jordan J, Simons A, Schmid M, (eds.). An international system for human cytogenomic nomenclature. Reprint of Cytogenetic and Genome Res, S Karger, Basel, New York, 2016, 149:1-2.
7. Saura R, Traore W, Taine L, Wen ZQ, Roux D, Maugey-Laulom B, Ruffie M, Vergnaud A, Horovitz J. Prenatal diagnosis of trisomy 9. Six cases and a review of the literature.
8. Zen PR, Rosa RF, Rosa RC, Graziadio C, Paskulin GA. New report of two patients with mosaic trisomy 9 presenting unusual features and longer survival. *Sao Paulo Med J.* 2011; 129:428-432.
9. Francke U, Benirschke K, Jones OW. Prenatal diagnosis of trisomy 9. *Humangenetik.* 1975; 29:243-250.
10. Schwartz S, Ashai S, Meijboom EJ, Schwartz MF, Sun CC, Cohen MM. Prenatal detection of trisomy 9 mosaicism. *Prenat Diagn.* 1989; 9:549-554.
11. Ben Slama S, Ouertani I, Dimassi K, Bacha D, Lahmar A, Mzabi S. Complete trisomy 9 with unusual phenotype association. *Tunis Med.* 2016; 94:895.
12. National organization for rare disorders (NORD). Rare Disease Database. <https://rarediseases.org/rare-diseases/chromosome-9-trisomy-9p-multiple-variants> (accessed December 5, 2018).
13. Bruns D. Presenting physical characteristics, medical conditions, and developmental status of long-term survivors with trisomy 9 mosaicism. *Am J Med Genet A.* 2011; 155:1033-1039.
14. Moorhead PS, Nowell PC, Mellman WJ, Battips DM, Hungerford DA. Chromosome preparations of leukocytes cultured from human peripheral blood. *Exp Cell Res.* 1960; 20:613-616.
15. Seabright M. A rapid banding technique for human chromosomes. *Lancet.* 1971; 2:971-972.
16. Liu HY, Huang J, Li T, Wu D, Wang HD, Wang Y, Wang T, Guo LJ, Guo QN, Huang FF, Wang RL, Wang YT. Clinical and molecular cytogenetic analyses of four patients with imbalanced translocations. *Mol Cytogenet.* 2016; 9:31.
17. Bruns DA, Campbell E. Twenty-Five additional cases of trisomy 9 mosaic: Birth information, medical conditions and developmental status. *Am J Med Genet A.* 2015; 167A:997-1007.
18. López-Félix J, Flores-Gallegos L, Garduño-Zarazúa L, Leis-Márquez T1, Juárez-García L1, Meléndez-Hernández R, Castelazo-Morales E, Mayén-Molina D. Partial trisomy 9: Prenatal diagnosis and recurrence within same family. *Clin Case Rep.* 2017; 5:986-992.
19. Leube B, Majewski F, Drechsler M, Royer-Pokora B. Unbalanced cryptic translocation der (14)t(9;14)(q34.3;q32.33) identified by subtelomeric FISH. *Clin Dysmorphol.* 2003; 12:261-265.
20. Deng L, Peng Y, Liu J, Wen J, Xia Y, Liang D, Wu L. Brief Report. Adult patient presenting an interstitial (9) (q21.32q31.1) direct duplication resulting from the malsegregation of a paternal balanced insertional translocation. *Birth Defects Res A Clin Mol Teratol.* 2014; 100:294-299.
21. Brambila-Tapia AJ, Neira VA, Vásquez-Velásquez AI, Jimenez-Arredondo RE, Chávez-González EL, Picos-Cárdenas VJ, Fletes-Rayas AL, Figuera LE. Pure 9p trisomy derived from a terminal balanced unreciprocal

- translocation. *Genet Couns.* 2014; 25:289-297.
22. Hamosh A, Scott AF, Amberger J, Valle D, McKusick VA. Online Mendelian Inheritance in Man (OMIM). *Hum Mutat.* 2000; 15:57-61.
  23. Smith DW. Recognizable patterns of human malformation. *Major Probl Clin Pediatr.* 1976; 7:1-497.
  24. Petek E, Plecko-Startinig B, Windpassinger C, Egger H, Wagner K, Kroisel PM. Molecular characterization of a 3.5 Mb interstitial 14q deletion in a child with several phenotypic anomalies. *J Med Genet.* 2003; 40:e47.
  25. Short EM, Solitare GB, Breg WR. A case of partial 14 trisomy 47,XY,(14q-) and translocation t(9p+;14q-) in mother and brother. *J Med Genet.* 1972; 9:367-373.
  26. Prontera P, Ottaviani V, Toccaceli D, Rogaiia D, Ardisia C, Romani R, Stangoni G, Pierini A, Donti E. Recurrent~100 Kb microdeletion in the chromosomal region 14q11.2, involving *CHD8* gene, is associated with autism and macrocephaly. *Am J Med Genet A.* 2014; 164A:3137-3141.
  27. Bouhjar IB, Hannachi H, Zerelli SM, Labalme A, Gmidène A, Soyah N, Missaoui S, Sanlaville D, Elghezal H, Saad A. Array-CGH study of partial trisomy 9p without mental retardation. *Am J Med Genet A.* 2011; 155A :1735-1739.
  28. Kowalczyk M, Tomaszewska A, Podbiół-Palenta A, Constantinou M, Wawrzkiwicz-Witkowska A, Kowalski J, Kałużewski B, Zajaczek S, Srebniak MI. Another rare case of a child with de novo terminal 9p deletion and co-existing interstitial 9p duplication: Clinical findings and molecular cytogenetic study by array-CGH. *Cytogenet Genome Res.* 2013; 139:9-16.
  29. Fryns JP, Casaer P, Van den Berghe H. Partial duplication of the short arm of chromosome 9 (p13 leads to p22) in a child with typical 9p trisomy phenotype. *Hum Genet.* 1979; 46:231-235.
  30. Smart RD, Viljoen DL, Fraser B. Partial trisomy 9 – further delineation of the phenotype. *Am J Med Genet.* 1988; 31:947-951.
  31. Chen CP, Shih JC. Prenatal diagnosis of bilateral ventriculomegaly and an enlarged cisterna magna in a fetus with partial trisomy 9 and partial trisomy 21. *Prenat Diagn.* 1999; 19:1175-1176.
  32. von Kaisenberg CS, Caliebe A, Krams M, Hackelöer BJ, Jonat W. Absence of 9q22-9qter in trisomy 9 does not prevent a Dandy-Walker phenotype. *Am J Med Genet.* 2000; 95:425-428.
  33. Lyons MJ, Fuller JD, Montoya Mdel C, DuPont BR, Holden KR. Unbalanced translocation involving partial trisomy 9p and partial monosomy yq with neurodevelopmental delays. *J Child Neurol.* 2013; 28:524-526.

(Received January 3, 2019; Revised February 13, 2019; Accepted February 18, 2019)

## Network established to collaborate on diagnosis and treatment of rare diseases in China: A strategic alliance backed by tiered healthcare is the key to the future

Qianli Ren<sup>1</sup>, Jianbin Wang<sup>2,\*</sup>

<sup>1</sup> Department of Medical Imaging, The People's Hospital of Huaibei, Huaibei, Anhui, China;

<sup>2</sup> Intensive Care Unit, The People's Hospital of Huaibei, Huaibei, Anhui, China.

### Summary

Rare diseases are an important public health issue and a challenge to healthcare. Over the past few years, China has actively worked to improve rare disease care and orphan drugs for rare diseases, but many challenges still remain. In order to further promote measures to combat rare diseases, the "National Network to Collaborate on Diagnosis and Treatment of Rare Diseases" was established by the National Health Commission of the People's Republic of China on February 12, 2019. This network for collaboration consists of 324 hospitals nationwide, and its aim is to set up a practical mechanism for an effective alliance by different tiers of the healthcare system. The strategy for collaboration includes six programs: *i*) to establish a mechanism for collaboration, *ii*) to implement standards of care, *iii*) to enhance quality control, *iv*) to ensure the supply of drugs, *v*) to set up a registry, and *vi*) to enhance clinical research. These programs will play a pivotal role in combating rare diseases in the future and eventually achieving the goal of creating a proper and consistent mechanism to treat and manage rare diseases.

**Keywords:** Rare diseases, network for collaboration, tiered healthcare

On February 12, 2019, establishment of the "National Network to Collaborate on Diagnosis and Treatment of Rare Diseases" was announced by the National Health Commission of the People's Republic of China to further combat rare diseases (1). The network consists of 324 hospitals nationwide, including 1 leading national institution, 32 leading provincial institutions, and 291 member institutions in accordance with recommendations from provincial health authorities and a panel of experts.

Worldwide, there are between 6,000 and 8,000 rare diseases. Eighty percent of rare diseases have identified genetic origins, 75% of rare diseases affect children, and 30% of patients with rare diseases die before the age of 5 (2,3). Rare diseases are serious chronic diseases and may be life-threatening. The features of rare diseases and the increasing number of identified

rare diseases make these diseases a priority for policymakers, researchers, legislators, and healthcare professionals (4,5).

Over the past few years, China has actively worked to improve rare disease care and orphan drugs for rare diseases, but it still lags far behind the US, EU, Japan, and other countries and regions in scientific research, diagnosis and treatment, protection of patient rights, public awareness, and other areas. The good news is that some provinces and cities in China have taken a step forward in policy-making and alliance building. Supporting measures have mainly been implemented by professional groups, such as the Specialty Committee of Rare Diseases of the Shanghai Medical Association since 2011 (6), the Shanghai Center for Diagnosis and Treatment of Rare Diseases, the Shanghai Children's Center for Diagnosis and Treatment of Rare Diseases, and the Shanghai Clinic Specializing in Rare Diseases established in 2018 (7), and the China Rare Disease Alliance consisting of more than 50 entities ranging from medical facilities, universities, academic institutions, and companies since 2018 (8). These measures are intended to promote research and

\*Address correspondence to:

Dr. Jianbin Wang, Intensive Care Unit, The People's Hospital of Huaibei, No.66, Huaihai-Xi-Lu, Huaibei 235000, Anhui, China.

E-mail: wangjbin@126.com

development on rare diseases and orphan drugs.

On May 22, 2018, China's First National List of Rare Diseases, which includes 121 rare diseases, was jointly issued by five national bodies, including the National Health Commission, the Ministry of Science and Technology, the Ministry of Industry and Information Technology, the State Drug Administration, and the State Administration of Traditional Chinese Medicine (9,10). This is a historical breakthrough indicating that rare diseases are garnering more attention and that those diseases are being considered as part of national health strategy and planning. Given this situation, the "National Network to Collaborate on Diagnosis and Treatment of Rare Diseases" was approved as an important platform in February 2019. The goal of the Network is to further flesh out practical mechanisms and infrastructure to combat rare diseases in light of changing social and financial resources.

In order to facilitate coordination among the different tiers of the healthcare system, the "National Network to Collaborate on Diagnosis and Treatment of Rare Diseases" has clearly described workflow management and identified future strategies to deal with the challenge of rare diseases from various perspectives. Priorities are to establish a network for diagnosis and treatment of rare diseases, to create a comprehensive mechanism for coordination and designation of certain hospitals as bases for treatment through referrals in the tiered healthcare system, to eventually achieve the goal of early detection and diagnosis, and to create fair and consistent mechanisms to treat and manage rare diseases. The strategy for collaboration includes six programs. One is *i*) to establish a mechanism for collaboration. Leading hospitals and member hospitals will form a network to cover the screening, diagnosis, treatment, rehabilitation, and long-term management. The second program is *ii*) to implement standards of care. Clinicians will be trained to follow technical guidelines and a referral system will be developed to improve the rate of early diagnosis and treatment. The third program is *iii*) to enhance quality control. Provincial healthcare authorities will enhance management, guidance, and evaluation. Member hospitals will improve their diagnosis and treatment capabilities with an emphasis on safety and multi-disciplinary treatment (MDT). The fourth program is *iv*) to ensure the supply of drugs. Member hospitals will properly manage orphan drugs and fulfill clinical demand. The supply chain will make picking up drugs more convenient for patients with rare diseases. The fifth program is *v*) to set up a registry. The National Health Commission has set up a registry for rare diseases. Member hospitals will collect data and statistics. The sixth program is *vi*) to enhance clinical research. Basic,

clinical, and translational research will be encouraged, and international exchanges and cooperation will be enhanced.

Rare diseases are a pressing public health issue and challenge to healthcare worldwide. The kickoff of the "National Network to Collaborate on Diagnosis and Treatment of Rare Diseases" represents a positive step by the government to formulate measures to combat rare diseases in China, and this effort portends a number of efforts in the future. Substantial efforts are urgently needed, and society is still calling for the enactment of legislation and accompanying regulations on rare diseases and orphan drugs.

## References

1. Xinhua News Agency. 324 hospitals create a network for diagnosis and treatment of rare disease. [http://www.xinhuanet.com/health/2019-02/18/c\\_1124127837.htm](http://www.xinhuanet.com/health/2019-02/18/c_1124127837.htm) (accessed on February 15, 2019) (in Chinese)
2. EURORDIS. What is a rare disease? <https://www.eurordis.org/content/what-rare-disease> (accessed February 16, 2019).
3. Song PP, Gao JJ, Inagaki Y, Kokudo N, Tang W. Rare diseases, orphan drugs, and their regulation in Asia: Current status and future perspectives. *Intractable Rare Dis Res.* 2012; 1:3-9.
4. EURORDIS. Rare diseases: Understanding this public health priority. <http://www.eurordis.org/publication/rare-diseases-understanding-public-health-priority> (accessed February 16, 2019).
5. Tang Q, Song PP, Xu LZ. The Government's role in regulating, coordinating, and standardizing the response to Alzheimer's disease: Anticipated international cooperation in the area of intractable and rare diseases. *Intractable Rare Dis Res.* 2016; 5:238-243.
6. Ma D, Zhou WH, Huang GY. The rare diseases are not rare. *Chinese Journal of Evidence-based Pediatrics.* 2011; 6: 83-85. (in Chinese)
7. Kang Q, Hu JH, Song PP, He JJ. System building and improvement for the diagnosis and treatment of rare diseases in Shanghai, China. *Intractable & Rare Diseases Research.* 2018; 7:291-294.
8. China Daily. China sets up alliance for rare diseases. <http://www.chinadaily.com.cn/a/201810/28/WS5bd56137a310eff303284ff8.html> (accessed February 16, 2019).
9. China Central Television Website. Five ministries jointly issue a national rare diseases list that includes 121 diseases. <http://news.cctv.com/2018/05/23/ARTIsgTVRkhQoWEGyVRhmc2s180523.shtml> (accessed February 18, 2019). (in Chinese)
10. He JJ, Kang Q, Hu JH, Song PP, Jin CL. China has officially released its first national list of rare diseases. *Intractable Rare Dis Res.* 2018; 7:145-147.

(Received February 19, 2019; Revised February 26, 2019; Accepted February 27, 2019)

## Guide for Authors

### 1. Scope of Articles

Intractable & Rare Diseases Research is an international peer-reviewed journal. Intractable & Rare Diseases Research devotes to publishing the latest and most significant research in intractable and rare diseases. Articles cover all aspects of intractable and rare diseases research such as molecular biology, genetics, clinical diagnosis, prevention and treatment, epidemiology, health economics, health management, medical care system, and social science in order to encourage cooperation and exchange among scientists and clinical researchers.

### 2. Submission Types

**Original Articles** should be well-documented, novel, and significant to the field as a whole. An Original Article should be arranged into the following sections: Title page, Abstract, Introduction, Materials and Methods, Results, Discussion, Acknowledgments, and References. Original articles should not exceed 5,000 words in length (excluding references) and should be limited to a maximum of 50 references. Articles may contain a maximum of 10 figures and/or tables.

**Brief Reports** definitively documenting either experimental results or informative clinical observations will be considered for publication in this category. Brief Reports are not intended for publication of incomplete or preliminary findings. Brief Reports should not exceed 3,000 words in length (excluding references) and should be limited to a maximum of 4 figures and/or tables and 30 references. A Brief Report contains the same sections as an Original Article, but the Results and Discussion sections should be combined.

**Reviews** should present a full and up-to-date account of recent developments within an area of research. Normally, reviews should not exceed 8,000 words in length (excluding references) and should be limited to a maximum of 100 references. Mini reviews are also accepted.

**Policy Forum** articles discuss research and policy issues in areas related to life science such as public health, the medical care system, and social science and may address governmental issues at district, national, and international levels of discourse. Policy Forum articles should not exceed 2,000 words in length (excluding references).

**Case Reports** should be detailed reports of the symptoms, signs, diagnosis, treatment, and follow-up of an individual patient. Case reports may contain a demographic profile of the patient but usually describe an unusual

or novel occurrence. Unreported or unusual side effects or adverse interactions involving medications will also be considered. Case Reports should not exceed 3,000 words in length (excluding references).

**News** articles should report the latest events in health sciences and medical research from around the world. News should not exceed 500 words in length.

**Letters** should present considered opinions in response to articles published in Intractable & Rare Diseases Research in the last 6 months or issues of general interest. Letters should not exceed 800 words in length and may contain a maximum of 10 references.

### 3. Editorial Policies

**Ethics:** Intractable & Rare Diseases Research requires that authors of reports of investigations in humans or animals indicate that those studies were formally approved by a relevant ethics committee or review board.

**Conflict of Interest:** All authors are required to disclose any actual or potential conflict of interest including financial interests or relationships with other people or organizations that might raise questions of bias in the work reported. If no conflict of interest exists for each author, please state "There is no conflict of interest to disclose".

**Submission Declaration:** When a manuscript is considered for submission to Intractable & Rare Diseases Research, the authors should confirm that 1) no part of this manuscript is currently under consideration for publication elsewhere; 2) this manuscript does not contain the same information in whole or in part as manuscripts that have been published, accepted, or are under review elsewhere, except in the form of an abstract, a letter to the editor, or part of a published lecture or academic thesis; 3) authorization for publication has been obtained from the authors' employer or institution; and 4) all contributing authors have agreed to submit this manuscript.

**Cover Letter:** The manuscript must be accompanied by a cover letter signed by the corresponding author on behalf of all authors. The letter should indicate the basic findings of the work and their significance. The letter should also include a statement affirming that all authors concur with the submission and that the material submitted for publication has not been published previously or is not under consideration for publication elsewhere. The cover letter should be submitted in PDF format. For example of Cover Letter, please visit <http://www.irdrjournal.com/downcentre.php> (Download Centre).

**Copyright:** A signed JOURNAL PUBLISHING AGREEMENT (JPA) form must be provided by post, fax, or as a scanned file before acceptance of the article. Only forms with a hand-written signature are accepted. This copyright will ensure the widest possible dissemination of information.

A form facilitating transfer of copyright can be downloaded by clicking the appropriate link and can be returned to the e-mail address or fax number noted on the form (Please visit [Download Centre](#)). Please note that your manuscript will not proceed to the next step in publication until the JPA Form is received. In addition, if excerpts from other copyrighted works are included, the author(s) must obtain written permission from the copyright owners and credit the source(s) in the article.

**Suggested Reviewers:** A list of up to 3 reviewers who are qualified to assess the scientific merit of the study is welcomed. Reviewer information including names, affiliations, addresses, and e-mail should be provided at the same time the manuscript is submitted online. Please do not suggest reviewers with known conflicts of interest, including participants or anyone with a stake in the proposed research; anyone from the same institution; former students, advisors, or research collaborators (within the last three years); or close personal contacts. Please note that the Editor-in-Chief may accept one or more of the proposed reviewers or may request a review by other qualified persons.

**Language Editing:** Manuscripts prepared by authors whose native language is not English should have their work proofread by a native English speaker before submission. If not, this might delay the publication of your manuscript in Intractable & Rare Diseases Research.

The Editing Support Organization can provide English proofreading, Japanese-English translation, and Chinese-English translation services to authors who want to publish in Intractable & Rare Diseases Research and need assistance before submitting a manuscript. Authors can visit this organization directly at <http://www.iacmhr.com/iac-eso/support.php?lang=en>. IAC-ESO was established to facilitate manuscript preparation by researchers whose native language is not English and to help edit works intended for international academic journals.

### 4. Manuscript Preparation

Manuscripts should be written in clear, grammatically correct English and submitted as a Microsoft Word file in a single-column format. Manuscripts must be paginated and typed in 12-point Times New Roman font with 24-point line spacing. Please do not embed figures in the text. Abbreviations should be used as little as possible and should be explained at first mention unless the term is a well-known abbreviation (e.g. DNA). Single words should not be abbreviated.

**Title page:** The title page must include 1) the title of the paper (Please note the title should be short, informative, and contain the major key words); 2) full name(s) and affiliation(s) of the author(s), 3) abbreviated names of the author(s), 4) full name, mailing address, telephone/fax numbers, and e-mail address of the corresponding author; and 5) conflicts of interest (if you have an actual or potential conflict of interest to disclose, it must be included as a footnote on the title page of the

manuscript; if no conflict of interest exists for each author, please state "There is no conflict of interest to disclose"). Please visit [Download Centre](#) and refer to the title page of the manuscript sample.

**Abstract:** The abstract should briefly state the purpose of the study, methods, main findings, and conclusions. For article types including Original Article, Brief Report, Review, Policy Forum, and Case Report, a one-paragraph abstract consisting of no more than 250 words must be included in the manuscript. For News and Letters, a brief summary of main content in 150 words or fewer should be included in the manuscript. Abbreviations must be kept to a minimum and non-standard abbreviations explained in brackets at first mention. References should be avoided in the abstract. Key words or phrases that do not occur in the title should be included in the Abstract page.

**Introduction:** The introduction should be a concise statement of the basis for the study and its scientific context.

**Materials and Methods:** The description should be brief but with sufficient detail to enable others to reproduce the experiments. Procedures that have been published previously should not be described in detail but appropriate references should simply be cited. Only new and significant modifications of previously published procedures require complete description. Names of products and manufacturers with their locations (city and state/country) should be given and sources of animals and cell lines should always be indicated. All clinical investigations must have been conducted in accordance with Declaration of Helsinki principles. All human and animal studies must have been approved by the appropriate institutional review board(s) and a specific declaration of approval must be made within this section.

**Results:** The description of the experimental results should be succinct but in sufficient detail to allow the experiments to be analyzed and interpreted by an independent reader. If necessary, subheadings may be used for an orderly presentation. All figures and tables must be referred to in the text.

**Discussion:** The data should be interpreted concisely without repeating material already presented in the Results section. Speculation is permissible, but it must be well-founded, and discussion of the wider implications of the findings is encouraged. Conclusions derived from the study should be included in this section.

**Acknowledgments:** All funding sources should be credited in the Acknowledgments section. In addition, people who contributed to the work but who do not meet the criteria for authors should be listed along with their contributions.

**References:** References should be numbered in the order in which they appear in the text. Citing of unpublished results, personal

communications, conference abstracts, and theses in the reference list is not recommended but these sources may be mentioned in the text. In the reference list, cite the names of all authors when there are fifteen or fewer authors; if there are sixteen or more authors, list the first three followed by *et al.* Names of journals should be abbreviated in the style used in PubMed. Authors are responsible for the accuracy of the references. Examples are given below:

*Example 1 (Sample journal reference):*  
Inagaki Y, Tang W, Zhang L, Du GH, Xu WF, Kokudo N. Novel aminopeptidase N (APN/CD13) inhibitor 24F can suppress invasion of hepatocellular carcinoma cells as well as angiogenesis. *Biosci Trends*. 2010; 4:56-60.

*Example 2 (Sample journal reference with more than 15 authors):*  
Darby S, Hill D, Auvinen A, *et al.* Radon in homes and risk of lung cancer: Collaborative analysis of individual data from 13 European case-control studies. *BMJ*. 2005; 330:223.

*Example 3 (Sample book reference):*  
Shalev AY. Post-traumatic stress disorder: Diagnosis, history and life course. In: *Post-traumatic Stress Disorder, Diagnosis, Management and Treatment* (Nutt DJ, Davidson JR, Zohar J, eds.). Martin Dunitz, London, UK, 2000; pp. 1-15.

*Example 4 (Sample web page reference):*  
World Health Organization. The World Health Report 2008 – primary health care: Now more than ever. [http://www.who.int/whr/2008/whr08\\_en.pdf](http://www.who.int/whr/2008/whr08_en.pdf) (accessed September 23, 2010).

**Tables:** All tables should be prepared in Microsoft Word or Excel and should be arranged at the end of the manuscript after the References section. Please note that tables should not in image format. All tables should have a concise title and should be numbered consecutively with Arabic numerals. If necessary, additional information should be given below the table.

**Figure Legend:** The figure legend should be typed on a separate page of the main manuscript and should include a short title and explanation. The legend should be concise but comprehensive and should be understood without referring to the text. Symbols used in figures must be explained.

**Figure Preparation:** All figures should be clear and cited in numerical order in the text. Figures must fit a one- or two-column format on the journal page: 8.3 cm (3.3 in.) wide for a single column, 17.3 cm (6.8 in.) wide for a double column; maximum height: 24.0 cm (9.5 in.). Please make sure that artwork files are in an acceptable format (TIFF or JPEG) at minimum resolution (600 dpi for illustrations, graphs, and annotated artwork, and 300 dpi for micrographs and photographs). Please provide all figures as separate files. Please note that low-resolution images are one of the leading causes of article resubmission and schedule delays. All color figures will be reproduced in full color in the online edition of the journal at no cost to authors.

**Units and Symbols:** Units and symbols conforming to the International System of Units (SI) should be used for physicochemical quantities. Solidus notation (*e.g.* mg/kg, mg/mL, mol/mm<sup>2</sup>/min) should be used. Please refer to the SI Guide [www.bipm.org/en/si/](http://www.bipm.org/en/si/) for standard units.

**Supplemental data:** Supplemental data might be useful for supporting and enhancing your scientific research and Intractable & Rare Diseases Research accepts the submission of these materials which will be only published online alongside the electronic version of your article. Supplemental files (figures, tables, and other text materials) should be prepared according to the above guidelines, numbered in Arabic numerals (*e.g.*, Figure S1, Figure S2, and Table S1, Table S2) and referred to in the text. All figures and tables should have titles and legends. All figure legends, tables and supplemental text materials should be placed at the end of the paper. Please note all of these supplemental data should be provided at the time of initial submission and note that the editors reserve the right to limit the size and length of Supplemental Data.

## 5. Submission Checklist

The Submission Checklist will be useful during the final checking of a manuscript prior to sending it to Intractable & Rare Diseases Research for review. Please visit [Download Centre](#) and download the Submission Checklist file.

## 6. Online submission

Manuscripts should be submitted to Intractable & Rare Diseases Research online at <http://www.irdjournal.com>. The manuscript file should be smaller than 5 MB in size. If for any reason you are unable to submit a file online, please contact the Editorial Office by e-mail at [office@irdjournal.com](mailto:office@irdjournal.com)

## 7. Accepted manuscripts

**Proofs:** Galley proofs in PDF format will be sent to the corresponding author *via* e-mail. Corrections must be returned to the editor ([office@irdjournal.com](mailto:office@irdjournal.com)) within 3 working days.

**Offprints:** Authors will be provided with electronic offprints of their article. Paper offprints can be ordered at prices quoted on the order form that accompanies the proofs.

**Page Charge:** No page charges will be levied to author for the publication of their article except for reprints.

(As of February 2013)

## Editorial and Head Office:

Pearl City Koishikawa 603  
2-4-5 Kasuga, Bunkyo-ku  
Tokyo 112-0003, Japan  
Tel: +81-3-5840-9968  
Fax: +81-3-5840-9969  
E-mail: [office@irdjournal.com](mailto:office@irdjournal.com)

### JOURNAL PUBLISHING AGREEMENT (JPA)

-----  
**Manuscript No.:**

**Title:**

**Corresponding Author:**  
-----

The International Advancement Center for Medicine & Health Research Co., Ltd. (IACMHR Co., Ltd.) is pleased to accept the above article for publication in Intractable & Rare Diseases Research. The International Research and Cooperation Association for Bio & Socio-Sciences Advancement (IRCA-BSSA) reserves all rights to the published article. Your written acceptance of this JOURNAL PUBLISHING AGREEMENT is required before the article can be published. Please read this form carefully and sign it if you agree to its terms. The signed JOURNAL PUBLISHING AGREEMENT should be sent to the Intractable & Rare Diseases Research office (Pearl City Koishikawa 603, 2-4-5 Kasuga, Bunkyo-ku, Tokyo 112-0003, Japan; E-mail: office@irdrjournal.com; Tel: +81-3-5840-9968; Fax: +81-3-5840-9969).

#### 1. Authorship Criteria

As the corresponding author, I certify on behalf of all of the authors that:

- 1) The article is an original work and does not involve fraud, fabrication, or plagiarism.
- 2) The article has not been published previously and is not currently under consideration for publication elsewhere. If accepted by Intractable & Rare Diseases Research, the article will not be submitted for publication to any other journal.
- 3) The article contains no libelous or other unlawful statements and does not contain any materials that infringes upon individual privacy or proprietary rights or any statutory copyright.
- 4) I have obtained written permission from copyright owners for any excerpts from copyrighted works that are included and have credited the sources in my article.
- 5) All authors have made significant contributions to the study including the conception and design of this work, the analysis of the data, and the writing of the manuscript.
- 6) All authors have reviewed this manuscript and take responsibility for its content and approve its publication.
- 7) I have informed all of the authors of the terms of this publishing agreement and I am signing on their behalf as their agent.

#### 2. Copyright Transfer Agreement

I hereby assign and transfer to IACMHR Co., Ltd. all exclusive rights of copyright ownership to the above work in the journal Intractable & Rare Diseases Research, including but not limited to the right 1) to publish, republish, derivate, distribute, transmit, sell, and otherwise use the work and other related material worldwide, in whole or in part, in all languages, in electronic, printed, or any other forms of media now known or hereafter developed and the right 2) to authorize or license third parties to do any of the above.

I understand that these exclusive rights will become the property of IACMHR Co., Ltd., from the date the article is accepted for publication in the journal Intractable & Rare Diseases Research. I also understand that IACMHR Co., Ltd. as a copyright owner has sole authority to license and permit reproductions of the article.

I understand that except for copyright, other proprietary rights related to the Work (e.g. patent or other rights to any process or procedure) shall be retained by the authors. To reproduce any text, figures, tables, or illustrations from this Work in future works of their own, the authors must obtain written permission from IACMHR Co., Ltd.; such permission cannot be unreasonably withheld by IACMHR Co., Ltd.

#### 3. Conflict of Interest Disclosure

I confirm that all funding sources supporting the work and all institutions or people who contributed to the work but who do not meet the criteria for authors are acknowledged. I also confirm that all commercial affiliations, stock ownership, equity interests, or patent-licensing arrangements that could be considered to pose a financial conflict of interest in connection with the article have been disclosed.

-----  
**Corresponding Author's Name (Signature):**

**Date:**





